

We are IntechOpen, the world's leading publisher of Open Access books Built by scientists, for scientists

4,400

Open access books available

117,000

International authors and editors

130M

Downloads

Our authors are among the

154

Countries delivered to

TOP 1%

most cited scientists

12.2%

Contributors from top 500 universities



WEB OF SCIENCE™

Selection of our books indexed in the Book Citation Index
in Web of Science™ Core Collection (BKCI)

Interested in publishing with us?
Contact book.department@intechopen.com

Numbers displayed above are based on latest data collected.
For more information visit www.intechopen.com



Airway Management in ICU Settings

Nabil Abdelhamid Shallik, Mamdouh Almustafa,
Ahmed Zaghw and Abbas Moustafa

Additional information is available at the end of the chapter

<http://dx.doi.org/10.5772/intechopen.69166>

Abstract

Maintenance of patent airway, adequate ventilation, and pulmonary gas exchange is very important in critically ill patients. Airway management in intensive care patients differs significantly from routine surgical procedures in the operating room. The airway competence in intensive care unit (ICU) should be coping with the rapidly evolving advances in airway management. Therefore, efforts should be focused on the three pillars of airway master: airway providers as intensivists or critical care physicians, equipment, and operational plans. Not all institutions can afford all airway equipment in the market; however, they should make sure that critical care providers have a full access to the available tools and they are comfortable using it. Educational sessions and refresher courses should be tailored to meet the competence level of the ICU providers and equipment availability. Operational plan includes developing institutional airway protocols and implementing difficult airway guidelines. The protocols should consider different staffing models of ICU and make sure all the time at least one member of the team with the highest experience in airway should be always available. The aim of writing this chapter is to enable the intensivist to optimize their use of airway equipment and managing high-risk patients in ICU.

Keywords: tracheal intubation, videolaryngoscopy (VL), flexible fiberoptic intubation, bronchoscopy, percutaneous tracheostomy, extubation in ICU, high-flow nasal cannula (HFNC), virtual endoscopy (VE), airway ultrasound, supra-glottic airway devices, tube exchange

1. Tracheal intubation in ICU

1.1. Introduction

Tracheal intubation (TI) is one of daily practiced procedures in the intensive care unit (ICU), especially when the patient has respiratory failure or cardiovascular collapse. It involves highly skilled techniques that require much of training, practice, and expertise. The excellence in airway management in ICU is necessary for intensivist's every day practice, which when it is lacking does not only compromise the quality of care but also has a potential impact on patient safety.

The optimal intubation condition prevailing in surgical theaters differs a lot in nature than harsh and chaotic scenarios in ICU. The nature of those situations has three factors: the highly skilled anesthesiologists versus the intensivists; the compensated, well-controlled surgical patient versus the decompensated sick ICU patients; and equipment availability. That is why in ICU settings, the airway instrumentation-related complications have higher incidence than anesthesia settings. Among the contributory factors for high failure rates are the highly stressful environment, limited expertise level of the providers with different techniques of airway management, the physiological baseline for the patients, inadequate pre-oxygenation, unfamiliarity with new airway equipment, and the critical time factor in distressed situations in addition to the negative hemodynamic effects for the intubation medications.

2. Challenges in airway management in the critically ill patients

2.1. Response to pre-oxygenation

Effective pre-oxygenation is the first step for airway management. If it is done optimally by reaching PEO_2 of $>90\%$, it extends the apnea safety time margin for critical ICU patients with already limited oxygen transport and when the intubation for airway control would be time consuming. The apnea time for oxy-hemoglobin to desaturate below 85% in postoperative period is 23 s in critically ill patients compared to 502 s in healthy adults [1].

The standard pre-oxygenation used in optimized surgical patients would fail to sustain adequate PaO_2 in critically ill patients with hyper-metabolic profile during apneic period for intubation.

The airway management encountered in a rapidly deteriorating patient with hypoxia from a life-threatening cardiopulmonary failure is not an uncommon daily ICU scenario. Lack of airway expertise is a high risk for multiple intubation attempts, airway trauma, esophageal intubation, and intubation failure, and consequences were adverse with high percentage of cardiac arrest or brain damage. Moreover, multiple traumatic trials by inexperienced provider could easily convert a simple airway to a difficult one due to airway edema.

2.2. Assessment and evaluation of the airway

Airway evaluation prior to tracheal intubation (TI) is the standard of care in anesthesia settings and should be routinely practiced in ICU before any TI. Many studies about airway

evaluation in controlled anesthesia settings showed that combined airway tests are better than each test alone in terms of sensitivity and reliability.

Airway tests include Mallampati classification, thyromental distance, neck mobility, inter-incisor distance, and body mass index (BMI), which are all reliable predictors for difficult airway. Other scores include El Ganzouri test and LEMON test. El Ganzouri test is a numerical score, involves all the abovementioned tests: Mallampati classification, thyromental distance, neck mobility, inter-incisor distance, and BMI plus under-bite and previous difficult intubation history. LEMON test involves Look Externally, Mallampati class, Obstruction, and Neck mobility.

2.3. Drugs used for tracheal intubation, rapid sequence intubation

Hemodynamic changes during TI are predictable physiological consequences after airway management, which are attributed to three main factors: sympathetic system, cardiac contractility, and mechanical ventilation. Vaso-dilatory and cardio-depressive effects of medications, pre-existing hypovolemia, and positive-pressure ventilation are major contributors to any predictable hemodynamic changes. Ketamine and Etomidate are anesthetic agents with a fast onset, short half-life, and tolerable hemodynamic changes. They are widely used in emergency settings to improve intubation conditions. Etomidate is an anesthetic agent with adrenal inhibition effect. A cardio-stable agent as Ketamine is preferable in ICU. The critical illness of ICU patients compromises the gastric emptying, making a rapid sequence intubation (RSI) a wise decision. Succinylcholine is a fast acting muscle relaxant with ultra short duration that is commonly used in emergency setting when there are no contraindications to its use. Muscle relaxants have its role in facilitating intubation; however, encountering cannot-ventilate-cannot-intubate (CVCI) scenario after giving muscle relaxants could lead to a fatal airway emergency. Studies found that physicians other than anesthesiologists are reluctant to use muscle relaxants before intubation in the ICU. A large data set found fewer complications, including in patients with difficult airways when muscle relaxants were used. In a prospective multicenter study, Jaber showed that tracheal intubation by muscle relaxants has less complications by 22 versus 37% when muscle relaxants were not used [2]. In another study in emergency department, Li et al. found a significant decrease in esophageal intubation with the use of muscle relaxants (3 vs. 18%) [3]. Succinylcholine should not be used in patients with hyperkalemia, congenital muscle disorders, and burn patients with difficult airway as it could lead to hyperkalemic cardiac arrest. As alternative to Succinylcholine, Rocuronium Bromide (1 mg/kg) can be used for rapid sequence intubation in critical care patients and can be reversed by Sugammadex Sodium.

2.4. Pre-oxygenation and tracheal tube confirmation

Pre-oxygenation before intubation is the standard of care. The standard pre-oxygenation used in optimized surgical patients could fail to sustain adequate PaO₂ in patients with respiratory failure. Randomized control trial (RCT) by Baillard et al. confirmed that pre-oxygenation done by noninvasive positive-pressure ventilation (NIPPV) prior to TI is superior to that done classically by a bag-valve mask device for a 3-min duration [2]. The patients who have been pre-oxygenated by NIPPV have higher pulse oximetric saturation (98 ± 2 vs. 93 ± 6%) and higher PaO₂ values during TI (203 vs. 97 mmHg) and up to 5 min into the post-intubation period compared with the bag-valve mask method. In acute respiratory failure,

NIPPV improves oxygenation by delivering high oxygen concentration, by unloading respiratory muscle, recruiting alveoli, and thereby increasing the functional residual capacity in such hypoxemic patients. To confirm the endotracheal tube placement after TI, classically chest inspection for bilateral equal expansion and chest auscultation for equal air entry on both sides have been routinely used. Recently, the American Society for Anesthesiology (ASA) has adopted end tidal CO₂ monitor as the standard of care inside the operating room. Confirmation of endotracheal intubation by capnography has 100% sensitivity and specificity. Continuous capnography waveform is recommended as well during chest compression for cardiac arrest victims [4]. Esophageal detector device is an alternative carbon dioxide-monitoring device. The endobronchial intubation must be ruled out by chest radiograph, as a part of post-intubation care.

2.5. Intubation “care bundle” management

Care bundles are the best evidence-based therapies that could guarantee the best outcomes when applied together than each therapy alone in the bundle. Intubation bundle has been developed to enhance the quality of intubation procedure by setting a package tool to be followed by any provider in any intubation scenario with every patient. This bundle focuses on standardization of the stepwise process and eliminating the individual preferences and technical variability. The bundle involves maintaining cardiovascular stability, gas exchange, and the neurological status while securing the airway. The proposed ICU intubation management protocol includes 10 elements bundle [2].

2.5.1. Pre-intubation

1. Presence of two persons.
2. (Normal saline 500 ml or colloid 250 ml) as fluid loading in the absence of cardiogenic causes of pulmonary edema.
3. Long-term sedation ready to start.
4. Pre-oxygenation for 3 min by NIPPV with the following parameters:
(FiO₂ 100%, pressure support ventilation level of 5–15 cm H₂O, tidal volume of 6–8 ml/kg, and PEEP of 5 cm H₂O).

2.5.2. During intubation

5. Rapid sequence induction: Anesthetic medications include Etomidate 0.2–0.3 mg/kg or ketamine 1.5–3 mg/kg or Propofol-Ketamine mixture. Muscle relaxants include Succinylcholine 1–1.5 mg/kg or Rocuronium Bromide 1 mg/kg. Succinylcholine is contraindicated in the following condition, hyperkalemia, severe acidosis, acute or chronic neuromuscular disease, burn patient for more than 48 h and spinal cord trauma, otherwise Rocuronium Bromide is preferred.
6. Cricoid pressure or Sellick maneuver should be applied.

2.5.3. Post-intubation

7. Immediate confirmation of tube placement by capnography.
8. Nor-adrenaline infusion if diastolic blood pressure still low.
9. Start long-term sedation.
10. Initial “protective ventilation”: Tidal volume 6–8 ml/kg of ideal body weight, PEEP 5 cm H₂O and respiratory rate between 10 and 20 cycles/min, FiO₂ 100%, plateau pressure <30 cm H₂O.

Studies showed that the bundle lowered the life-threatening complications as severe desaturation, hypotension, or cardiac arrest by 21 versus 34%. Other moderate complications have lowered as well (9 vs. 21%) compared with the non-bundle group [2].

TI in emergency settings in unstable patients could lead to an acute airway emergency. The airway morbidity and mortality increase with unstable hemodynamics and failing oxygenation during emergency intubations. That is why tracheal intubation in the ICU may be life-saving or life threatening. Airway management in a deteriorating sick patient is a real ICU emergency which cannot be delayed. Rescue airway equipment as THRIVE, NIPPV, and tracheostomy should be ready as a backup when difficult airway is encountered. Fewer complications have been noticed when the TI was done by experienced providers. Familiarity with rescue airway techniques is helpful. The rhythm of ICU environment necessitates precise guidelines that are tailored to ICU settings. Hence, implementation of an intubation care bundle along with a pre-planned approach to difficult airway is essential for safe TI in the ICU.

2.6. Tracheal re-intubation

Particular issues as the need to re-intubate following a trial of extubation or accidental extubation are common in ICU. Re-intubation may be unexpectedly difficult in hypoxic, distressed, or uncooperative patients with multiple risk factors and in patients who have been extubated after prolonged intubation as airway edema is common sequela.

3. Videolaryngoscopy in ICU

3.1. Introduction

Videolaryngoscopy (VL) is an indirect visualization technique for the larynx mainly for the purpose of airway assessment or airway management especially in ICU area. The images from the video can be displayed, magnified, and recorded on a monitor. Video-assisted visualization has been evolved in airway practice after the pressing clinical need of difficult airway scenario and lack of new tools other than Macintosh/Miller blades. That was invented in 1940. After many years of clinical practice, the VL techniques have been approved by the American Society of Anesthesia (ASA) and incorporated in their difficult airway algorithms. VL is promoted as a first step to go in anticipated difficult airway scenario.

3.2. Indication or advantage over ordinary laryngoscopy

1. The first choice of elective oral or nasal intubation in adults, pediatrics, or neonates, in case of anticipated and unanticipated difficult laryngoscopy.
2. Reduces strain and stress of operator during intubation.
3. Diagnostic and recording of airway lesions, abnormal anatomy, and pathology.
4. Can be used for TEE probes [5], naso-gastric tube [6], double lumen bronchial tube [7], and throat-pack insertion.
5. VAFI techniques (video-assisted fiberoptic intubation).
6. Good teaching tool for junior staff.
7. Guide the assistant where to apply external laryngeal manipulation: BURP (Backward Upward Rightward Pressure).
8. Help presbyopic doctors especially in neonatal intubation.
9. Awake tracheal intubation [8] and in abnormal intubating position as lateral decubitus [9].
10. Less traumatic over ordinary laryngoscopy.
11. Reduce the cervical spine mobility in patients with unstable cervical spine or reduced spinal mobility [10].

3.3. Types of videolaryngoscopy (VL)

Many types have been introduced into the market, which has created many dilemmas for the practitioners which one to choose (**Table 1**). Each VL device is unique in its size, shape, and profile, which gives specific strength and weakness to each. As a dozen devices are being continuously added to the market, it would be challenging and impractical for the anesthesiologists to obtain and train on all of them. Ideal VL should be intuitive, lightweight, low profile, inexpensive, easily maneuverable, easy to learn and master, remote view screen, with memory storage capacity, and long-lasting rechargeable batteries. Special features are being added as antifog capabilities by heating of the lens. The device should be easily adaptable to different intubation techniques, for example, nasal and oral.

3.3.1. Video stylets

The rigid stylets were in practice for the last 25 years to facilitate retromolar intubation. The bending angle is 40° at the distal end with a view angle of 110°. The video RIFL has a rigid rod with a flexible tip to articulate till 135° by closing the lever by a handgrip.

The stylets are advocated when the mouth opening is limited; however, its applicability is restricted to oral intubation. The video stylets are bulky, requiring space in the room,

Rigid blades		Guided channels-Automatically shaped		Video stylets	
Standard blade	Angled blade	Channeled blade	Channeled airway	Rigid stylet	Rigid stylet + Flexing tip
Storz C-Mac	Coopdech VLP100	AirTraq	Total track (VLM) Video Laryngeal Mask	Bonfils	RIFL
	Storz DCI	Pentax AWS			Shikani optical stylet
	McGrath "AIRCRAFT"	Res-Q-Scope II			
	GlideScope				
Storz V-Mac	Storz D-Blade				
	King Vision				
	Venner A.P. Advance				
	MedAn				

Table 1. Summary of different types of VL devices.

with no antifogging mechanism. It has the longest intubation time among other video techniques and higher learning curve but is very useful in restricted mouth opening using retro-molar space. The Shikani optical stylet is a malleable, stainless steel, J-shaped endoscope with illumination fibers and a fiberoptic bundle that can be used with a separate camera and monitor system, or on its own with an optical eyepiece. **Figure 1** shows Bonfils retro-molar videolaryngoscope.




Figure 1. Bonfils retromolar videolaryngoscope (Storz-Company).

3.3.2. Channeled videolaryngoscopy

The representatives of the family are Pentax and AirTraq. All channeled devices have been designed mainly for oral intubation; however, the recent version of AirTraq has been studied and used in nasal intubation. The AirTraq is a single-use optical device with optional video camera attachment. It is available in different sizes and could be used for nasal intubation and double lumen tube insertion; however, it is single use and it requires 30–40 s to reduce fogging. Pentax is similar to AirTraq, with the advantage of the only plastic guide blades which are disposable. The tip is angled by 135° and it cannot be used with an endotracheal tube (ETT) less than 6.5, making it impractical for pediatric population. Both Pentax and AirTraq have been proved to reduce the cervical spine mobility in patients with unstable cervical spine or reduced spinal mobility. Res-Q-Scope is a similar device, but the clinical studies are so limited.

3.3.3. Rigid blades

Rigid blades are classified into standard blade or angled blade. In general, the standard blades use the various modifications of typical Macintosh blades as C-Mac (**Figure 2**). However, the angled blades offer more angulations near the distal tip to widen the view angle. In some equipment, as in Coopdech D-scope, sizes of 0,1 and Miller's blades are available, etc. C-scope sizes (sizes 0 and 1) Miller blades are available, but in most of the others Macintosh blades sizes 2, 3, and 4 are the standard.




Figure 2. Videolaryngoscopes.

It was shown that the design familiarity with standard Macintosh blades, side screen, and enhanced view has reduced the learning curve for the inexperienced providers.

The main difference among rigid blades is the blade angulation and the position of the side view screen. In Coopdech VLP100, it has a build-in screen on top of the device with the view angle of 39-52°, with the option of sizes 2, 3, and 4 Macintosh or size 0, 1 Miller blade. The McGrath "AIRCRAFT" is similar to Coopdech VLP100 in having a build-in side screen over the handle, but different in having adjustable variable length blades that snaps in place once the length is adjusted. The GlideScope (**Figure 3**) has an angulation of 60°, with antifogging camera, plastic disposable blades, and separate view screen. GlideScope appeared to be the most intuitive, easy to learn with the steepest learning curve [11] but a little bit bulky in relation to C-Mac blade; that is why most of clinicians prefer C-Mac over GlideScope. Venner A.P. Advance and MedAn videolaryngoscopes are also available in the market from these VL types but the clinical studies are so limited.

In general, not one device has shown to have a 100% success rate and none has shown to be superior to another. All studies concluded that VL offers better laryngoscopic view if not the same as direct laryngoscopy. Most of the studies have concluded that the intubation time is more with videolaryngoscopy than with the direct laryngoscopy. Relative devices were faster than others by few seconds, DCI Storz Videolaryngoscope is relatively faster by 10 s than GlideScope (34 s) and McGarh (38 s); other study showed that the time for intubation for GlideScope was 33 s, CMAC was 17 s, and McGarh was 41 s [12]. Intubation with the GlideScope has been found to be 99% successful after initial failure of direct laryngoscopy, helping to reduce the incidence of failed intubation. It should be noted that the relative learning curves could affect the performance of GlideScope in some studies, as in

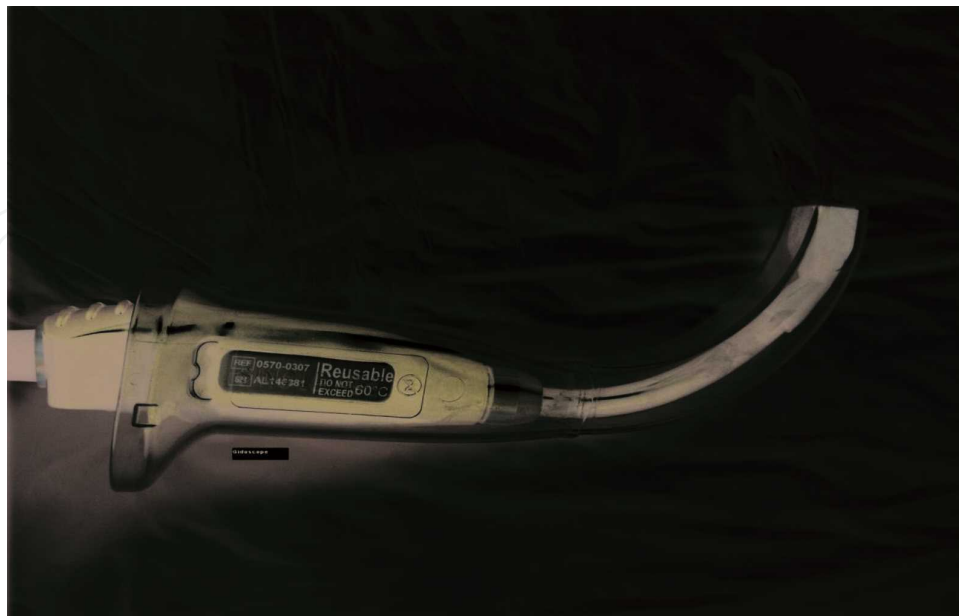


Figure 3. GlideScope (Verathon Inc., US).

the study of Platts-Mills in emergency department, which showed no difference in intubation failure between GlideScope and Macintosh, and intubation time in GlideScope was longer (12 s) [13] (**Figure 3**).

The main advantage for the videolaryngoscopy is minimal cervical spine mobility during intubation as the pharyngeal and laryngeal axis should not align together, offering least mobility for cervical instability. Moreover, it is helpful in case of limited accessibility, for example, magnetic resonance imaging (MRI) scanning, beach chair position, or prone position. It also allows sharing the airway view with beyond the operator for teaching or assistance purposes (**Figure 2**).

The devices of VL have been evaluated and adopted for practice outside the operative room.

3.4. Disadvantages of VL

The most common disadvantages of VL could be variable learning curve that depends on the level of training and experience, difficult passage of tube despite satisfactory laryngeal view, and loss of the depth perception. The fogging and secretion that could obstruct the camera are among other technical issues. Other disadvantage is the cost that could range from 5000 to 10,000\$, which could be a burden in some part of the world; however, the cost could be justifiable in the industrialized part of the world if it could prevent such fatal airway events with its subsequent million dollar lawsuits. One study for VL adoption in Massachusetts emergency departments in 2012 has showed that adoption rate for VL was 43%, a relatively fast rate. The 69% of non-adopters have attributed that to the cost of the device [14].

4. Flexible fiberoptic intubation in ICU

4.1. Introduction

It is an airway device used for indirect visualization of the airway either for airway management or for other diagnostic and therapeutic purposes. Traditionally, all old scopes have used the fiberoptic fiber technology; however, the newer scopes, out of reliability issues, do not use the fiberoptic technology anymore and that's why the nomenclature changed to flexible intubation scope.

4.2. Types

Flexible intubation scope is a flexible cord that has fiberoptic fibers (old scopes) or optical fibers with a small camera on the tip of the scope using complementary metal oxide semiconductor (CMOS) technology and the so-called flexible intubation video endoscope (FIVE) from Storz Company. The proximal handle has a working channel port for oxygen and suction, lever to flex or extend the tip and light source. The diameter of adult scope is of 3.8 and 4.2 mm which can hold ETT of 6.5 mm or more. The diameter of children scope is of 2.2 and 3.1 mm which can hold 3 and 4 mm EET, respectively. Both adult and pediatric

scopes have working channel of 1.2 mm. Most of flexible intubation scopes are reusable; however, recently a single-use flexible intubation scope started to be in the market from Ambu Company.

4.3. Indications

The main indication of flexible scope intubation (FSI) in anesthesia care and ICU settings is to secure the placement of endotracheal tube when there is anticipated airway difficulty and confirmation of tube position after intubation if necessary. It can be used as well in the management of abnormal airway anatomy, obstructive upper airway lesion, and unstable cervical spine to limit the cervical mobility, and the evaluation of airway obstruction is another anesthetic indication as a preoperative assessment (preoperative naso-endoscopy in pre-assessment anesthesia clinic) or directly prior to intubation for the patients with known anatomical abnormalities in the upper airway. The choice of the route has its indications as well, as nasal route is used in a case of limited mouth opening or a strong gag reflex, or if the surgery needs nasal intubation. Other indications other than primary anesthetic care involve diagnostic and therapeutic purposes, see **Table 2**.

4.4. Contraindications

There are no absolute contraindications for the FSI, but in the following situations difficult to impossible scenarios could be encountered. Large airway bleeding and secretions could make the view impossible. The limited clinical experience of the operator, the necessities for rapid airway control, the need to insert the tube under vision to minimize further trauma to the upper airway, and uncooperative patient are other contraindications. However, it is not absolute, as uncooperative patient can be intubated as sleep FSI and the visualization for ETT

Diagnostic indications	Therapeutic indications
<ul style="list-style-type: none"> • Evaluation of pneumonia, atelectasis, infiltrate of unclear etiology. • Evaluation of hemoptysis. • Evaluation of toxic burn inhalation. • Evaluation of chest trauma. • Evaluation of chronic cough. • Placement of artificial airways. • Evaluate complications of tracheostomy. • Evaluation of precancerous lesions. • Evaluation of tracheoesophageal fistula. • Evaluation of bronchopleural fistula. • Confocal microbronchoscopy. 	<ul style="list-style-type: none"> • Mucus impaction. • Foreign body removal. • Laser coagulation for lesions. • Photodynamic therapy. • Electrocoagulation. • Cryotherapy. • Dilation by balloon. • Brachytherapy. • Tracheobronchial stents. • Bronchopleural fistula. • Needle aspiration of mediastinal cysts.

Table 2. Indications of flexible scope intubation (FSI).

insertion could be achieved by adjuvant airway as in fiberoptic-assisted videoscopic intubation (FAVI), a technique, when other indirect visualization technique, as C-Mac VL (**Figure 2**), is used to facilitate the insertion of ETT under vision. Nasal route is contraindicated in case of severe craniofacial deformity and skull base fracture.

4.5. Preparation for flexible scope intubation (FSI)

The preparation step for FSI is the most important step for a successful procedure. It involves patient selection and preparation, airway anesthesia and equipment preparation. The patient selection will determine whether the FSI will be through the oral or nasal route and whether it will be awake or sleep FSI. Generally, the awake has better visualization than the deep, due to loss of muscle tone and pharyngeal collapse after induction of anesthesia.

4.5.1. Patient preparation

It starts by good communication with the patient and proper assessment of the underlying condition. Anti-sialagogues should be applied for all patients whether it is oral or nasal, as secretions do not only affect the view but also limit the action of the local anesthetics. Commonly, it is recommended to use intravenous 0.2 mg glycopyrrolate, 15 min before the procedure. For patients with high risk for aspiration, risk and benefit should be analyzed as airway anesthesia and long intubation time could compromise the airway reflexes and increase aspiration risk. Certain measures have been recommended to minimize that risk: as intubation in head-up position, administration of 0.3 M sodium citrate 30 ml and Metoclopramide 10 mg or Ranitidine 50 mg within 1 h before the start of the procedure. Patient positioning depends on the technique and patient and operator's preference as well. Positions could be sitting (beach-chair), lateral decubitus for awake FSI or supine positions for sleep FSI and prone position as a rescue technique.

Airway anesthesia is a critical step in the procedure. It can be done by applying the local anesthetic solutions, gel, or ointment by atomizer, nebulizer, or "spray as you go technique." Airway anesthesia equipment includes atomizing devices, nebulizers, syringes and needles, and cotton swabs.

Combined techniques are always recommended to optimize the outcome. Combination of 4% lidocaine nebulization, atomization spray to tongue, and oropharynx followed by "spray as you go" through the working channel of the scope using epidural catheter are commonly applied together.

Cautions should be taken not to exceed with the lidocaine dosage above 6 mg/kg to avoid systemic toxicity. Trans-tracheal local anesthetic infiltration and nerve blocks could be used with a skilled operator but it is not commonly done. Glossopharyngeal nerve block, superior laryngeal nerve block, sphenopalatine nerve block, and anterior ethmoidal nerve block are among the nerves that could be blocked; however, the discussion of each nerve technique will be beyond the scope of this chapter. For nasal anesthesia, vasoconstrictors as 1% phenylephrine or 0.05% oxymetazoline are added to the local anesthetics to minimize nasal bleeding.

Airway equipment includes flexible intubating scope, face mask, specialized oral airway, and endotracheal tube, antifogging agent, lubricating agent, nasopharyngeal airway, oral or nasal

mucosal atomization device (MAD) and video monitor. All equipment should be checked for functionality before any operation.

4.6. Technique

Oral intubation is the most common route. Stepwise approach should be followed: as ETT is loaded first to the scope, then oropharyngeal suction before insertion of scope, then applying of bite blocker or fiberoptic plastic airway (e.g., Ovassapian, Williams, or Berman). FSI should always be in the midline till satisfactory view is achieved. The working channel offers a source for suction, oxygen insufflation, or channel for epidural catheter during the procedure.

Nasal intubation has its advantage in avoiding the gag reflex; however, the chance of epistaxis is high. Topical nasal decongestant such as 0.05% oxymetazoline and 1% phenylephrine should be used to decrease the nasal mucosal irritation and bleeding.

Awake intubation necessitates patient cooperation, adequate airway anesthesia; however, sedation may be required. The patient is asked to swallow or breathe deeply and smoothly. Sedation could be titrated on individual basis, based on the underlying comorbidities. Commonly used sedation is Remifentanyl infusion starting with 0.05 µg/kg/min or Remifentanyl target-controlled infusion (TCI) mode with or without 1–2 mg Midazolam or Dexmedetomidine 0.3 µg/kg/h with or without Midazolam 1–2 mg or incremental doses of Midazolam 1 mg alone. Propofol TCI is another alternative to Midazolam as a sedative agent.

Sleep intubation could be done after induction of anesthesia in certain circumstances.

4.7. Strategies for success

It is important to keep in mind that FSI is a complex clinical procedure with requirements of special skills, which make even good preparation not enough to guarantee the success. Practicing certain adjuvant measures as strategies for enhancing the laryngoscopic view and facilitated ETT insertion could decrease the failure rate. Enhancing the view could be achieved by keeping airway patent by one or more of the following: jaw thrust, pulling tongue out by a gauze, fiberoptic oral airway placement, external laryngeal manipulation, insertion of laryngoscopic blade with lifting the epiglottis away from the pharyngeal wall (VAFI technique), and clearing the lens fogging by gentle touch of mucus membrane. Facilitated ETT insertion aims to minimize a possible trauma from the blind insertion of the tube after the FIS has reached the carina. The facilitation could be done by a 90° anticlockwise rotation of the tube to avoid getting caught at right arytenoid, warming the tube, flexible tube and combination of direct and indirect laryngoscopic technique or using video-assisted fiberoptic intubation (VAFI) technique.

4.8. Advantages

Flexible intubation scope is unique airway visualization equipment that offers great clinical help, not only in the management of difficult airway scenarios but also in the diagnosis and treatment as well. More details are described under bronchoscopy section.

4.9. Disadvantages

FSI is a complex procedure with no straightforward steps. To master the technique, it requires a lot of practice with high learning curve. Extra equipments are always necessary; moreover, it requires time for preparation and cannot help in emergency situation. Nasal epistaxis, minor airway trauma as erythema, and vocal cord injury could occur.

5. Bronchoscopy in ICU

5.1. Introduction

Flexible fiberoptic bronchoscopy is frequently used for diagnosis and therapy, performed in ventilated patients via an endo-tracheal tube or tracheostomy tube in ICU and other critical areas. Indication may be diagnostic or therapeutic (**Table 2**). *The most common indications* include clearance of retained secretion, mucous plug, lung collapse, endobronchial brush, removal of blood clot, diagnosis of ventilator-associated pneumonia by broncho-alveolar lavage (BAL), trans-bronchial biopsy, detection of airway lesions (e.g., neoplastic), endobronchial ultrasound (US), and visualization of instruments during percutaneous tracheostomy. Contraindications are relative so each patient should be carefully assessed for risk benefits. *Contraindications* include uncooperative patient, unstable patient as severe hypoxemia, hypercarbia, unstable asthma, recent myocardial infarction, or any situation of possible serious hemorrhage after biopsy as uremia, tracheal obstruction or stenosis and pulmonary hypertension.

5.2. Management of the airway for bronchoscopy

Separate operator should manage airway and ventilation. The bronchoscopist should be prepared to interrupt the procedure immediately if there is destabilization. Patients are pre-oxygenated, anesthetized, paralyzed, and ventilated on 100% O₂. Positive end expiratory pressure (PEEP) should be maintained. Impairment of gas exchange is common due to tube obstruction and when suction is applied through the scope.

Endotracheal tubes smaller than 8-mm internal diameter may be significantly occluded by flexible fiberoptic bronchoscopy and this could impair ventilation and oxygenation. A lubricated swivel (or elbow) connector with a fitted rubber cap prevents loss of ventilation. If pressure-controlled ventilation is used, peak pressure setting should be increased to compensate for the loss of tidal volume. Suction periods should be limited to 5 s or less. Thick secretions often require instillation of saline (10–20 ml) down the injection port to dissolve them. During broncho-alveolar lavage (BAL), a sputum trap should be used between bronchoscope and wall suction.

5.3. Special situation with flexible fiberoptic bronchoscopy

- *Bleeding dyscrasias*: Coagulation studies, platelet counts, and hemoglobin concentration are necessary before the procedure especially when there are clinical risk factors for abnormal coagulation. Bronchoscopy with lavage can be performed with platelet counts of >20,000 per/ μ l.

- *Pneumothorax*: A chest radiograph should be obtained if a patient is symptomatic or if there is a clinical suspicion of possible pneumothorax after trans-bronchial biopsy. Patients should be advised of the potential for delayed complications following trans-bronchial biopsy.
- *Fever and infection*: Antibiotic prophylaxis is not warranted before bronchoscopy for the prevention of endocarditis, fever, or pneumonia.
- *Ischemic heart disease*: flexible fiberoptic bronchoscopy should ideally be delayed for 4 weeks after MI.

6. Percutaneous tracheostomy

6.1. Introduction

Mechanical ventilation can be delivered to the patient who requires ventilatory support either initially through endotracheal tube (ETT) for short-term period or through tracheostomy tube, in cases where the respiratory support will be prolonged due to underlying medical reasons [15].

Tracheostomy versus intubation: The relative advantages and disadvantages of tracheostomy and endotracheal intubation are outlined in **Table 3** [16–20].

Tracheostomy techniques: Bedside percutaneous tracheostomy is an alternative to operative (open) tracheostomy, as it could be done either at the bedside or in the operating room. Successful performance of the bedside percutaneous procedure is related to the expertise of the operator and supportive personnel. Surgeons or well-trained critical care clinicians could do with fewer complications. Choosing between open or percutaneous tracheostomy depends upon the availability of each procedure and institutional expertise.

	Intubation	Tracheostomy
Advantage	<ul style="list-style-type: none"> • Highly skilled personnel are required. • Stoma complication is less. • Procedural complication is less. 	<ul style="list-style-type: none"> • Ability to speech, swallowing. • Ability to mobile and discharged outside ICU. • Easy suction. • Better patient satisfaction and comfort.
Disadvantage	<ul style="list-style-type: none"> • Possible mouth, nasal or laryngeal injury. • Cuff pressure complication. • Requirement of tube exchange or possible ICU care. 	<ul style="list-style-type: none"> • Cuff pressure complication. • Stoma and fistula complications. • Possible laryngeal injury, pulmonary and mediastinum complication. • Mortality complication due de-cannulation in improper time.

Table 3. Advantage and disadvantage tracheostomy versus intubation.

Percutaneous versus operative: Percutaneous tracheostomy offers numerous advantages compared to operative tracheostomy: it requires less time to perform, it is less expensive, and it is typically performed sooner (because an operating room doesn't have to be scheduled). In addition, overall complications may be less frequent with percutaneous tracheostomy than surgical tracheostomy, even though percutaneous tracheostomy has an increased risk of anterior tracheal injury and posterior tracheal wall perforation.

Data describing outcomes comparing both techniques are conflicting, which may reflect the different techniques used to perform percutaneous tracheostomy (e.g., ultrasound-guided, bronchoscopy-guided, dilatational, other).

6.2. Complication

Infection: In two meta-analyses of randomized controlled trials, percutaneous dilatational tracheostomy reduced wound infections (e.g., odds ratio: 0.28, 95% CI: 0.16–0.49) compared to both surgical tracheostomy performed in the ICU and surgical tracheostomy performed in the operating room. A separate meta-analysis of 29 randomized and non-randomized studies reported a similar reduction in the rate of wound infection with percutaneous tracheostomy [21].

Bleeding and mortality: When compared to surgical tracheostomy performed in the operating room, only percutaneous dilatational tracheostomy has also been associated with reduced bleeding (odds ratio: 0.29, 95% CI: 0.12–0.75) and mortality (odds ratio: 0.71, 95% CI: 0.50–1.0). A similar reduction in overall mortality was reported in another 10-year review of 616 trauma patients that compared those who underwent percutaneous tracheostomy with those who underwent open tracheostomy (10 vs. 15%) [17].

By contrast, another meta-analysis of 20 trials reported no difference in mortality or major bleeding [18]. In a separate meta-analysis, perioperative complications (including death, serious cardiorespiratory events, and minor complications) were rare, but more common with percutaneous tracheostomy than with surgical tracheostomy. In another meta-analysis of 29 studies, no significant difference in bleeding or tracheal stenosis was reported [20].

Scarring: While one meta-analysis reported no difference in the rate of tracheal stenosis or scarring, another reported significant reduction on the rate of scarring.

Taken together, the data suggest that percutaneous dilatational tracheostomy offers numerous advantages compared to surgical tracheostomy. However, the benefit of percutaneous tracheostomy may be substantially less dependent upon the technique employed.

6.3. Contraindications

Relative contraindications to percutaneous tracheostomy include age under 15 years of age; uncorrectable bleeding diathesis; gross distortion of the neck from hematoma, tumor, thyroid gland enlargement, or scarring from previous neck surgery; documented or clinically suspected tracheomalacia; evidence of infection in the soft tissues of the neck; obese and/or short neck which obscures landmarks; and inability to extend the neck because of cervical fusion, rheumatoid arthritis, or other causes of cervical spine instability.

It should be reiterated that these contraindications are relative. Percutaneous dilatational tracheostomy has been performed successfully by skilled operators in patients who were very old, were morbidly obese, had a history of previous tracheostomy, or had thrombocytopenia (the patients received pre-procedure platelet transfusions). It has also been performed successfully in patients receiving high-frequency oscillation ventilation or positive end expiratory pressure (PEEP) at a level of >10 cm H₂O.

A study that evaluated the rates of bleeding complications during percutaneous tracheostomy showed that bleeding complications could be predicted by a platelet count less than 50,000/ μ l, an activated partial thromboplastin time longer than 50 s, or the presence of two or more coagulation disorders. Administration of prophylactic subcutaneous heparin did not increase the risk of bleeding [18].

For patients undergoing a bronchoscopic-guided percutaneous tracheostomy, a bedside checklist, similar to that performed for open tracheostomy performed in the operating room, may be associated with reduced procedural complications.

6.4. Complications

Acute: The most common acute (e.g., first few days) complications include obstruction and pneumothorax as well as postoperative hemorrhage and infection.

Obstruction: Percutaneous tracheostomy tubes can become partially obstructed by the posterior membranous trachea following initial placement, although symptomatic obstruction is uncommon. This complication appears to be related to the experience of the clinician performing the procedure. However, the swelling of the posterior tracheal wall could cause symptomatic compression of the tube up to 1 week after placement.

Subcutaneous emphysema and pneumothorax: The incidence of subcutaneous emphysema and pneumothorax is 1.4 and 0.8%, respectively [19]. Cadaver models revealed that imperfect positioning of fenestrated cannula and posterior wall perforation are possible mechanisms for these complications [19].

Chronic complications of tracheostomy (i.e., weeks and months) that are specific to tracheostomy include the following:

- *Tracheal stenosis:* Granulation tissue is the main reason for tracheal obstruction in patients under long mechanical ventilation by tracheostomy, which differs from the stenosis that develops in endotracheal tube that will be appearing earlier and be web-like. Stenosis of the trachea is not only below the tracheostomy tube, but it may occur above the tracheal stoma but below the glottis. That could contribute to high-peak airway pressures and difficulty in weaning. Treatment includes the placement of a longer tracheostomy tube, surgical intervention, or the placement of a tracheal stent [20].
- *Tracheoarterial fistula:* Massive hemorrhage due to a tracheoarterial fistula is the most devastating complication. Tracheoarterial fistula (most often a tracheoinnominate artery fistula) was more common in the past from low-positioned tracheostomy tubes and is now rarely encountered

with several studies reporting an incidence of <1% in both short-term and long-term tracheostomies [21]. The development of a tracheoarterial fistula is a life-threatening complication with a reported survival of 14%. Tracheoarterial fistulas are due to erosion from the tube tip or cuff into the anterior wall of the trachea resulting in a fistulous communication with the innominate artery as it passes anteriorly across the trachea. Patients may develop a “sentinel” bleeding followed by massive hemoptysis. Diagnosis is dependent upon a high index of suspicion, and when suspected, immediate action should be undertaken to stop the bleeding since diagnostic modalities such as angiography or bronchoscopy may lead to delay and death.

The following temporizing maneuvers may be performed while waiting for definitive therapy, which is surgical repair [22].

- In an attempt to compress the innominate artery, the tracheostomy or endotracheal tube cuff may be overinflated.
- If the above fails, an ETT may be placed orally, the tracheostomy removed, and the cuff inflated distal to the tracheostomy site.
- If that fails, a finger can be placed through the tracheostomy stoma and positioned distally into the trachea (“The little Dutch boy maneuver”); the finger is then pulled anteriorly to compress the artery against the sternum (pressure should be sufficient to lift the torso anteriorly). Pressure should be maintained during transport to the operating room. Ventilation and oxygenation need to be preserved with a bag-valve mask or intubation with an ETT orally.

Reduced phonation: Following tracheostomy, many patients experience a reduction in or loss of phonation, the duration of which may be prolonged or indefinite, and the effect of which can be devastating to some patients. Traditionally, speech valves are used in tracheostomized patients (with the cuff deflated) who successfully wean from mechanical ventilation and are able to self-ventilate. Preliminary data suggest that early phonation is feasible and may be beneficial when instituted during mechanical ventilation in tracheostomized patients. As an example, one randomized trial of 30 ventilated tracheostomized patients reported that early intervention with cuff deflation plus an in-line speaking valve during mechanical ventilation shortened the time to phonation by 11 days, when compared with late intervention using the standard approach. Further research is needed before in-line speaking valves can become routine for this population [22].

Others: Tracheoesophageal fistula is more commonly encountered with prolonged endotracheal intubation and is discussed separately.

Although not studied in a randomized trial, the complication rate associated with tracheostomy may be increased in obese patients with a body mass index of ≥ 35 [22].

Changing a tracheostomy tube: There are no universally accepted indications for changing a tracheostomy tube. Therefore, the following indications are based on clinical experience rather than on empirical evidence:

Routine changes: Tracheostomy tubes are routinely changed from 7 to 14 days after initial insertion and then every 60 to 90 days. Observational data suggest that changing the tracheostomy tube before 7 days may be associated with earlier use of a speaking valve and earlier ability to

tolerate oral intake. A consensus statement recommends changing the tracheostomy tube at 3–7 days if inserted operatively but 10–14 days if placed via the percutaneous dilatational method.

Patient discomfort: Patient discomfort may respond to a reduction in the size of the tracheostomy tube.

Malposition: Tracheostomy tube malposition may respond to a change in the length or size of the tracheostomy tube.

Patient-ventilator asynchrony: Patient-ventilator asynchrony that is related to the tracheostomy tube may respond to changing the tube.

Cuff leak: A cuff leak may be due to malposition of the tracheostomy tube (particularly in the setting of tracheomalacia) and may respond to changing the tube.

Fracture: Fracture of the tracheostomy tube or flange is an indication for a new tracheostomy tube.

Type change: Changing a tracheostomy tube from one type to another may be indicated by the clinical circumstances; as an example, changing from a balloon cuff to either a foam cuff or a cuff-less tracheostomy tube.

Bronchoscopy: Flexible bronchoscopy generally requires a tracheostomy tube with an inner diameter of at least 7.5 mm; thus, the tracheostomy tube may need to be changed to one with a larger inner diameter to facilitate bronchoscopy.

Decannulation: Appropriate candidates for tracheal decannulation after weaning from mechanical ventilation include patients who fulfill all the following criteria:

No upper airway obstruction, ability to clear secretions that are neither too copious nor too thick, and presence of an effective cough. In patients with neuromuscular disease, a peak cough flow greater than 160 ml/min generally predicts successful decannulation. The value of this measurement in patients without neuromuscular disease is unknown.

Failed decannulation has been associated with age, greater severity of illness, the presence of renal failure, and a shorter duration of spontaneous breathing prior to decannulation or the insertion of a tracheostomy plug.

7. Extubation in ICU

7.1. Introduction

The removal of endotracheal tube (ETT) termed as extubation is the last step of ventilatory weaning. Extubation step necessitates consideration of patient condition, experience with extubation techniques, and post-extubation management.

Before extubation: Successful weaning from mechanical support is not the only prerequisite for safe extubation. Extubation is carried on patent airway with adequate airway reflex after independence from ventilatory support.

Airway protection: Airway protection requires a conscious patient with a strong cough reflex and minimal secretions.

Typical criteria for successful weaning: Fully awake and cooperative, good muscle tone and function, intact bulbar function, stable hemodynamic, no dysrhythmias, Hb greater than 8.0 gm%, minimal inotropic requirements, optimal fluid balance, respiratory $\text{FiO}_2 < 0.4$, PEEP < 10 cm H_2O , no significant respiratory acidosis ($\text{pH} > 7.3$ or $\text{PaCO}_2 < 6.5$ kPa), good cough, normal metabolic pH, normal electrolyte balance, non-distended abdomen, adequate nutritional status, normal CO_2 production, and normal oxygen demands [23].

Some patients will be extubated without difficulty and others will rapidly deteriorate as a result of inadequate respiratory effort or clearance of secretions. Those patients will require re-intubation, ventilation, and another period of optimization and consideration for tracheostomy. Some patients will benefit from weaning straight onto mask CPAP or NIV [23].

Difficult extubation: Extubation of a patient with a known difficult airway requires careful planning in anticipation for potential re-intubation. If there are doubts about airway patency prior to extubation, then direct laryngoscopy, fiberoptic bronchoscopy, and assessment of leak upon cuff deflation are useful checks. Patients who are considered likely to be difficult to re-intubate can be extubated with an airway exchange catheter in situ, to allow rapid re-intubation. Intravenous dexamethasone, nebulized adrenaline, and Heliox have been used with variable success in such circumstances.

Risk factors for extubation failure are peak expiratory flow rate (PEFR) of ≤ 60 L/min, sputum volume production of > 2.5 ml/h, and compromised neurological status. Combination of three risk factors reliably predicts extubation failure by 100% compared to 3% if no risk factor mentioned above is present [24].

Post-extubation management: Post-extubation care includes suctioning, bronchodilator therapy, diuresis, or noninvasive ventilation (NIV). Those measures could aid to prevent re-intubation by improving the oxygenation and airway clearance.

Oxygen (including high-flow nasal cannula (HFNC)): Every patient should be oxygenated post-extubation. We prefer using devices that provide adequate oxygenation and comfort for the patient. For most patients, this goal is achieved with low-flow devices (nasal prongs, simple, or venturi face masks). When higher flows of oxygen are required, high-flow nasal cannula (HFNC) may offer improved oxygenation, provide a small amount of positive end expiratory pressure (PEEP), and is better tolerated when compared with oxygen delivered through low- or high-flow face masks.

The efficacy of HFNC in the post-extubation setting was best illustrated in a trial of 527 patients who were mechanically ventilated for an average of only 1–2 days and considered to be at low risk for re-intubation following extubation. Compared to conventional low-flow oxygen therapy, HFNC reduced the rate of re-intubation at 72 h (5 vs. 12%) as well as the rate of respiratory failure (14 vs. 8%). However, methodologic flaws such as imperfect blinding and the high proportion of postsurgical and neurologic patients, where HFNC may have improved secretion clearance, may have biased results in favor of HFNC. Although encouraging, this trial does not support the routine use of HFNC following extubation [25].

In addition, while further studies are required to clarify who benefits the most from HFNC after extubation, its use in those who are severely hypoxemic is appropriate (e.g., partial arterial pressure of oxygen/fraction of inspired oxygen ratio <300). Further details regarding HFNC in other medical and postoperative populations and efficacy compared with NIV in post-extubation patients are discussed separately.

8. High-flow nasal cannula (HFNC)

8.1. Introduction

Different names and descriptions of this therapy:

HFNC: High-Flow Nasal Cannula.

THRIVE: Transnasal Humidified Rapid Insufflation Ventilatory Exchange.

POINT: Perioperative Oxygenation Insufflatory Nasal Therapy (**Figure 4**).

Or transnasal insufflation or nasal high-flow or nasal high-flow ventilation or high-flow therapy or high-flow nasal cannula oxygen therapy.

HFNC oxygen delivery system involves a mixture of oxygen/air, an active humidified, heated circuit, and nasal cannula. The active heater and humidifier are able to deliver heated and humidified high flow reaching 60 L/min than has many physiological advantages. High flow is able to reduce dead space by maintaining PEEP inside the airway and supplying constant fraction of oxygen. In spite of limited evidence in literature in ICU, it has gained popularity among physicians in various critical conditions. The existing evidence in neonates proves that HFNC decreases the work of breathing by reducing the respiratory rate and sufficiently supports the patient ventilation, reducing the escalation of ventilator support [26].



Figure 4. High-flow nasal cannula (HFNC) (Aqua VENT FD 140® from Armstrong Medical Company, Northern Ireland).

As the evidence is still evolving, still the indications and contraindications should be considered for each case individually.

8.2. Indications

- Hypercapnic respiratory failure.
- Hypoxemic respiratory failure.
- Post-extubation.
- Pre-intubation oxygenation.
- Sleep apnea.
- Acute heart failure.

8.3. Contraindication

- Bilateral nasal blockade as postnasal operations.
- Nasal bleeding.
- Nasal tumors.
- Nasal infection.
- It is also unlikely that HFNC can readily rescue those patients who have total airway obstruction and its use in the presence of a known or suspected cranial base fracture is also not advised.

8.4. Advantages

- Better tolerated in some patients than face masks.
- Fixed performance, permitting accurate delivery of up to 100% oxygen in most clinical situations.
- Gas is warmed and humidified.
- Low-level positive airways pressure is possible.
- An additional benefit is that nasal high-flow devices have been shown to produce positive airway pressures of over 5 cm H₂O, thus permitting their use in place of low-level CPAP [26].
- It is an open system and we do not have to care about the tight contact of interfaces, and HFNC can be applicable to patients with claustrophobia.

8.5. Disadvantages

- Results of large-scale clinical trials are still awaited.

- More expensive than standard oxygen delivery devices.
- Not yet available in all hospitals, and rarely outside of critical care.

9. Usage of supraglottic airway devices (SGAD) in ICU

9.1. Introduction

Airway management in the critical care is challenging and differs from the operating theatre. The supra-glottic airway devices (SGADs), especially the laryngeal mask airway (LMA), provide a fast and lifesaving way in the critical events.

9.2. Advantages

- Can solve “Cannot Intubate, Cannot Ventilate” (CICV) scenario.
- Passing a Bougie through it, then intubation over a Bougie or using an Aintree Intubating Catheter (Cook Critical Care, Bloomington, IN, USA).
- Bronchoscopy through LMA.
- Used as an airway while performing a tracheostomy.
- Ventilation during cardiac arrest instead of an ETT, if no skilled staffs are available.
- Minimal skills requirements to use an LMA.
- No muscle relaxant is required.
- No contact with vocal cords, less irritating than ETT.

9.3. Disadvantages

- No guarantee for a good airway, as the tip may fold on itself blocking the airway.
- No good seal with no protection from aspiration.
- Intubating through the LMA could be problematic. As it has shown that the LMA opening sits perfectly above the cords only in 45–60% of the time [27]. This means almost half of the time the LMA is directing the ETT away from the cords. The situation is worse in difficult airway as the provider was perfectly capable of shoving the tube the wrong way without any help.

9.4. Evidence for and against the use of LMAs in critical care

- Experts have recommended the use of LMA in a “Cannot Intubate, Cannot Ventilate” (CICV) scenario while waiting for a better airway. It has shown that LMAs have saved lives in such situations [28].

- The dilemma of LMAs not offering a good seal has no effect on clinical outcomes. Risk of aspiration has never been demonstrated, even with the old generations of LMA [29].
- No difference between the LMA and routine bag-mask and ETT anesthesia [29]
- Using the LMA as an airway while performing a tracheostomy has no sufficient evidence in the literature. There is no difference in the rate of complications, but the tracheostomies involving LMAs seemed to be quicker, may be due to less time to adjust the ETT cuff above the cords [30].

10. Endotracheal tube exchanger in ICU

10.1. Indications

- Mostly due to a cuff leak.
- The need for a different endotracheal tube (ETT) size as when smaller one is needed in patients with vocal cord edema or larger ETT for flexible bronchoscopy procedure.
- Change of special types of ETT like reinforced or double lumen to ordinary ETT.

10.2. Complications

However, exchanging the ETT may be life-threatening and lead to

- Esophageal intubation.
- Loss of the airway.
- Severe hypoxia.
- Cardiac arrest.

The risk may be more in those with a difficult airway or those with poor cardiopulmonary reserve.

10.3. Techniques

The ideal way for ETT exchange has not yet been studied. Experienced team with advanced airway skills should be consulted prior to ETT replacement.

The ETT placement can be done under direct laryngoscopy or indirect laryngoscopy with or without a Bougie guide. The initial airway assessment by direct laryngoscopy will determine which tool should be used. When a good laryngeal view is obtained by direct laryngoscopy, ETT can be introduced safely; however, in difficult laryngeal view, video laryngoscopy should be sought. Intubation medications are recommended to be used as well in tube exchange. Video laryngoscopy has been shown, compared with historical controls, to reduce the number of attempts at ETT exchange, with fewer complications including hypoxemia, esophageal intubation, bradycardia, and need for rescue airway device intervention [31].

11. Virtual endoscopy and 3D reconstruction of airway

Virtual endoscopy (VE) (**Figure 5**) is a noninvasive technology by which two-dimensional (2D) or three-dimensional (3D) images are reconstructed by computer software from high-resolution computed tomography (CT) scan (**Figure 6**). Virtual bronchoscopy was initially reported in 1993, but it was modified in 1996 to be used in virtual laryngoscopy. The virtual images reconstructed by software have comparable quality of fiberoptic views with sensitivity of 100% to detect upper airway lesions [32, 33]. The novel application of virtual laryngoscopy is eminent in the assessment and staging of upper airway lesion, comprehensive preoperative airway assessment, and planning of complex reconstructive upper airway surgeries. The “fly-through” reconstructions provided accurate and comparable images to fiberoptic bronchoscopy, which provided valuable information for the evaluation of the airway passages in a step forward prior to going to the difficult airway management (**Figure 5**). The utilization of the 3D imaging package is now commercially available within the workstation delivered by the different vendors worldwide, to obtain 3D models of the airway. This approach will be the added value and advantage that most anesthetists and intensive care physician would be able to use this technology to construct VE images of the airway from existing CT images and find them easy to interpret (**Figure 7**).

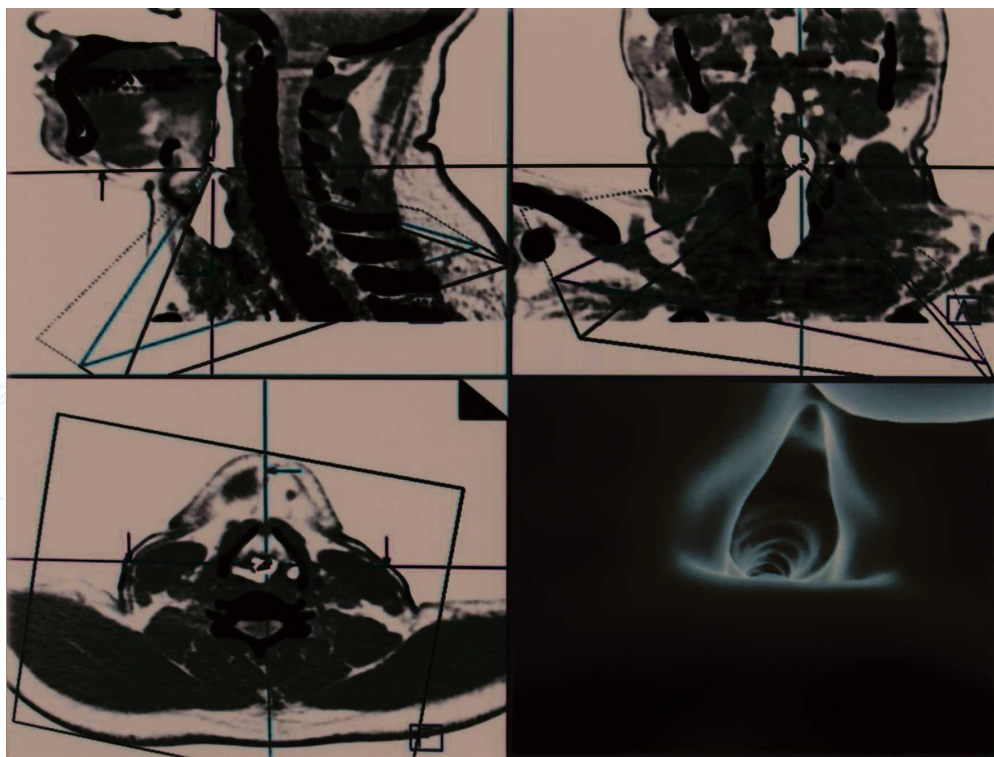


Figure 5. Virtual endoscopic evaluation of the air way. The vocal cords are well demonstrated. The accompanied reference images in axial, coronal, and sagittal planes with the virtual endoscope are noted, and its apex represents the eyepiece while the base represents the virtual lens.

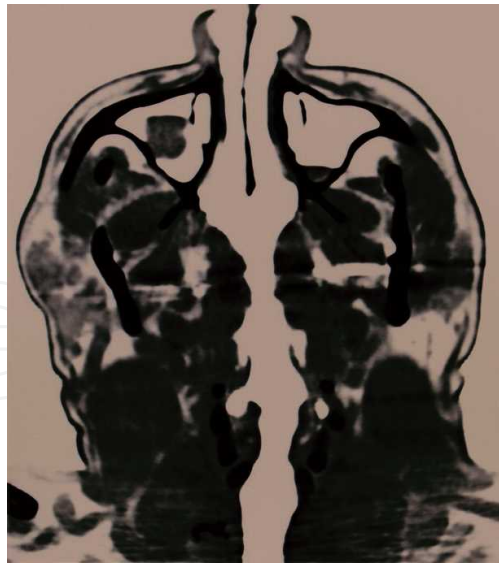


Figure 6. Curved MPR multi-planar reconstruction of the airway showing the entire airway in single plane from the nares down to the trachea allowing accurate measurement and orientation of the airway caliber at the different levels.

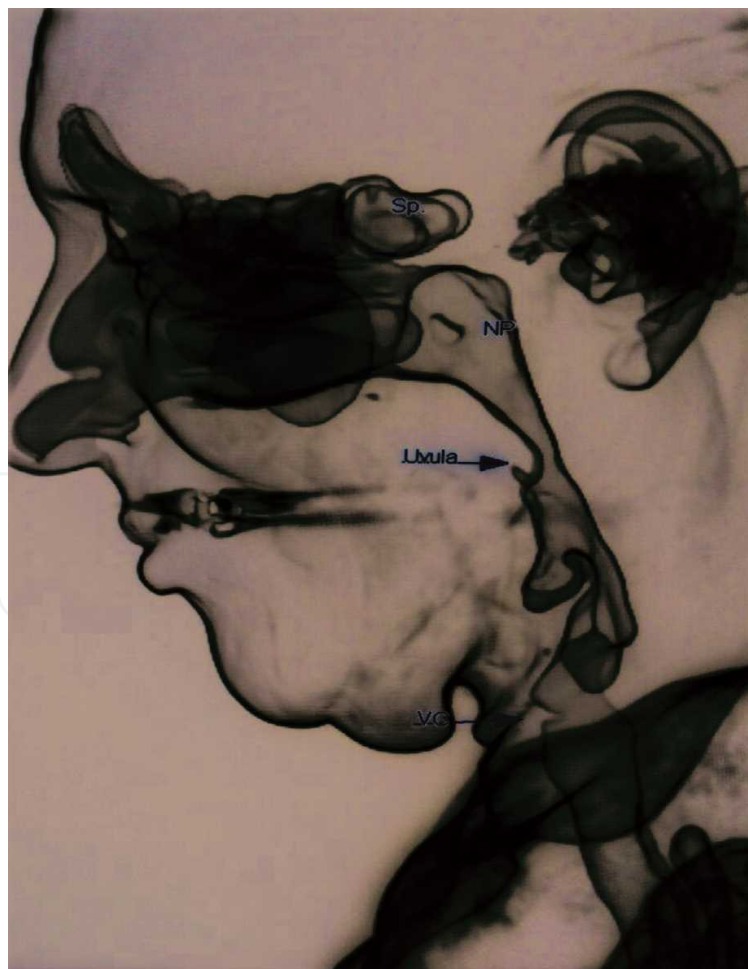

Figure 7. Lateral projections of the SSD-shaded surface display using volume-rendering techniques for the airway. SP: sphenoid sinus; NS: nasopharynx; VC: vocal cord.

This state-of-the-art technology has a promising future value in airway management for both anesthesiologists and intensivists as they will be able to easily interpret the airway images by noninvasive way (**Figure 8**).

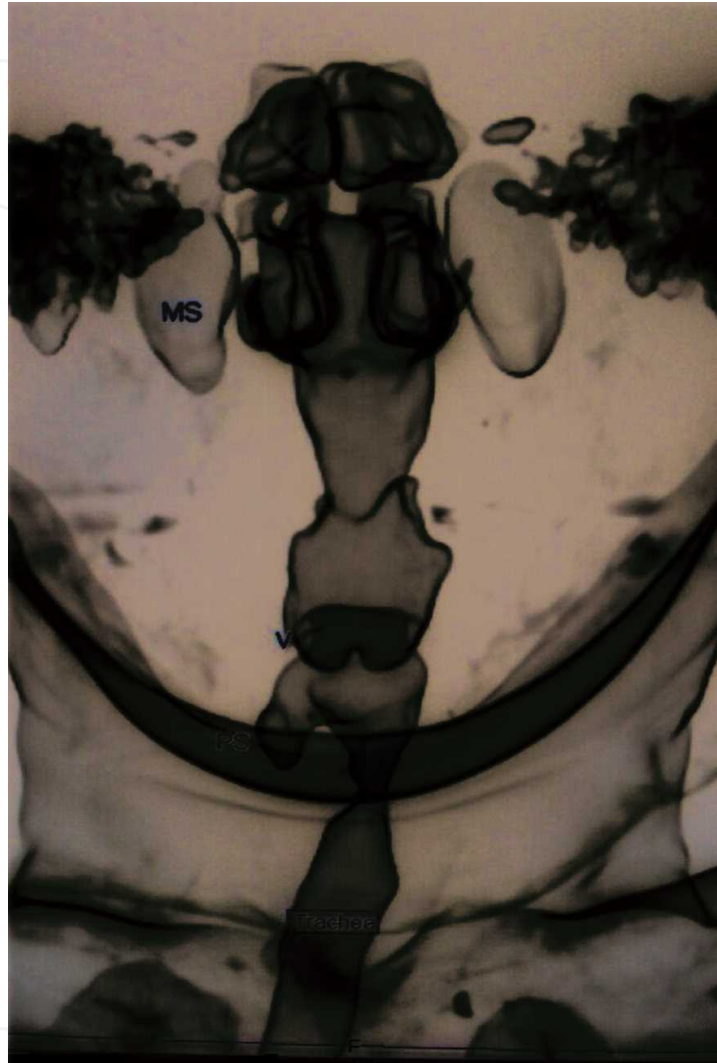


Figure 8. Antero-posterior (AP) curved MPR multi-planar reconstruction of the airway showing the entire airway in single plane from the nares down to the trachea allowing accurate measurement and orientation of the airway caliber at the different levels. MS: maxillary sinus; V: vallecula; PS: piriform sinus.

12. Ultrasound in airway management

12.1. Introduction

Ultrasound (US) examination of the upper airway in critically ill patients supplies a number of attractive advantages compared with competitive traditional imaging techniques or endoscopy. It is widely available, portable, repeatable, relatively cheap, pain-free, safe, and bedside machine in every operating theater and ICU suite.

12.2. Uses in airway management

- Locate the anatomy of major vessels and the thyroid gland in relation to tracheostomy site [34].
- Localize tracheal rings and cricothyroid membrane (**Figure 9**).
- Identify midline, puncture site for percutaneous tracheostomy.
- Checking of endotracheal intubation and detection of esophageal intubation [34].
- Estimation of gastric content [35].
- Recognize the air-tissue border from tongue to mid-trachea and at the pleural level [36].
- Localize the trachea by combining palpation of the sternal bone with US.
- Identify the “string-of-pearls” sign that identifies the tracheal rings and mark the cricothyroid membrane as part of difficult airway management skills [34].
- Recognize sonographic evidence of lung movement during respiration and exclude a pneumothorax [34].
- Recognize endobronchial intubation and one-lung ventilation [36].

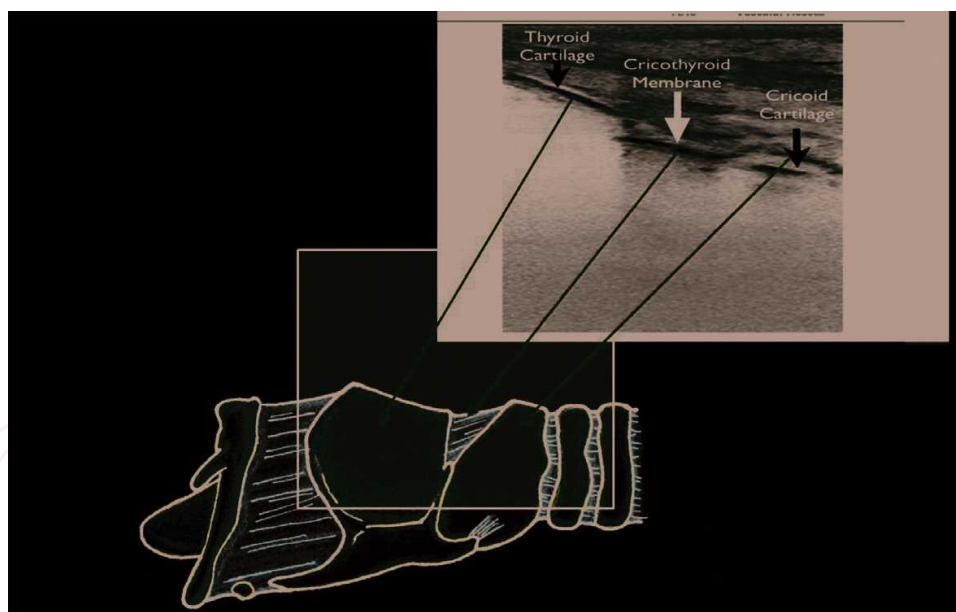


Figure 9. Ultrasound images of larynx and trachea rings.

13. Recommendations

The airway competence in ICU should be coping with the rapidly evolving advances in airway management. Therefore, efforts should be focused on the three pillars of airway

mastery: airway providers as intensivists or critical care physicians, equipment, and operational plans. Not all institutions can afford all airway equipment in the market; however, they should make sure that critical care providers have a full access to the available tools and they are comfortable using it. Educational sessions and refresher courses should be tailored to meet the competence level of the ICU providers and equipment availability. Operational plan includes developing institutional airway protocols and implementing difficult airway guidelines. The protocols should consider different staffing models of ICU and make sure all the time at least one member of the team with the highest experience in airway should be always available.

14. Key points

- Airway management in intensive care patients may be lifesaving or life threatening.
- Maintenance of patent airway, adequate ventilation, and pulmonary gas exchange are very important in critically ill patients. Airway management in intensive care patients differs significantly from routine surgical procedures in the operating room.
- Critical care physicians should be familiar with the equipment and the techniques to maintain and secure the airway.

Competing interests

The authors declare that there are no competing interests.

Author details

Nabil Abdelhamid Shallik^{1,2,3,4*}, Mamdouh Almustafa⁵, Ahmed Zaghw⁵ and Abbas Moustafa^{6,7}

*Address all correspondence to: nshallik@hamad.qa

1 Hamad Medical Corporation, Clinical Anesthesiology, Weill Cornell Medical College in Qatar, Doha, Qatar

2 Anesthesia and ICU Department, Tanta Faculty of Medicine, Tanta, Egypt

3 Anesthesia Section of Rumailah Hospital, Anesthesia, ICU and Perioperative Medicine Department HMC, Doha, Qatar

4 Medical Education and Qatar Robotic Surgery Center, HMC, Doha, Qatar

5 Department of Anesthesia, ICU and Perioperative Medicine, HMC, Doha, Qatar

6 Elminia University, Egypt

7 Radiology, HMC, Doha, Qatar

References

- [1] Schwartz DE, Matthay MA, Cohen NH. Death and other complications of emergency airway management in critically ill adults. *Anesthesiology*. 1995;**82**:367-376
- [2] Jaber S, Amraoui J, Lefrant JY, Arich C, Cohendy R, Landreau L, et al. Clinical practice and risk factors for immediate complications of endotracheal intubation in the intensive care unit: A prospective, multiple-center study. *Critical Care Medicine*. 2006;**34**:2355-2361
- [3] Adnet F, Jouriles NJ, Le Toumelin P, Hennequin B, Taillander C, Rayeh P, et al. Survey of out-of-hospital emergency intubations in the French prehospital medical system: A multicenter study. *Annals of Emergency Medicine*. 1998;**32**:454-456
- [4] Griesdale DE, Bosma TL, Kurth T, Isac G, Chittock DR. Complications of endotracheal intubation in the critically ill. *Intensive Care Medicine*. 2008;**34**:1835-1842
- [5] Tagawa T, Sakuraba S, Okuda M. Pentax-AWS-assisted insertion of a transesophageal echocardiography probe. *Journal of Clinical Anesthesia*. 2009;**21**(1):73-74
- [6] Roberts JR, Halstead J. Passage of a nasogastric tube in an intubated patient facilitated by a video laryngoscope. *The Journal of Emergency Medicine*. 2011;**40**(3):330
- [7] El-Tahan M, Doyle DJ, Khidr AM, Hassieb AG. Case report: Double lumen tube insertion in a morbidly obese patient through the non-channeled blade of the King Vision™ Videolaryngoscope. *F1000 Research*. 2014;**3**:129. DOI: 10.12688/f1000research.4481.3
- [8] Kajekar P, Mendonca C, Danha R, Hillermann C. Awake tracheal intubation using Pentax airway scope in 30 patients: A case series. *Indian Journal of Anaesthesia*. 2014;**58**:447-451
- [9] Shinohara H, Ishii H, Kakuyama M, Fukuda K. Morbidly obese patient with a huge ovarian tumor who was intubated while awake using airway scope in lateral decubitus position. *Masui*. 2010;**59**:625-628
- [10] Hirabayashi Y, Fujita A, Seo N, Sugimoto H. A comparison of cervical spine movement during laryngoscopy using the Airtraq or Macintosh laryngoscopes. *Anaesthesia*. 2008;**63**(6):635-640
- [11] Siu LW, Mathieson E, Naik VN, Chandra D, Joo HS. Patient- and operator-related factors associated with successful GlideScope intubations: A prospective observational study in 742 patients. *Anaesthesia and Intensive Care Journal*. 2010;**38**(1):70-75
- [12] Maassen R, Lee R, Hermans B, Marcus M, van Zundert A. A comparison of three videolaryngoscopes: The Macintosh laryngoscope blade reduces, but does not replace, routine stylet use for intubation in morbidly obese patients. *Anesthesia and Analgesia*. 2009;**109**(5):1560-1565
- [13] Platts-Mills TF, Campagne D, Chinnock B, Snowden B, Glickman LT, Hendey GW. A comparison of GlideScope video laryngoscopy versus direct laryngoscopy intubation in the emergency department. *Academic Emergency Medicine*. 2009;**16**(9):866-871

- [14] Raja AS, Sullivan AF. Adoption of video laryngoscopy in Massachusetts emergency departments. *The Journal of Emergency Medicine*. 2012;**42**(2):233-237
- [15] Diehl JL, El Atrous S, Touchard D, et al. Changes in the work of breathing induced by tracheotomy in ventilator-dependent patients. *American Journal of Respiratory and Critical Care Medicine*. 1999;**159**:383
- [16] Lin MC, Huang CC, Yang CT, et al. Pulmonary mechanics in patients with prolonged mechanical ventilation requiring tracheostomy. *Anaesthesia and Intensive Care*. 1999;**27**:581
- [17] Lim CK, Ruan SY, Lin FC, et al. Effect of tracheostomy on weaning parameters in difficult-to-wean mechanically ventilated patients: A prospective observational study. *PLoS One*. 2015;**10**:e0138294
- [18] Mohr AM, Rutherford EJ, Cairns BA, Boysen PG. The role of dead space ventilation in predicting outcome of successful weaning from mechanical ventilation. *The Journal of trauma*. 2001;**51**:843.
- [19] Fikkers BG, van Veen JA, Kooloos JG, et al. Emphysema and pneumothorax after percutaneous tracheostomy: Case reports and an anatomic study. *Chest*. 2004;**125**:1805.
- [20] Koitschev A, Graumueller S, Zenner HP, et al. Tracheal stenosis and obliteration above the tracheostoma after percutaneous dilational tracheostomy. *Critical Care Medicine*. 2003;**31**:1574.
- [21] Scalise P, Prunk SR, Healy D, Votto J. The incidence of tracheoarterial fistula in patients with chronic tracheostomy tubes: A retrospective study of 544 patients in a long-term care facility. *Chest*. 2005;**128**:3906
- [22] Arola MK. Tracheostomy and its complications. A retrospective study of 794 tracheostomized patients. *Annales Chirurgiae et Gynaecologiae*. 1981;**70**:96
- [23] Coplin WM, Pierson DJ, Cooley KD, et al. Implications of extubation delay in brain-injured patients meeting standard weaning criteria. *American Journal of Respiratory and Critical Care Medicine*. 2000;**161**:1530
- [24] Thille AW, Boissier F, Ben Ghezala H, et al. Risk factors for and prediction by caregivers of extubation failure in ICU patients: A prospective study. *Critical Care Medicine*. 2015;**43**:61
- [25] Nishimura M. High- flow nasal cannula oxygen therapy in adults. *Journal of Intensive Care*. 2015;**3**:15
- [26] Patel A, Nouraei SAR. Transnasal Humidified Rapid-Insufflation Ventilatory Exchange (THRIVE): A physiological method of increasing apnoea time in patients with difficult airways. *Anaesthesia*. 2015;**70**:323-329
- [27] Benumof JL, et al. Laryngeal mask airway and the ASA difficult airway algorithm. *Anesthesiology*. 1996;**84**(3):686-699

- [28] Siddiqui S, Seet E, Chan WY. The use of laryngeal mask airway Supreme™ in rescue airway situation in the critical care unit. *Singapore Medical Journal*. 2014;**55**(12):205
- [29] Brimacombe JR, Berry A. The incidence of aspiration associated with the laryngeal mask airway: A meta-analysis of published literature. *Journal of Clinical Anesthesia*. 1995;**7**(4):297-305
- [30] Strametz R, et al. Laryngeal mask airway versus endotracheal tube for percutaneous dilatational tracheostomy in critically ill adult patients. *The Cochrane Database of Systematic Reviews*. 2014;**30**(6):CD009901
- [31] Mort TC, Braffett BH. Conventional versus video laryngoscopy for tracheal tube exchange: Glottic visualization, success rates, complications, and rescue alternatives in the high-risk difficult airway patient. *Anesthesia & Analgesia*. 2015;**121**(2):440-448
- [32] Finkelstein SE, Schrupp DS, Nguyen DM, Hewitt SM, Kunst TF, Summers RM. Comparative evaluation of super high-resolution CT scan and virtual bronchoscopy for the detection of tracheobronchial malignancies. *Chest*. 2003;**124**:1834-1840
- [33] Osorio F, Perilla M, Doyle DJ, Palomo JM. Cone beam computed tomography: An innovative tool for airway assessment. *Anesthesia & Analgesia*. 2008;**106**(6):1803-1807
- [34] Drescher MJ et al. Ultrasound of Esophageal Intubation. *Academic Emergency Medicine*. 2000;**7**(6):722-725
- [35] Perlas A, Mitsakakis N, Liu L, Cino M, Haldipur N, Davis L, Cubillos J, Chan V. Validation of a mathematical model for ultrasound assessment of gastric volume by gastroscopic examination. *Anesthesia & Analgesia*. 2013;**116**(2):357-363
- [36] Singh M, Chin KJ, Chan VW, Wong DT, Prasad GA, Yu E. Use of sonography for airway assessment: An observational study. *Journal of Ultrasound in Medicine*. 2010;**29**:79-85.