

We are IntechOpen, the world's leading publisher of Open Access books Built by scientists, for scientists

4,400

Open access books available

117,000

International authors and editors

130M

Downloads

Our authors are among the

154

Countries delivered to

TOP 1%

most cited scientists

12.2%

Contributors from top 500 universities



WEB OF SCIENCE™

Selection of our books indexed in the Book Citation Index
in Web of Science™ Core Collection (BKCI)

Interested in publishing with us?
Contact book.department@intechopen.com

Numbers displayed above are based on latest data collected.
For more information visit www.intechopen.com



Clinical Consideration and Management of Impacted Maxillary Canine Teeth

Belma Işık Aslan and Neslihan Üçüncü

Additional information is available at the end of the chapter

<http://dx.doi.org/10.5772/59324>

1. Introduction

Impaction is a retardation or halt in the normal process of tooth. There are various terminology in literature to define impaction including delayed eruption, primary retention, submerged teeth, impacted teeth etc. A canine is considered as being impacted if it is interrupted after complete root development or the contralateral tooth is erupted for at least 6 months with complete root formation [1].

Impaction of maxillary canines is a frequently encountered clinical problem. The cause of canine impaction can be the result of localized, systemic or genetic factor(s). There are a number of possible sequelae to canine impactions. The diagnosis and localization of the impacted canines is the most important step in the management of impacted canines based on clinical and radiographic examinations. Treatment of impacted maxillary canines usually requires an interdisciplinary approach. Treatment options include no treatment, interseptive approach, extraction, autotransplantation and surgical exposure and orthodontic alignment of the impacted canine. The most desirable treatment approach is early diagnosis and interception of potential impaction. However, in the absence of prevention, surgical exposure and orthodontic alignment should be considered. Surgical treatment techniques and orthodontic considerations depend on the location of the impacted canine in the dental arch.

2. Incidence of impacted canines

Maxillary canines are the second-most frequently impacted teeth after the third molars [2] with prevalence from 0.8-5.2 % depending on the population examined [3,4]. The incidence of maxillary canine impaction is about 20 times more than mandibular canine impaction [5].

Approximately one third of impacted maxillary canines are positioned labially or within the alveolus, and two thirds are located palatally [6]. In another study [7], Ericson and Kuroil reported that, 50% of the 156 ectopically positioned canines were in a palatal or distopalatal position, 39% in a buccal or distobuccal position, and 11% apical to the adjacent incisor or between the roots of the central and lateral incisors. Maxillary canine impactions occur twice as often in females than in males [8] and only 8% of canine impactions are bilateral [9].

3. Developmental considerations

Maxillary canines develop lateral to the priform fossa and have a longer and difficult path of eruption than any other tooth through they reach their final position in occlusion. Coulter and Richardson [10] stated that in three planes of space, maxillary canines travel almost 22 mm from their position at the age of 5 years to their position at 15 years. At the age of 3 maxillary canine is high in the maxilla, with its crown directed mesially and lingually. At the age of 8 it angulates medially with its crown lying distal and slightly buccal to the lateral incisor [11]. Also at this stage the canine normally migrates buccally from a position lingual to the root apex of its deciduous precursor, however, if it cannot make this transition from the palatal to the buccal side, it remains palatally impacted [12]. Maxillary canines follow a mesial path until it reaches the distal aspect of the lateral incisor root and gradually uprights to a more vertical position by moving towards the occlusal plane guided by the lateral incisor root. However, maxillary canines often erupt into the oral cavity with a marked mesial inclination [13]. If the lateral incisors are congenitally missing, the canine may erupt in a mesial direction until it comes into contact with the distal aspect of the central incisor root and erupts into the lateral incisor space [14]. Consequently, the roots of the lateral incisors play an important role in the guidance of upper permanent canines [15].

Table 1 shows the calcification and eruption timing of the maxillary canines according to Brand and Isselhard [16].

Calcification begins	4 months
Enamel complete	6-7 years
Eruption	11-12 years
Root completed	13-15 years

Table 1. Calcification and eruption timing of the maxillary canines

The mean eruption age for the maxillary canine is approximately 1 year earlier in females (10.98 years) than in males (11.69 years) [17]. Hurme [17] suggested that if maxillary canine has not appeared by the age of 13.1 in males or by 12.3 in females, the eruption may be considered late.

4. Etiology of impacted canines

Eruption is a tightly coordinated process, regulated by a series of signaling effects between the dental follicle and the osteoblast and osteoclast cells found in the alveolar bone [18]. A wide variety of localized, systemic and genetic reasons may cause disruption in eruption process, ranging from delayed eruption to a complete failure of eruption [19]. Systemic reasons include endocrine deficiencies, febrile diseases, and irradiation. There is not only one etiology to explain the occurrence of a majority of impactions or either the localization of impaction occurring labially or palatally [20]. Environmental factors may cause impaction during the long, tortuous eruption path of a canine. The primary causes of impacted canines are localized conditions and result of one or a combination of following factors [21]:

1. tooth size, arch length discrepancies,
2. prolonged retention or early loss of the deciduous canine,
3. apical periodontitis of deciduous teeth [22],
4. abnormal position of the tooth bud,
5. presence of an alveolar cleft,
6. ankylosis,
7. premature root closure [23],
8. cystic or neoplastic formation,
9. dilaceration of the root,
10. disturbances in tooth eruption sequence,
11. mucosal barriers-scar tissue: trauma/surgery [24],
12. gingival fibromatosis/ gingival hyperplasia [25],
13. supernumerary teeth [26],
14. iatrogenic,
15. idiopathic including primary failure of eruption [27].

If no physical barrier can be identified, the cessation of eruption of a normally placed and developed tooth germ before emergence is described as primary retention [28]. Generally genetic etiology is related with primary retention [29]. If the teeth becomes impacted due to an obstruction of the eruption pathway such as crowded dental arch, it is defined as secondary retention [28].

The etiology of impacted teeth may depend upon the location of impacted tooth. The exact etiology of palatally displaced maxillary canines is unknown yet hypothesized to be both multifactorial and genetic in origin [30]. Where as buccal canine impaction is result of ectopic

migration of the canine crown over the root of the lateral incisor due to crowding or shifting of the maxillary dental midline, causing insufficient space for the canine to erupt [31].

Two main theories have been associated with the occurrence of palatally impacted maxillary canines: the “guidance theory” and the “genetic theory” [2]. According to the guidance theory, the presence of the lateral incisor root with right length and formed at the right time are important variables needed to guide the mesially erupting canine in a more favorable distal and incisal direction. If excessive space exists due to malformed or absent lateral incisor the canine would cross back from the buccal to the palatal side behind the buds of the other teeth [3]. In the clinical observation of Jacoby [32], he stated that 85% of the 40 palatally impacted canines had sufficient space for eruption in the dental arch. He claimed that labially impacted maxillary canine could only be due to arch length deficiency where as palatal impaction due to excessive space in the canine area. In accordance, Al-Nimri and Gharaibeh [33] stated that the presence of an excess palatal width and anomalous lateral incisor may contribute to the etiology of palatal canine impaction. They have also found that palatal canine impaction occurred most frequently in subjects with a Class II division 2 malocclusion. Conversely, McConnell [34] found transverse maxillary deficiency in palatally impacted canine cases. On the other hand, Langberg and Peck [35] observed no statistically significant difference in the anterior and posterior maxillary arch widths between subjects with palatally displaced canines and a comparison sample.

The genetic theory assigns genetic factors as the primary origin of the eruption anomaly of maxillary permanent canines. Palatally impacted canines, such as familial and bilateral occurrence, sex differences, are genetically associated with dental anomalies such as ectopic eruption of first molars, infraocclusion of primary molars, aplasia of premolars and one third molar [36]. Sacerdoti and Baccetti [38] showed that unilateral palatal canine displacement was associated with missing upper lateral incisors where as bilateral canine displacement with agenesis of third molars, indicating the genetic etiology of palatal canine displacement. Peck et al., [37] also found a positive correlation between palatally displaced canines and third molar agenesis.

5. Sequelae of canine impaction

Careful observation of the development and eruption of canines during periodic dental examination of the growing child is essential to prevent potential complications. Shafer et al. [39] suggested the following sequelae for canine impaction:

1. labial or lingual malpositioning of the impacted tooth,
2. migration of the neighboring teeth and loss of arch length,
3. internal resorption,
4. dentigerous cyst formation,
5. external root resorption of the impacted tooth, as well as the neighboring teeth,

6. infection particularly with partial eruption, and
7. referred pain and combinations of the above sequelae.

6. Diagnosis of impacted canines

The diagnosis and localization of the impacted canines is the most important step in the management of impacted canines based on clinical and radiographic examinations.

6.1. Clinical evaluation

In clinical evaluation firstly patient's age and dentition should be examined to determine whether there is a delayed eruption or not. Secondly, the presence or absence of a factor such as certain diseases that may cause tooth structure, size, shape, and color defects adversely affecting tooth development should be searched [40]. Subsequently the amount of space in the arch for the unerupted canine, the morphology and position of the adjacent teeth, the contours of the bone, the mobility of teeth should be considered through clinical evaluation [41].

Indicative clinical signs of canine impaction may be listed as following: [20]

1. delayed eruption of the permanent canine or prolonged retention of the deciduous canine beyond 14 to 15 years of age,
2. the presence of an asymmetry in the canine bulge or absence of a normal labial canine bulge observed during alveolar palpation,
3. presence of a palatal bulge, and
4. distal tipping, or migration of the lateral incisor

During normal eruption of the maxillary canine, usually a labial bulge is noted on the mucosa superior to the maxillary primary canine. When such a bulge is not visible, an intraoral palpation is required to provide a clear localization of the permanent canine. Also mobility of all present teeth should be assessed during palpation. Mobile deciduous canines may indicate normal resorption of the roots by the permanent canines whereas mobility of the permanent lateral incisor may be the potential result of root resorption by the impacted canine [20].

According to Ericson and Kurol [42] the absence of the "canine bulge" at earlier ages should not be considered as indicative of canine impaction. In their evaluation of 505 schoolchildren between 8 and 12 years of age, they found that at 10 years, 29% of the children had nonpalpable canines, but only 5% at 11 years of age, whereas at later ages only 3% had nonpalpable canines. They found that many of the children under 10 years of age whose canines initially were determined by palpation to be potentially abnormal, actually later developed and erupted normally. Thus they found radiographic examination impractical and unnecessary for children under 10 years of age [43].

In contrast, examination of intrabony movement of the canines between the dental age of 8 to 10 years was advised by Williams [44]. If permanent canine bulges are not palpable, he offered

to examine lateral and frontal radiographs specifically for Class I malocclusions, even with minimal arch length loss. He suggested removing the deciduous canine when a position apparently lingual to the anterior teeth on the lateral radiograph and a medial tilt of the long axis of the canine in relation to the lateral wall of the nasal cavity on the frontal radiograph are observed.

6.2. Radiographic verification

The accurate location of impacted canines and determining their relationship to adjacent incisors and anatomical structures is the part of the diagnostic process and is essential for successful treatment. This required information can be partially obtained from conventional two-dimensional radiographs as the first step which includes periapical radiographs, occlusal films, panoramic views, and lateral cephalograms [45].

In most cases analysis should begin with routine periapical films. A single periapical film would relate the canine with the neighboring teeth both mesiodistally and superoinferiorly. In order to estimate the buccolingual position of the canine, a second periapical film is obtained by using [46]: (1) Tube-shift technique or Clark's rule, (2) buccal-object rule.

In tube-shift technique two adjacent periapical radiographs of the impacted tooth are taken at slightly different horizontal angles. The object that moves in the same direction as the cone, is palatally impacted. If the impacted canine is located buccally, the crown of the tooth moves in the opposite direction as the x-ray beam. Consequently the object closest to the film will move in the same direction as the tube head.

In the buccal-object rule two periapical films are taken of the same area, with approximately 20° vertical angulation of the cone changed when the second film is taken. The buccal object will move in opposite direction to the source of radiation.

Occlusal films also aid to detect the buccolingual position of the impacted canine in conjunction with the periapical films especially when treating an uncooperative child, a child with very small oral aperture. However, alone, this type of radiograph provides no information relative to the vertical position of the impacted tooth [47].

Frontal and lateral cephalograms can sometimes be useful in determining the position of the impacted canine, particularly its relationship to other facial structures, such as the maxillary sinus and the floor of the nose.

Panoramic radiography has also been utilized as a diagnostic tool for determination of unerupted canine positions [48]. Radiographic variables on panoramic x-rays: α -angle (angle measured between the long axis of the impacted canine and the midline), d-distance (distance between the canine cusp tip and the occlusal plane), and s-sector where the cusp of the impacted canine is located (sector 1, between the midline and the axis of the central incisor; sector 2, between the axes of the central incisor and the lateral incisor; or sector 3, between the axes of the lateral incisor and the first premolar) have been shown to be predictive factors for prediction of eventual impaction, the durations of orthodontic traction and comprehensive orthodontic treatment to reposition the impacted tooth. However these features are not valid

predictors of the final periodontal status of orthodontically-repositioned impacted canines [49]. The more severely displaced the canine with regard to the adjacent maxillary incisors, the longer the orthodontic treatment.

Medical computerized tomography (CT) was an improvement which overcomes the limitations of conventional two-dimensional (2D) imaging however, radiation exposure of CT scans limits its clinical utility [50]. The advent of 3D cone beam computed tomography (CBCT) has reduced the radiation dose, making it an advantageous tool in dentistry [51]. CBCT images have been proven to be useful for the accurate diagnosis of the impacted canines, treatment planning and the identification of associated complications, such as root resorption in adjacent incisors. In addition it was found that CBCT reduces the treatment duration and increases the success of treatment in difficult cases to a similar level of simpler cases [52]. Small volume CBCT may be indicated as a supplement to a routine panoramic X-ray in the following cases if: [53]

- canine inclination in the panoramic X-ray exceeds 30°
- root resorption of adjacent teeth is suspected
- the canine apex is not clearly discernible in the panoramic X-ray, implying dilaceration of the canine root.

6.3. Root resorption and radiographic evaluation

The ability to evaluate the condition of the lateral incisor root is of great importance to the clinician because 80% of the teeth resorbed by the ectopically erupting canines were found to be lateral incisors [21]. Lateral incisor image could only be evaluated in 37% of the cases with the use of periapical films [47]. However CBCT provides more detailed information about the location and extent of the resorbed roots and may notably alter the prevalence of root resorption [54].

Ericson and Kuroi [7] found the incidence of lateral resorption as 38%, in a study of 156 ectopically impacted maxillary canines with using CT. In a more recent study, Oberoi and Knueppel [55] determined no root resorption in 40.4%, slight root resorption in 35.7%, moderate resorption in 14.2% and severe root resorption in 4% of the adjacent lateral incisor evaluated by CBCT.

7. Treatment planning considerations

Maxillary canines play an important role in creating good facial and smile esthetics, since they are positioned at the corners of the dental arch, forming the canine eminence for support of the alar base and the upper lip. Moreover, when the maxillary canines are properly aligned and have good shape and size, pleasing anterior dental proportions and correct smile lines are achieved. Functionally, they support the dentition, contributing to disarticulation during lateral movements in certain persons [56]. Treatment of impacted maxillary canines usually

requires an interdisciplinary approach involving oral surgical, restorative, periodontic as well as orthodontic components. Prudent treatment planning is necessary to achieve the various treatment goals [21].

The patient with an impacted maxillary canine initially must undergo a comprehensive clinical and radiographic evaluation of the malocclusion to localize the impacted canine and decide on its prognosis for alignment. Patient's cooperation, age, general oral health, skeletal variation and presence of spacing or crowding in the arch are important agents affecting prognosis [57]. Any root resorption of the adjacent teeth should also be considered. Orthodontist should also be aware of the normal development and eruption pattern in order to conduct interceptive treatment if appropriate, which provides cost benefit than other more invasive procedures. Patient and parent counselling on the treatment options and informed consent is essential to avoid any medicolegal problems [58].

8. Treatment options

The clinician should consider the various treatment options available for the patient, including: [21]

1. No treatment
2. Interceptive treatment
3. Extraction of the impacted canine
4. Autotransplantation of the canine
5. Surgical exposure and orthodontic alignment

1. No treatment

No active treatment could be recommended when: [59]

- the patient does not request treatment
- there is no sign of resorption of adjacent teeth or other pathology
- there is a severely displaced canine with no evidence of pathology, if it is remote from the dentition ideally there is a good contact between lateral incisor and first premolar or good esthetics/prognosis for deciduous canine

In this instance, the unerupted canine should be periodically monitored with respect to cystic degeneration, root resorption and the other possible complications. The optimal time interval between radiographs is not known to reduce the radiation dosage. In most cases, long-term prognosis of retained deciduous canine is poor, regardless of its root length and crown shape since the root of retained deciduous canine will eventually resorb and it will have to be extracted [21].

2. Interceptive treatment

Early diagnosis and intervention is very important for it could save the time, expense, and more complex treatment in the permanent dentition. If early signs of ectopic eruption of the canines is determined, the clinician should made an attempt to prevent their impaction and its potential sequelae. Frequently, primary canines are extracted as an interceptive measure to facilitate the permanent canine eruption or at least provide changes to a more favorable position [12]. The extraction of the primary canine is recommended when:

- the patient is aged 10-13 years.
- the maxillary canine is not palpable in its normal position and radiographic examination exhibits palatal canine ectopia. If the permanent canine is located in a more medial position or the patient is older than the ideal age group, extraction of the primary canine may provide less favourable results [60].

Clinical re-evaluation and follow-up radiographs should normally be taken at 6-month intervals. If there is no improvement in canine position within 12 months on panoramic films after the extraction of primary canines, an alternative treatment is indicated [61].

The severity of the angulation of the impacted canine is an important factor in the prognosis. The more inclined the tooth is, the less is the probability that it will spontaneously erupt [61]. Power and Short [62] predicted the chances of canine impaction based on orthopantomographs between the years of 10-13 and claimed that eruption chance of the impacted tooth will decrease even after deciduous extraction is performed if the permanent canine is angled more than 31° to the midline.

Ericson and Kurol [61] stated that the removal of the deciduous canine before 11 years of age will normalize the position of the ectopically erupting permanent canines up to 91% if the permanent canine crown is distal to the midline of the lateral incisor. However the success rate decreases to 64% when the canine crown overlaps medially to the long axis midline of the lateral incisor.

Williams [44] suggested the extraction of the maxillary deciduous canine as early as 8 or 9 years of age to enhance the eruption and self-correction of a labial or intra-alveolar maxillary canine impaction in Class I uncrowded cases.

Extraction of deciduous canines in conjunction with the use of cervical pull headgear, and rapid maxillary expansion have been reported to be effective procedures in the interceptive treatment of maxillary canine impaction [2]. Baccetti et al. [63] found that 65 percent of palatally displaced cases that underwent the removal of the deciduous canine resulted in successful eruption of permanent canines without any other treatment. The prevalence rate could be improved significantly up to 88 percent by preventing mesial migration of the upper posterior teeth after extraction of the deciduous canine, such as with the use of cervical-pull headgear [63]. Also Olive [64] stated that opening space for the canine crown with routine orthodontic mechanics might allow for spontaneous eruption of an impacted canine. However early correction of the flared and distally tipped lateral incisors is not recommended in order not to cause impaction of the canines or the resorption of lateral incisor roots [65].

Another randomized clinical trial performed by Bagetti et al. [66] reported that TPA and deciduous canine extraction alone was as effective as rapid maxillary expansion followed by a TPA coupled with the extraction of deciduous canines, as an interceptive treatment option for patients from 9 years 5 months to 13 years of age with palatally displaced canines. The use of these protocols in late mixed dentition subjects increased the eruption rate significantly more than only extraction and untreated groups.

3. Extraction of impacted canines

The surgical removal of impacted canines although seldom considered might be a viable option in the following situations: [29]

- patient declines active treatment and/or is happy with appearance.
- there is evidence of early resorption of adjacent teeth.
- the patient is too old for interseption.
- there is a good contact for lateral incisor and first premolar or the patient is willing to undergo orthodontic treatment to substitute first premolar for the canine
- if the impacted canine is ankylosed and cannot be transplanted
- if the root of impacted canine is severely dilacerated
- if the impaction is severe and the degree of malocclusion is too great for surgical repositioning/transplantation.

Especially extraction of the labially erupting and crowded canine is contraindicated. Such an extraction might temporarily improve the aesthetics however may complicate and compromise the orthodontic treatment results.

If removal of the impacted canine is required, the orthodontist should decide whether to replace the premolar into the canine position or restore the missing canine space with a prosthesis or an implant. If the canine space is going to be closed orthodontically, the posterior segment has to be protracted. Before the extraction decision is made, factors such as lingual cusp interferences, tooth size discrepancy, and the difficulties encountered when employing unilateral mechanics should also be considered [21].

When an extraction is performed, it often leaves a critical alveolar defect of difficult management. Puricelli et al. [67] recommended maxillary partial osteotomy as an efficient resolution for the correction of bone defects within the dental arches which is performed by mobilizing an alveolar bone segment. They have indicated this technique within the concept of individual and multiple sustenance of integrity in occlusion and of the dental arches, especially in young patients, where the indication for fixed prosthetics or osseointegrated implants might be precocious. They stated that this technique offers a superior time efficient solution for the loss of the maxillary canines compared to the osseointegrated implant rehabilitation or orthodontic space closure.

Surgical extraction of impacted canines and their substitution by first premolars eliminates all the risks and uncertainty related to orthodontic extrusion of an impacted canine. Good

functional and esthetic results can be achieved, if an accurate and detailed anterior tooth position is managed during orthodontic finishing [68]. Smile esthetics of maxillary premolar substitution can be improved by intruding the first premolars to a higher gingival margin with respect to the maxillary lateral incisors and restoring the premolars with composite resin buildups or porcelain veneers to produce natural canines [69]. Otherwise slightly extrusion of the maxillary first premolars is also acceptable if premolar crowns are long, with prominent buccal cusps. Also, slight negative crown torque and a mesiopalatal rotation is recommended to resemble a natural canine as possible [68]. Additionally it is reported that there is no scientific evidence that one occlusal scheme is better than the other. Hence canine guidance can well be constructed by premolar guidance or a group function, by slightly extruding the maxillary first premolar [70].

4. Autotransplantation of the canine

Autotransplantation could be performed as a treatment option when: [59]

- interceptive treatment is inconvenient or has failed,
- the degree of malocclusion is too severe to achieve orthodontic alignment, (crown tip mesial to the mid-line of the lateral incisor or mesial angulation greater than 55° [47],
- adequate space is available for the canine
- the prognosis is good for the tooth to be transplanted and it can be removed atraumatically.
- patient refuses a conventional orthodontic therapy
- failure of orthodontic alignment due to immobility

Successful prognosis of transplanted teeth depends on the following factors: the condition of the remaining periodontal ligament attached to the extracted donor tooth [72], the adaptation of the donor tooth to the socket [73], the duration and the method of splinting after transplantation [74], and the timing of endodontic treatment of the transplanted teeth [75].

Recent studies of autotransplantation of canines have reported success rates of 38–58% over more than 10 years [76, 77]. In another recent study, Huth et al. [71] found that the success rate of autotransplanted teeth was 74%, along with a high patient satisfaction [37]. They recommended autotransplantation especially in adolescent patients in whom alternative treatments, such as dental implants, are not yet indicated since autotransplanted teeth increase or at least maintain the bone level and facilitate a later dental implant supply.

The most relevant complications in autotransplantation of teeth that affect the success rate are inflammatory or replacement resorption [78]. Periodontal healing is responsible for root resorption after autotransplantation. At a later stage of development the root is fully formed and the chances of pulpal and periodontal healing is reduced [79, 80]. The optimal developmental stage for autotransplantation is when the root is 50-75 percent is formed [81].

In some clinical studies it was suggested that the preapplication of mechanical stimuli to the donor teeth might stimulate the periodontal ligament, prevent ankylosis, reduce the damage to the periodontal ligament, and prevent root resorption after replantation [82,83]. Recently,

Ru and Bai [84] reported a maxillary canine autotransplantation case where the extraction site of deciduous canine was preserved with a titanium prosthesis and a bioresorbable membrane to prevent root resorption and ankylosis.

The prognosis of ectopic canine autotransplantation in adults is poor. In the research of Schatz and Joho [85] on 20 transplanted maxillary canines, they determined that pulp vitality remained in 80% of the patients aged 13 to 20 years group however all impacted canines required root canal therapy in the 20-to 48-year age-group.

Endodontic treatment of autotransplanted teeth with closed apices is considered as mandatory analog of traumatically avulsed teeth with closed apices [86]. If the tooth has an open apex, a wait-and-see strategy is accepted due to the considerable potential of revascularization [87], which occurs in up to 100% of these teeth [81]. In such a case, endodontic treatment is performed only if signs of pulp necrosis or root resorption are detected [87]. On the other hand, some authors suggested a wait-and-see strategy even in cases with closed apices [88, 89]. In the study by Ahlberg et al. [89], 30% of 33 maxillary canines with complete root formation required no endodontic treatment after an average of 6 years. (Figure 1)

5. Surgical exposure of teeth and orthodontic treatment

The most desirable treatment approach for the management of impacted maxillary canines is early diagnosis and interception of potential impaction. However, in the absence of prevention, clinicians should consider surgical exposure and orthodontic alignment.

This treatment option is recommended when: [59]

- a. the patient tends to wear orthodontic appliances
- b. the patient is well motivated and has general good dental health
- c. the long axis of the ectopic canine is not too horizontal or oblique. The closer the crown is to the midline and the root to the mid-palatal suture, the poorer prognosis for alignment [60]
- d. any evidence of root resorption or other pathology is such that it is more desirable to preserve the canine. For instance if the adjacent lateral incisor is resorbed and have a very poor prognosis, it would be advantageous to attempt alignment of impacted canine to replace the lateral incisor [59].

Two approaches could be followed after surgical exposure: [21]

1. surgical exposure to allow for natural eruption to occur
2. surgical exposure with the placement of an auxiliary

8.1. Surgical exposure to allow for natural eruption to occur

This method is often used when:

- the canine has an appropriate axial inclination and does not need to be uprighted during its eruption,

- the root development has not been completed yet, therefore patient's age is important

The progress of canine eruption should be monitored with roentgenograms, using reference points such as an adjacent tooth or the arch wire. If the tooth fails to erupt, removal of any cicatricial tissue surrounding the crown is recommended. The main disadvantages of this approach are the spontaneous but slow canine eruption, the increased treatment time, and the inability to influence the path of eruption and the risk of ankylosing [21].

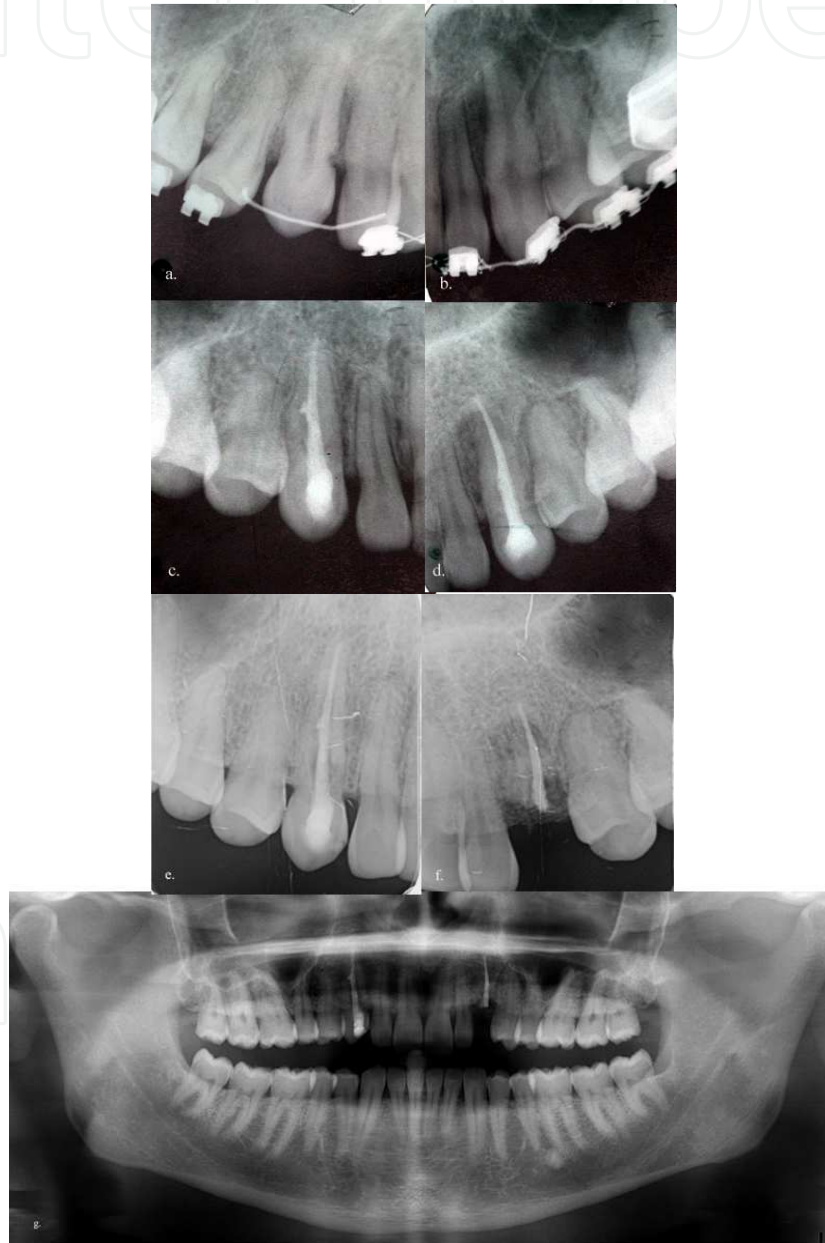

Figure 1. Bilateral impacted canines were treated with autotransplantation in a 22 year old adult patient. A wait and see strategy was followed and canal therapy was applied after seven months from autotransplantation as external root resorption was detected. 10 years after treatment the patient came with the left canine broken due to external root resorption, however no difference was observed in the contralateral canine.

8.2. Surgical exposure with the placement of an auxiliary

Surgically assisted orthodontic guidance is required when all possibilities of its natural eruption have been failed. It is preferred to be performed at least 6 months after root apex completion [10]. The duration of this orthodontic treatment varies from 12–36 months depending on a number of factors including the patient's age, crowding, the angulation and bucco-palatal position of the tooth, its distance from the occlusal plane and the periodontal health [8]. If the inclination of the canine is greater than 45 degrees in relation to the midline then the prognosis for alignment worsens. The further the canine needs to be moved then the poorer the diagnosis for a successful outcome. Either the tooth should not be anyklosed or the root not be dilaserated [60]. Correct root positioning and a good buccal overlap is necessary for a stable result [90]. The prognosis is worse in older patients than in young patients, thus early diagnosis is essential [42]. The upper age limits suggested for successful alignment of an unerupted canine are 16 and 20 years [57]. In contrast Nieri et al. [8] found the position of the impacted canines closer to the physiologic position of the dental arch in older subjects which affected the treatment duration positively.

Combined forced eruption treatment approach is performed at three phases [8].

- surgical exposure of the impacted tooth
- placement of an attachment to the tooth
- application of orthodontic mechanics to align the impacted teeth

Mostly two approaches are recommended in regards to the timing of attachment placement: [21]

1. The first method is a two-step approach. Firstly the canine is surgically uncovered and the area is packed with a surgical dressing in order to avoid filling in of tissues around the tooth. After wound healing within 3-8 weeks, the pack is removed, then an attachment is bonded on the impacted tooth [91]. This approach is preferred when bleeding compromises attachment bonding [92].
2. The second method is a one-step approach, in which, the attachment is placed on the tooth at the time of surgical exposure. This method is especially recommended for palatally impacted teeth which aids the clinician to visualize and better control the direction of tooth movement when traction force is applied.

8.3. Surgical exposure of the impacted tooth

During surgical exposure of an impacted tooth, only enough bone should be removed for the placement of a bonded bracket [21]. Excision of tissues must be carefully performed and the cemento-enamel junction (CEJ) should not be intentionally exposed. If done incorrectly, the unerupted tooth may be left with inadequate keratinized tissue. Therefore the use of electro-surgical or laser techniques is contraindicated for surgical exposure. These instruments are designed for removal of hard and soft tissues, the contact of the instrument to the tooth may lead to permanent damage of either type of tissue and/or devitalization of the tooth [20].

Main indicator of the treatment success of impacted maxillary canines is related with the final periodontal outcome [49]. In earlier methods, radical bone was removed during surgical exposure and all bony obstacles were removed to provide an easier path for tooth eruption. Literature shows that the most serious periodontal damage is loss of supporting bone which is associated with more heavy surgical procedures involving exposure of the tooth underneath the cemento-enamel junction (CEJ) [93]. Therefore exposure of the CEJ was a critical variable and special attention has to be given during surgery or when placing a wire lasso with or without a gold chain.

Classification and treatment techniques will be presented in detail according to the position of impacted maxillary canines:

8.4. Palatal versus labial impactions

The incidence rate of palatal impaction is at least 3:1 [94] and up to 6:1 when compared to labial impaction [95]. Labial impactions generally have a more favorable vertical angulation whereas palatally impacted canines are more often inclined in a horizontal/oblique direction [21]. Jacoby [32] determined that 85% of palatally impacted canines had enough space in the dental arch whereas only 17% of the labially unerupted maxillary canines appeared to have sufficient space for eruption. Consequently he claimed arch length deficiency as a primary causative factor for labially impacted canines.

Ectopic labially positioned canines may erupt frequently high in the sulcus or alveolar ridge on their own without either surgical exposure or orthodontic treatment. Contrarily, palatally impacted canines seldom erupt without intervention due to the thickness of the palatal cortical bone and also the dense, thick, and resistant palatal mucosa [21].

8.5. Management of labially impacted canines

Labially impacted maxillary canine is often positioned high in the alveolar bone and erupts through the alveolar mucosa. It has been emphasized that labially impacted canines are more challenging to manage without the occurrence of adverse periodontal problems. Therefore, special attention has to be given to surgical technique, marginal gingival placement, control of inflammation, magnitude of force, atraumatic surgery, and proper gingival attachment [96].

Generally 3 techniques are used for uncovering a labially impacted maxillary canine [31]:

- i.** excisional uncovering (gingivectomy)
- ii.** apically positioned flap
- iii.** closed eruption techniques

The orthodontist should guide the surgeon properly to select an appropriate technique. If the correct uncovering technique is chosen, the eruption process can be simplified, resulting in a predictably stable and esthetic result. Four criteria should be evaluated by the orthodontist in order to determine the appropriate method for uncovering the tooth before referring a patient for surgical exposure. First, the labiolingual position of the impacted canine crown should be

determined. If the tooth is impacted labially, then any of the 3 techniques could be performed, since there is usually little or any bone covering the crown of the impacted canine. However, if the tooth is impacted in the center of the alveolus, an excisional approach and an apically positioned flap are usually more difficult to perform, for large amount of bone removal might be required from the labial surface of the crown.

The second criterion to evaluate is the vertical position of the tooth relative to the mucogingival junction. Any of the 3 techniques can be chosen to uncover the tooth, if most of the canine crown is positioned coronal to the mucogingival junction. (Figure 2)

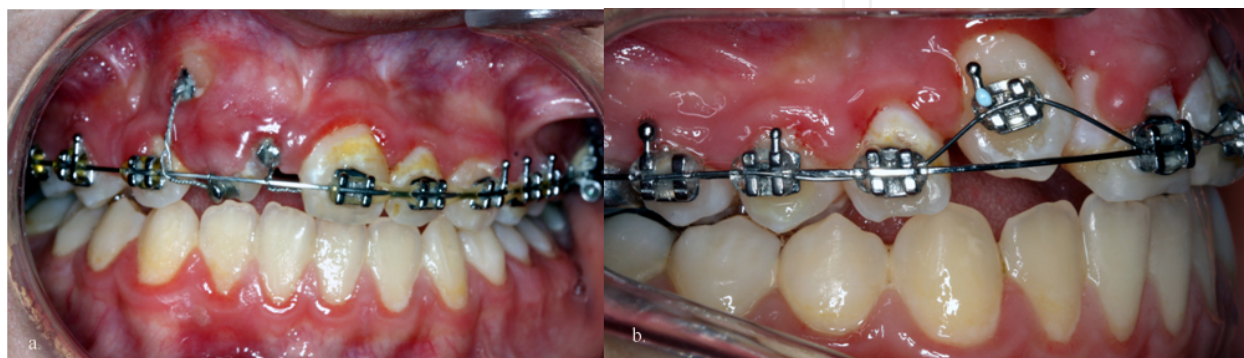


Figure 2. Closed flap technique was performed for the maxillary canine to erupt and orthodontic traction was applied to align the canine into the lateral position.

When the canine crown is positioned apical to the mucogingival junction, the most appropriate approach is the closed eruption technique for it would provide adequate gingiva over the crown and prevent reintrusion of the tooth in the long term [97]. Excisional technique would be inappropriate, because it would result in no gingiva over the labial surface of the tooth after eruption has completed. An apically positioned flap would either be inappropriate since it would cause possible reintrusion and instability of the crown of the tooth after orthodontic treatment [98].

The third criterion to evaluate is the amount of attached gingiva in the area of the impacted canine. The creation and preservation of the band of attached gingiva is very critical for periodontal health in the management of labially impacted teeth [12]. The only technique that predictably would produce more gingiva is an apically positioned flap, if there were insufficient gingiva in the area of the canine. Otherwise, mucogingival recession and alveolar bone loss may occur. Any of the 3 techniques could be selected, if there were sufficient gingiva to provide at least 2 to 3 mm of attached gingiva over the canine crown after it had been erupted [31].

The final criterion to evaluate is the mesiodistal position of the canine crown. An apically positioned flap should be preferred if the crown were positioned mesially and over the root of the lateral incisor, since it could be difficult to move the tooth through the alveolus unless it was completely exposed. In this situation, closed eruption or excisional uncovering generally would not be recommended [31].

There are conflicting reports in the literature regarding apically positioned flap technique and closed eruption technique [64,98-100]. Unfortunately, some reports and studies have failed to differentiate that the “open” technique is different from an apically positioned flap approach [96]. There is conclusive evidence that an open eruption approach through nonkeratinized gingival should be avoided [98]. The absence of an adequate band of attached gingiva around the erupting canine may cause inflammation of the periodontium. Vanarsdall and Corn [99] emphasized that it is risky to move teeth in the presence of inflammation. In addition Caprioglio et al. [101] stated that it is necessary to use conservative surgical techniques and orthodontic systems mimicking the natural pattern of eruption in order to achieve adequate periodontal status.

An apically repositioned flap or closed eruption techniques through keratinized gingival tissue are recommended [102]. If the tissue is too thin to be dissected as a partial thickness graft, laterally repositioned pedicle graft, a free gingival graft can be performed initially to increase the thickness of keratinized gingiva. After approximately 30 to 60 days or complete healing of the grafted tissue, the tooth may be exposed, bonded, and orthodontic traction might be applied.

Vernette et al. [98] compared the esthetic and periodontal results between the apically repositioned flap and the closed eruption techniques of surgically uncovering labially impacted maxillary teeth (incisors and canines). They have concluded that periodontal attachment differences between uncovered and contralateral teeth were not clinically significant in either the apically positioned flap or closed-eruption groups. However labially impacted maxillary anterior teeth uncovered with an apically positioned flap technique have more unesthetic sequelae than those with closed-eruption technique. Also adverse effects were detected treated with apically positioned flap technique such as increased clinical crown length, width of attached tissue, gingival scarring, and intrusive relapse since the mucosal attachment tends to pull the crown of the tooth apically.

However in literature the disadvantages of closed eruption technique were reported as increase in treatment time, additional surgical procedures, diminished control of tooth movement, as well as adverse periodontal responses [21,96]. Advantages of the apically positioned graft are that it is minimally invasive, provides controlled tooth movement (even high in the vestibular depth), prevents cystic follicles, decreases treatment time. Also it prevents ankylosis if bonding is delayed for 1 week [96]. It was reported that only 4 to 5 months was enough to erupt labially impacted teeth into the arch with apically positioned grafts even in severe cases [103].

In the review article of Vanarshdal [96] it was concluded that adverse responses have not been determined with labially uncovered teeth with grafts that have been left open and activated a week later. Surgical exposure with careful attention to the periodontal tissues and proper orthodontic alignment without intentional closing over with soft tissue could provide a more predictable result for patients. It was also emphasized that the pedicle graft is necessary on the labial of the maxilla. The gingivally repositioned procedure as described earlier [99] didn't create a compromised periodontal outcome, and treated teeth were indistinguishable from

untreated sides Vanarshdal [96] stated that closed eruption technique was not superior to apically repositioned flap technique as a result of this evidence based data.

Apart from these common used three techniques explained above, the application of tunnel technique might be indicated in the following situations: [8]

- i. if persistent deciduous canines exists with impacted canines or space available in the dental arch and
- ii. feasibility of direct traction of the impacted canine to the center of the alveolar ridge as assessed on the diagnostic radiographic records to reproduce the physiologic eruption pattern of the canine.

8.6. Management of the palatally impacted canines

The most common impaction encountered by orthodontists is the palatal impaction of maxillary canines (95-Stellzig et al., 1994). With palatal impactions it is critical to recognize that the entire palate is covered with specialized mucosa and a graft is not necessary [104]. The most commonly used surgical methods for exposing the impacted canine are: [59]

1. open surgical exposure and allowing for natural eruption
2. open surgical exposure and packing with subsequent bonding of an auxiliary
3. closed surgical exposure with the placement of an auxiliary attachment intraoperatively.

The first method is most appropriate if the canine has the correct inclination and will then erupt spontaneously. Schmidt [105] suggested to uncover palatally impacted canines early, during the mixed dentition in order to encourage autonomous eruption, without orthodontic intervention. They have reported that the overall treatment time is reduced with superior periodontal and aesthetic results since the bone levels and attachment levels improved on the canine and lateral incisor and also little to no root resorption occurred on the lateral incisors.

Kokich and Mathews [100] also recommended earlier timing for uncovering palatally impacted canines before starting orthodontic treatment. In some cases, surgical exposure could be performed during the late mixed dentition. First a full-thickness mucoperiosteal flap is elevated, then all bone over the crown is removed down to the cemento-enamel junction. Following the flap is returned, and a hole is made through the gingival flap. If the tooth is highly positioned in the palate a dressing might be placed over the exposed area in the flap. Although it has been noted that autonomous eruption occurs within 6 to 9 months postoperatively, there is currently no report in the literature to support this statement [106]. After the canines erupt to the occlusal level an attachment could be bonded for the further orthodontic treatment.

The second approach is the "open window" eruption technique in which a flap is elevated and enough amount of bone is removed to expose the tip of the impacted crown to be bonded. The flap is then repositioned and sutured with a small "window" cut into the flap of the palatal soft tissue, covering the embedded crown packed with surgical dressing. To provide a good periodontal prognosis, a special attention should be given in maintaining the attached gingiva

on the impacted tooth. One week later postoperatively the pack is removed and an attachment is bonded with subsequent traction using a fixed appliance. There is some evidence that the periodontal status may be compromised [107]. (Figure 3)

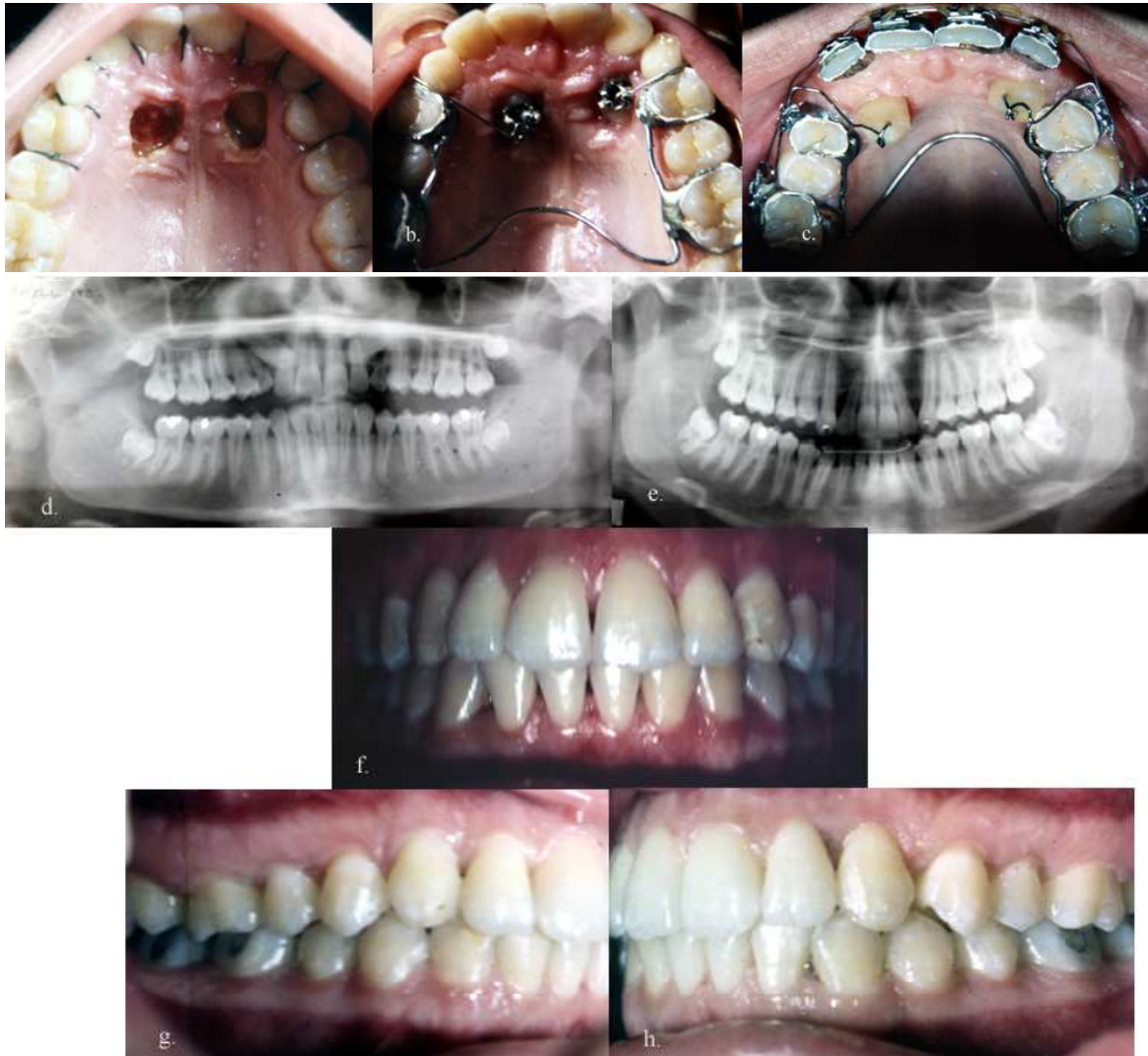

Figure 3. Bilateral palatally impacted maxillary canines were uncovered by open surgical technique, orthodontic traction was performed by ballista springs. Alignment of bilateral maxillary canines lasted 4,5 years.

The third option is the closed eruption technique. If a canine is associated with severe resorption of the root of the incisor, an open exposure is not indicated since it endangers the vitality and existence of the incisor. In such a case a closed eruption technique would provide both teeth a vital state [108]. In this technique sufficient space should be created before the surgical exposure. Usually uncovering a palatally impacted canine occurs after the first 6 to 9 months of orthodontic alignment of the maxillary dentition. In this technique firstly a mucoperiosteal flap is reflected and a minimum of bone is removed to reveal the follicle, which is opened at the most superficial point only. Bone is not cleared away from the neck of the tooth, nor more of the follicular tissue than is essential for bonding, and certainly not down to the cemento-

namel junction [109]. A small eyelet, threaded with soft twisted ligature wire of 0.012-in gauge, is then bonded while hemostasis is maintained. The flap is then sutured fully back to cover the entire wound and exposed area, with the twisted ligature wire drawn through the flap at a point strategically placed to permit traction in the direction that will have been confirmed when the orthodontist actually sees the tooth in situ. Generally, orthodontic traction begins soon after the surgery towards to the edentulous site [109].

On the other hand if not enough bone is removed then the tooth will not move and orthodontist might suspect from ankylosis. However the incidence of ankylosed maxillary canines is low [100]. In the case of insufficient bone removal over the impacted tooth, the tooth will not be able to resorb the bone over the crown efficiently for the dental follicle is deflated and removed. When a force is applied the enamel of the impacted crown comes into contact with the bone however there are no cells in the enamel to resorb the bone. Therefore resorption will eventually occur slowly through pressure necrosis [31].

Closed eruption technique is a more conservative approach however if bond failure occurs then re-exposure is required. Also direct bonding of the impacted canine during surgery may cause soft tissue injury due to the acid etching contamination. Becker et al. [108] suggested the use of an eyelet bonded in a mid-buccal position on the crown of the impacted tooth at surgery as these have the highest success rate. Becker and Chausu [109] stated that morbidity is lower in closed eruption approach than for open procedures since healing is faster, postoperative pain is considerably reduced, and postsurgical bleeding is virtually eliminated.

There is a controversy in the literature regarding the periodontal outcome of open or closed surgical exposure and subsequent orthodontic alignment of the palatally displaced canines [110]. It is believed that periodontal health is compromised when the palatal mucosa is excised with open technique [93].) However in a systematic review Parkin et al. [111] found no robust evidence to support one surgical technique over the other.

Also in recent studies [112, 113] evaluating the differences in the periodontal outcomes of palatally displaced canines (PDC) exposed with either an open or a closed surgical technique, no significant differences in post-treatment periodontal status of the canines and adjacent teeth were determined between the techniques. Both treatment methods were found acceptable for treatment of the palatally impacted canine. In addition Smailine et al., [113] 2013 concluded that post-treatment periodontal status and the level of bone support were not dependent on the patients' age at the start of treatment, the duration of treatment, or the initial horizontal and vertical localization of impacted canine.

9. Orthodontic considerations

Orthodontic treatment methodology for impacted canines depends on various factors, such as location of the impacted canine in the dental arch relative to adjacent incisors, the distance from the occlusal plane, canine crown overlaps, canine angulations, the possible presence of ankylosis, root resorption, or dilaceration [100]. Generally, horizontally impacted or ankylosed

canines are the most hazardous to manage and have the poorest prognosis [114]. Some of these teeth may need to be extracted. These variables are also used as predictors of the orthodontic treatment duration [100].

Frequently, when the palatally impacted canine is surgically uncovered, only the lingual surface of the tooth is available for bonding attachments. However Becker and coworkers [107] stated that the palatal surface as the poorest bonding surface. The orthodontic force to be applied to the bonded attachment requires careful planning because if an orthodontic force is applied from the adjacent maxillary teeth, it will tend to embed the buccal surface of the crown and may create periodontal problems. In order to prevent this problem, first the tooth should be erupted vertically and once a facial attachment can be bonded, forces should direct the tooth facially [115].

When removal of premolars is planned for the orthodontic treatment, it is advised to delay their extractions until the canine is surgically uncovered and feasibility of moving the impacted canine is insured. However, the premolar has to be removed initially prior to any attempt to move the canine in severely crowded cases. In such a case, the patient or parents should be made aware of the possible complications [21].

During closed-eruption technique, the orthodontist should select mechanics that erupt the tooth through the center of the alveolar ridge. The eruption of the tooth between the alveolar cortical plates prevents bone dehiscence and unfavorable orthodontic and esthetic consequences [49]. The mechanics that draw the tooth labially should be avoided, in order not to produce a bony dehiscence or labial recession of gingival margin [31].

The impacted tooth under orthodontic traction forces should be periodically checked for excessive mobility or bleeding from gingiva around the tooth. It is important to ensure that periodontal attachment is following the tooth as it is guided into the arch [116]. Furthermore correction of torque, labio-palatal root angulation of the impacted canine should be considered to achieve proper functional occlusion. The bracket on the labial aspect of the canine can be inverted to correct the torque or a mandibular premolar bracket can be bonded to the ectopic canine to produce a more negative torque [117].

9.1. Methods of attachment

Wire ligatures, a bracket, a hook, button or an eyelet directly may be attached to the enamel surface after the surgical exposure of the impacted tooth crown [29]. (Figure 2,3) If the canines are deeply impacted, a gold chain may be used that can pass through a long tunnel created between the impacted tooth and the empty socket of the extracted primary canine [118]. A circumferential, dead soft, ligature wire (lasso) passing around the cervical area of the tooth shouldn't be used as an attachment since too much bone removal is required. This "heavy exposure," may provoke the risk of injuring the adjacent teeth, external root resorption and ankylosis [119]. Celli et al. [120] advocated bonding of two attachments to the impacted canine instead of the classic single one for closed eruption of palatally impacted canines in order to reduce the potential risk of a second surgical operation when the traction attachment comes off.

9.2. Traction methods

Various methods have been used for moving the canine into proper alignment. These include the use of light wires (Figure 2) or springs soldered to a heavy labial or palatal base wire, mousetrap loops, K-9 spring, ballista loops (Figure 3c), Kilroy I, II springs [31, 121, 122]. Vardimon et al. [123] recommended the use of magnets to treat impacted canines on the basis of a less invasive surgical procedure, effective forces at short distances, and controlled spatial guidance. (Figure 4) With the introduction of new orthodontic materials such as elastic threads, elastometric chains, and nickeltitanium springs, the orthodontist has a wider choice of materials and also greater control of the force magnitude and direction.

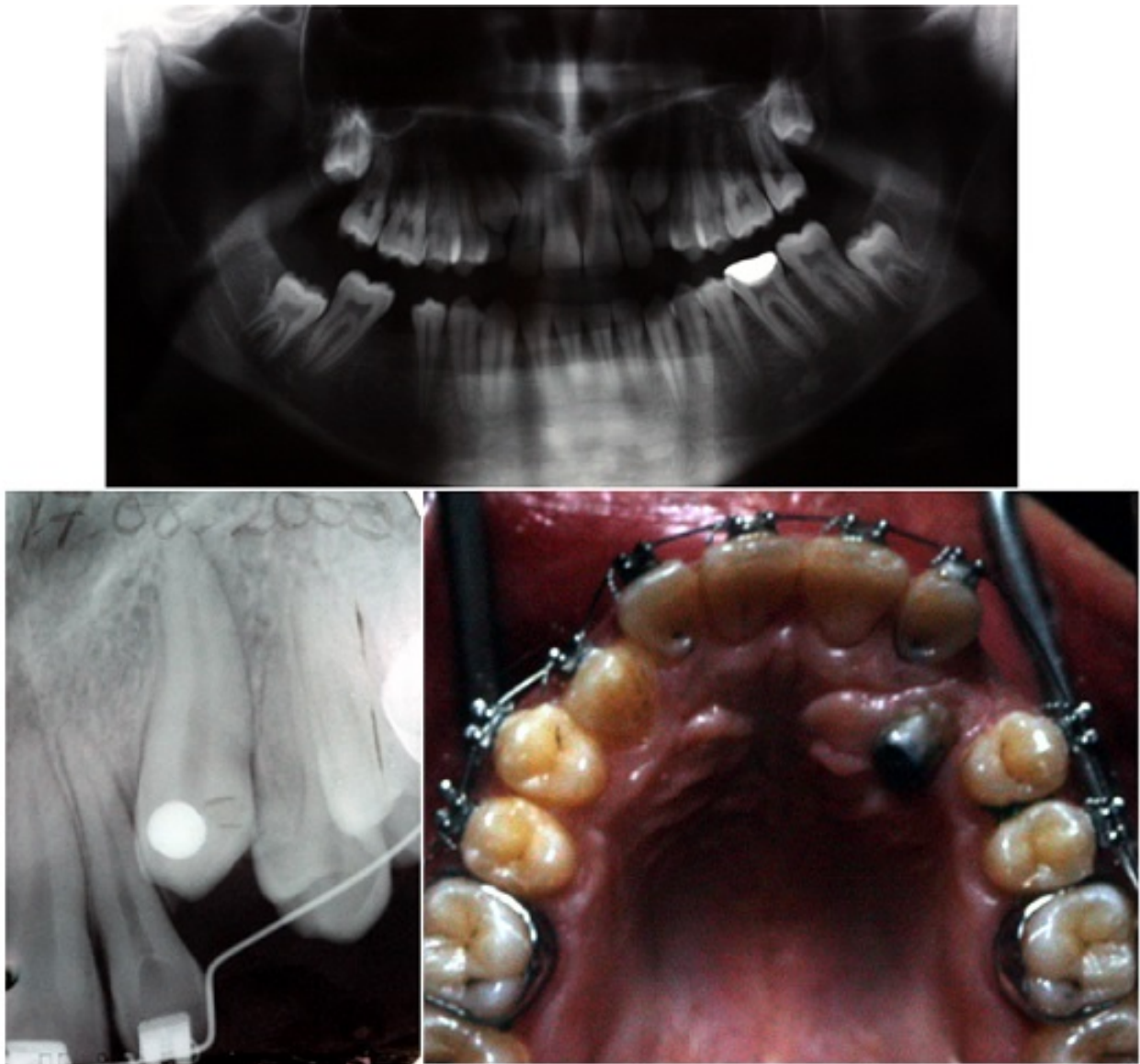


Figure 4. Orthodontic traction of bilateral impacted canines with the use of magnets. Right maxillary canine closer to the surface could be erupted with magnets. The left canine also moved closer along the top of the arch, however the patient discontinued his treatment.

An efficient way to make impacted canines erupt is to use closed-coil springs with eyelets, as long as no obstacles impede the path of the canine. If the canine is in close proximity to the incisor roots and a buccally directed force is applied, then it will contact the roots of adjacent teeth and may cause damage. (Figure 5) In addition, the canine position may not improve due to the root obstacle. Therefore regardless of the material used, the direction of the applied force should initially move the impacted tooth away from the roots of the neighboring teeth. In addition, the following is recommended: [21]

1. Initially maxillary arch should be levelled and aligned until a rigid rectangular arch can be inserted prior to the surgical exposure of the impacted tooth and application of traction forces [115].
2. Enough space should either be available in the arch or should be created for the impacted tooth;
3. In order to preserve the space created, either continuously tie the teeth mesially and distally to the canine or place a close coiled spring on the arch wire;
4. The eruption path might require the fabrication of auxiliaries numerous times due to anatomic obstructions during the traction process to redirect forces [115].
5. The use of light forces to move the impacted tooth, no more than 2 oz (60 g);
6. The arch wire should have enough stiffness, such as .018 × .022, to resist deformation against traction forces during canine extrusion (Figure 2). The added stiffness of the arch wire will diminish the undesirable "rollercoaster" effect caused by intrusion of the neighboring anchor teeth as a reaction to the deflection of a lighter and hence more flexible arch wire. Therefore, the magnitude of the force applied should not deflect the arch wire.

Orthodontic traction on the impacted tooth should be applied with light forces (20 to 30 g). In most of the cases, the root tip of the impacted canine is usually in a good position, so a tipping movement (light movement) is appropriate to move the crown toward the dental arch. The combined effects of "light" surgical exposure, "light" orthodontic movements, and "light" orthodontic forces are beneficial to the future periodontal health of the tooth since they minimize the loss of alveolar bone support and potential injury to the tooth during traction. However "heavy movement" such as torque during the traction cause more bone loss [21].

Fixed or removable appliances can be used for the traction of impacted tooth. However there are certain disadvantages of removable appliances such as the need for patient cooperation, limited control of tooth movement, and the inability to treat complex malocclusions [21] therefore only in cases with multiple missing teeth Hawley-type appliances might be used which transfer anchorage demands to the palatal vault and the alveolar ridge [124].

Most techniques have used the maxillary arch as anchorage for traction, which may be unsuitable in many clinical situations [94]. In cases in which the impacted canine is situated palatal to the lateral incisor, firstly an attempt should be made to move the canine away from lateral incisor before moving the impacted tooth toward the dental arch. In this situation if the desired forces cannot be applied from within the maxillary arch, mandibular arch might be

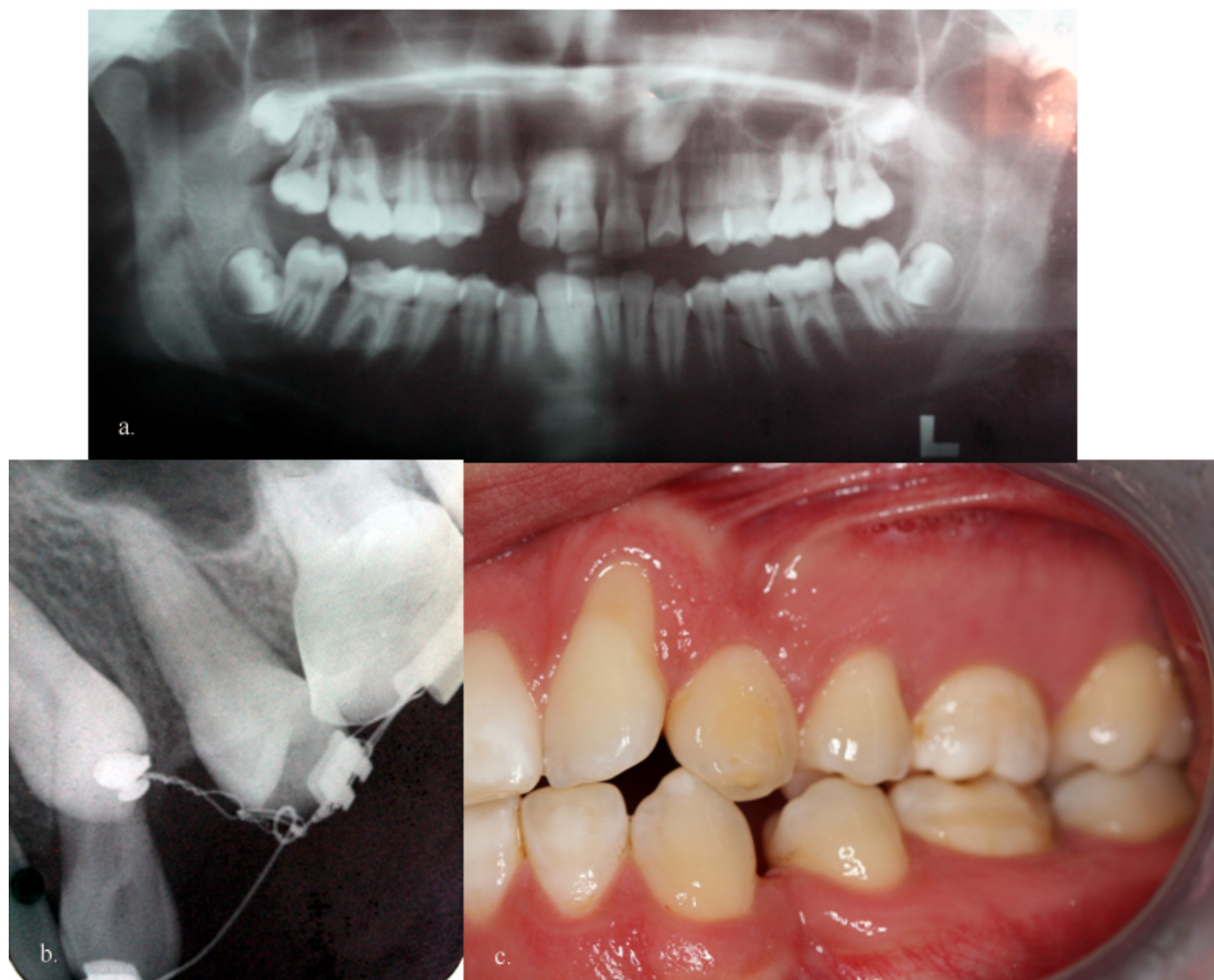

Figure 5. A buccally directed traction of a palatally impacted maxillary canine resulted in the buccal movement of the adjacent lateral root due to the close proximity and gingival recession was observed 10 years after treatment.

used as a source of anchorage. A mandibular fixed lingual arch with a vertical hook can be used for this purpose. Elastics are engaged in these vertical hooks and to the attachment on the impacted teeth for the required traction. In addition directional forces can be used by applying elastics. The main disadvantage of mandibular anchorage is the difficulty encountered in controlling the magnitude and direction of the applied forces because of the mobile mandibular arch [115].

Recently mini-screws have been proved to be reliable and convenient skeletal anchorage devices in the management of unerupted canines. Their mechanical resistance was found suitable for the initial orthodontic traction of these teeth. Mini-screws are placed in the alveolar process to improve the initial angulation of impacted canine teeth. Following soft tissue healing around the exposed tooth, mechanical traction can be activated with a nickel-titanium closed-coil spring exerting gentle forces 0.5–0.8 N (50–80 g) of force. The main advantage of this method is that the maxillary arch should not be bracketed until the canine has begun to move and ankylosis can be ruled out [125].

Poggio et al. [126] studied the interradicular anatomy of 25 patients with volumetric tomographic imaging. On the palatal side, the most available bone was determined between the second premolar and first molar whereas on the buccal side between the two premolars. These areas were found convenient for the clinical application of a mini-screw if extrusion of a palatally impacted canine is planned. On the buccal side less bone was determined between the second premolar and first molar. On the palatal side, the interseptal distance between the two molars was either less, yet still sufficient.

Impacted teeth tend to respond much later in adults than do those in children. Chaushu et al. [127] advised the placement of a temporary anchorage device in the palate at the time of closed exposure and the immediate application of elastic traction for several months since they have experienced failure of teeth to erupt despite the application of traction in patients in their fourth and fifth decades of life. They place orthodontic appliances if positive signs of movement are observed.

9.3. Retention considerations and long term follow-up of impacted canines

Treatment of impacted tooth is almost always a clinical challenge. Holistic treatment planning, prudent flap design, coupled with forced eruption using light extrusive forces, periodontal health and functional occlusion are central to achieving the desired long-term results.

Becker et al. [128] evaluated the posttreatment alignment of the impacted canines in patients who had completed their orthodontic treatment. They observed an increased incidence of rotations or spacings on the "impacted" side in 17.4% of the cases, whereas on the control side the incidence was only 8.7%. The control side had ideal alignment twice as often as did the impacted side.

Capriogli et al. [101] evaluated the long-term (4.6 years) periodontal response of palatally impacted maxillary canines aligned using a closed-flap surgical technique in association with a codified orthodontic traction system. No damage to periodontium was detected in the long-term.

Woloshyn et al. [129] evaluated the posttreatment changes nearly 4 years after treatment and compared the differences in the periodontal and pulpal status, root length, and tooth alignment between the side of the forced-erupted ectopically canine and the contralateral side. The probing attachment level was found lower on the mesial and distal aspect of the previously impacted canines, also the roots of the adjacent teeth were found shorter. The incidence of pulpal obliteration was 21% in the previously impacted canines. Significant posttreatment changes such as intrusion, lingual displacement, rotation, and discoloration was determined in 40% of the previously impacted teeth where as 91% had a normal appearance on the contralateral side.

A fiberotomy or a bonded fixed retainer is suggested to prevent rotational relapse, after the completion of the desired movements and often before the appliances are removed. Removing a "halfmoon-shaped wedge" of tissue from the lingual side of the canine might intercept lingual drift after correction of palatally impacted canines [130].

D'Amico et al. [131] reported the adverse effects of the orthodontic-surgical treatment for impacted maxillary canines in the long term conducted in a sample of 61 cases. 6.5% of the patients were dissatisfied with the esthetic results, whereas the orthodontist estimated the results as good in only 57% of the cases. Canine guidance was detected less frequently on the working side during lateral movements in previously impacted canines due to the significant difference in their inclination compared to normally erupted ones.

9.4. Frequent complications observed with unerupted teeth

Surgical exposure of the impacted tooth and the complex orthodontic mechanisms that are applied to align the impacted tooth into the arch may lead to deleterious consequences for the supporting structures of the tooth, such as displacement and devitalization, ankylosis or loss of vitality, recurrent pain, cystic degeneration, invasive servical root resorption, external root resorption of the canine and adjacent teeth. Furthermore loss of periodontal bone support, gingival recession, sensitivity problems or combinations of these factors may be observed [129].(Figure 5) Most of these risks can be prevented with proper management of periodontal tissues and timing of care. These problems can result in prolonged treatment time, esthetic deformities and often the loss of teeth.

If no movement of the impacted canine is observed, this may be as a result of single or combination of the following reasons: [132]

- inappropriate positional diagnosis of the impacted teeth and its relationship with the roots of the adjacent teeth which leads to incorrect direction of traction
- a lack of considerably anchorage requirement will lead to inefficient mechanotherapy and unnecessarily longer treatment
- anyklosis might have afflicted the impacted tooth either a priori or as the result of the earlier surgical or the orthodontic maneuvers.
- scar tissue might have blocked the wire chain, [133]

If, the tooth does not show clear evidence of movement after six months of orthodontic force application, a re-evaluation is necessary. Ankylosis, one of the major complications associated with impacted canines, can rarely be detected based on clinical and conventional radiographic examinations however CBCT provides a better diagnosis of the area of ankylosis [134].

In the recent study of Koutzoglou and Kostaki [135] evidence of an association between exposure technique and ankylosis was determined. The percentage of ankylosis was 3.5% in the open technique and 14.5% in the closed technique. They have defined anyklosis as impacted canines being immobilized a priori or during traction, due to all the possible causes that could contribute to immobilization, such as all types of external tooth resorption and other known or unknown factors. Additionally, they found a evidence that the grade of impaction and the patient's age are significant predictors of ankylosis.

Traditionally, once a tooth becomes ankylosed, surgical luxation has been the treatment of choice [136]. Although orthodontic light forces are applied immediately after luxation to

prevent reankylosis, ankylosis often occurs again [137]. Another viable treatment option for ankylosed or dilacerated maxillary canines is apicotomy proposed by Puricelli [138] in 1987. An apicotomy is a guided fracture of a canine root apex performed with a small chisel followed by orthodontic traction of the canine crown. Puricelli's data [138, 139] showed that in 29 patients who had the procedure, 26 procedures were successful and 3 failed.

Becker and Chausu [109] stated that invasive cervical root resorption is the cause of many failed impacted teeth, rather than the knee-jerk and usually unproven application of the label "ankylosis." It is difficult to diagnose on a radiograph, yet, as the lesion grows, bone is usually deposited in the depth of the resorption lacunae, and then the tooth will no longer respond to extrusive traction [140]. Radical surgery extending down to the cemento-enamel junction is likelihood of this possible sequel.

Becker et al. [132] reported that repeat surgery was required for 62.9% of the impacted canines in which corrective treatment was started, mostly to redirect the ligature wires with the guidance of the 3-dimensional imaging. If orthodontic traction fails other treatment options should be considered. Prosthetic replacement might be performed yet preparation of the adjacent, usually healthy teeth for a conventional fixed bridge is far from ideal. Implant placement would be another option that generally requires extraction of the impacted tooth. However this causes a bony defect which must be bone-grafted. Orthodontic closure of the gap might also be considered but it results in asymmetry in unilateral cases [125].

10. Conclusions

The management of impacted canines is important in terms of esthetics and function and, requires a qualified experience of a number of clinicians. If patients are evaluated and treated appropriately, then the frequency of ectopic eruption and subsequent impaction of the maxillary canine can be reduced. Various surgical and orthodontic techniques may be used to uncover impacted maxillary canines related to its position. Accurate localization, conservative management of the soft tissues, selection of appropriate surgical approach, rigid anchorage unit, and the direction of the orthodontic traction are the important factors for the successful management of impacted canines.

Author details

Belma Işık Aslan* and Neslihan Üçüncü

*Address all correspondence to: belmaslan2003@yahoo.com

Gazi University, Faculty of Dentistry, Department of Orthodontics, Ankara, Turkey

References

- [1] Lindauer SJ, Rubenstein LK, Hang WM, Andersen WC, Isaacson RJ. Canine Impaction Identified Early with Panoramic Radiographs. *The Journal of American Dental Association* 1992;123(3) 91–92.
- [2] Litsas G, Acar A. A Review of Early Displaced Maxillary Canines: Etiology, Diagnosis and Interceptive Treatment. *The Open Dentistry Journal* 2011; 5: 39-47.
- [3] Brin I, Becker A, Shalhav M. Position of the Maxillary Permanent Canine in Relation to Anomalous or Missing Lateral Incisors: a Population Study. *European Journal of Orthodontics* 1986; 8(1) 12-16.
- [4] Chu FC, Li TK, Lui VK, Newsome PR, Chow RL, Cheung LK. Prevalence of Impacted Teeth and Associated Pathologies-a Radiographic Study of the Hong Kong Chinese Population. *Hong Kong Medical Journal* 2003; 9(3) 158-163.
- [5] Thilander B, Myrberg N. The Prevalence of Malocclusion in Swedish School Children. *Scandinavian Journal of Dental Research* 1973; 81(1) 12-21.
- [6] Johnston WD. Treatment of Palatally Impacted Canine Teeth. *American Journal of Orthodontics* 1969; 56(6) 589-596.
- [7] Ericson S, Kurol J. Resorption of Incisors After Ectopic Eruption of Maxillary Canines. A CT study. *Angle Orthodontist* 2000; 70(6) 415-423.
- [8] Nieri M, Crescini A, Rotundo R, Baccetti T, Cortellini P, Pini Prato GP. Factors Affecting the Clinical Approach to Impacted Maxillary Canines: a Bayesian Network Analysis. *American Journal of Orthodontics and Dentofacial Orthopedics* 2010; 137(6) 755-762.
- [9] Ericson S, Kurol J. Radiographic Examination of Ectopically Erupting Maxillary Canines. *American Journal of Orthodontics and Dentofacial Orthopedics* 1988; 91(6) 483-492.
- [10] Coulter J, Richardson A. Normal Eruption of the Maxillary Canine Quantified in Three Dimensions. *European Journal of Orthodontics* 1997; 19(2) 171–183.
- [11] Van Der Linden PGM. Transition of the Human Dentition. Monograph, Craniofacial Growth Series. Ann Arbor, MI, Center For Human Growth And Development: University Of Michigan;1982
- [12] Becker A. *The Orthodontic Treatment Of Impacted Teeth* 2nd Ed. Jerusalem: Informa Healthcare; 2007.
- [13] Moyers RE, Van Der Linden FP, Riolo ML, Mcnamara Jr. Standards of Human Occlusal Development. Monograph 5, Craniofacial Growth Series. Ann Arbor, MI, Center For Human Growth And Development: The University Of Michigan; 1976.

- [14] Nanda SK. *The Developmental Basis of Occlusion And Malocclusion*. Chicago, IL: Quintessence Publishing; 1983.
- [15] Roberts-Harry D, Sandy J. Orthodontics. Part 10: Impacted Teeth. *British Dental Journal* 2004; 196(6) 319–327.
- [16] Brand RW, Isselhard DE. *Anatomy of Orofacial Structures*. 3rd Ed. St. Louis, MO: CV Mosby; 1986.
- [17] Hurme VO. Ranges of Normalcy in the Eruption of Permanent Teeth. *Journal of Dentistry for Children* 1949; 16(2) 11-15.
- [18] Wise GE, King GJ. Mechanisms of Tooth Eruption and Orthodontic Tooth Movement. *Journal of Dental Research* 2008; 87(5) 414-434.
- [19] Suri L, Gagari E, Vastardis H. Delayed Tooth Eruption: Pathogenesis, Diagnosis, and Treatment. A Literature Review. *American Journal of Orthodontics and Dentofacial Orthopedics* 2004; 126(4) 432-445.
- [20] Ngan P, Hornbrook R, Weaver B. Early Timely Management of Ectopically Erupting Maxillary Canines. *Seminars in Orthodontics* 2005; 11: 152–163.
- [21] Bishara SE. Clinical Management of Impacted Maxillary Canines. *Seminars in Orthodontics* 1998; 4(2) 87-98.
- [22] Yawaka Y, Kaga M, Osanai M, Fukui A, Oguchi H. Delayed Eruption of Premolars with Periodontitis of Primary Predecessors and a Cystic Lesion: A Case Report. *International Journal of Paediatric Dentistry* 2002; 12(1) 53-60.
- [23] Acquavella FJ. Delayed Eruption. Why? *The New York State Dental Journal* 1965; 31(10) 448-449.
- [24] Tomizawa M, Yonemochi H, Kohno M, Noda T. Unilateral Delayed Eruption of Maxillary Permanent First Molars: Four Case Reports. *Pediatric Dentistry* 1998; 20(1) : 53-56.
- [25] Katz J, Guelmann M, Barak S. Hereditary Gingival Fibromatosis with Distinct Dental, Skeletal and Developmental Abnormalities. *Pediatric Dentistry* 2002; 24(3) 253-256.
- [26] Sekletov GA. Supercomplex Retained Tooth is the Cause of Delayed Eruption of the Upper Central Left Incisor. *Therapy Stomatologiia* 2001; 80(4) 66-68.
- [27] Proffit WR, Vig KWL. Primary Failure of Eruption: A Possible Cause of Posterior Open-Bite. *American Journal of Orthodontics and Dentofacial Orthopedics* 1981;80(2) 173-190.
- [28] Raghoebar GM, Boering G, Vissink A, Stegenga B. Eruption Disturbances of Permanent Molars: A Review. *Journal of Oral Pathology & Medicine* 1991; 20(4) 159-166.
- [29] Bishara SE. Impacted Maxillary Canines: A Review. *American Journal of Orthodontics and Dentofacial Orthopedics* 1992; 101(2) 159-171.

- [30] Pirinen S, Arte S, Apajalahti S. Palatal Displacement of Canine is Genetic and Related to Congenital Absence of Teeth. *Journal of Dental Research* 1996; 75(10) 1742-1746.
- [31] Kokich VG. Surgical and Orthodontic Management of Impacted Maxillary Canines. *American Journal of Orthodontics and Dentofacial Orthopedics* 2004; 126(3) 278-283.
- [32] Jacoby H. The Etiology Of Maxillary Canine Impactions. *American Journal of Orthodontics* 1983; 84(2) 125-132.
- [33] Al-Nimri K, Gharaibeh T. Space Conditions and Dental and Occlusal Features in Patients with Palatally Impacted Maxillary Canines: An Aetiological Study. *European Journal of Orthodontics* 2005; 27(5) 461-465.
- [34] Mcconnell TL, Hoffman DL, Forbes DP, Jensen EK, Wientraub NH. Maxillary Canine Impaction in Patients With Transverse Maxillary Deficiency. *Journal of Dentistry for Children* 1996; 63(3) 190-195.
- [35] Langberg BJ, Peck S. Adequacy of Maxillary Dental Arch Width In Patients with Palatally Displaced Canines. *American Journal of Orthodontics and Dentofacial Orthopedics* 2000; 118(2) 220-223.
- [36] Peck S, Peck L, Kataja M. Site-Specificity of Tooth Maxillary Agenesis in Subjects with Canine Malpositions. *Angle Orthodontist* 1996; 66(6) 473-476.
- [37] Peck S, Peck L, Kataja M. Concomitant Occurrence of Canine Malposition and Tooth Agenesis: Evidence of Orofacial Genetic Fields. *American Journal of Orthodontics and Dentofacial Orthopedics* 2002; 122(6) 657-660.
- [38] Sacerdoti R, Baccetti T. Dentoskeletal Features Associated With Unilateral Or Bilateral Palatal Displacement Of Maxillary Canines. *Angle Orthodontist* 2004; 74(6) 725-32.
- [39] Shafer WG, Hine MK, Levy BM, Editors. *A Textbook Of Oral Pathology*. 2nd Ed. Philadelphia: WB Saunders; 1963.
- [40] Suri L, Gagari E, Vastardis H. Delayed Tooth Eruption: Pathogenesis, Diagnosis, and Treatment. A Literature Review. *American Journal of Orthodontics and Dentofacial Orthopedics* 2004; 126(4) 432-445.
- [41] Moss JP. The Unerupted Canine. *The Dental Practitioner and Dental Record* 1972; 22(6) 241-248.
- [42] Ericson S, Kurol J. Longitudinal Study and Analysis of Clinical Supervision of Maxillary Canine Eruption. *Community Dent Oral Epidemiology* 1986; 14(3) 172-176.
- [43] Ericson S, Kurol J: Radiographic Assessment Of Maxillary Canine Eruption In Children with Clinical Signs of Eruption Disturbances. *European Journal of Orthodontics* 1981; 8(3) 133-140.

- [44] Williams BHJ. Diagnosis and Prevention of Maxillary Cuspid Impaction. *Angle Orthodontist* 1981; 51(1) 30-40.
- [45] Bishara SE. Clinical Management of Impacted Maxillary Canines. *Seminars in Orthodontics* 1998; 4(2) 87-98.
- [46] Langland OE, Francis SH, Langlois RD. Atlas Of Special Technics in Dental Radiology. In: *Textbook of Dental Radiology*. Springfield, IL: Charles C. Thomas Publishes; 1984.
- [47] Ericson S, Kuroi J. Radiographic Examination of Ectopically Erupting Maxillary Canines. *American Journal of Orthodontics and Dentofacial Orthopedics* 1987; 91(6) 483-492.
- [48] Turk MH, Katzenell J. Panoramic Localization. *Oral Surgery, Oral Medicine and Oral Pathology* 1970; 29(2) 212-215.
- [49] Crescini A, Nieri M, Buti J, Baccetti T, Pini Prato GP. Pre-Treatment Radiographic Features for the Periodontal Prognosis of Treated Impacted Canines. *Journal of Clinical Periodontology* 2007; 34(7) 581-587.
- [50] Liu DG, Zhang WL, Zhang ZY, Wu YT, Ma XC. Localization of Impacted Maxillary Canines and Observation of Adjacent Incisor Resorption with Cone-Beam Computed Tomography. *Oral Surgery, Oral Medicine and Oral Pathology, Oral Radiology and Endodontics* 2008; 105(1) 91-98.
- [51] Boeddinghaus R, Whyte A. Current Concepts In Maxillofacial Imaging. *European Journal of Radiology* 2008; 66(3) 396-418.
- [52] Algerban A, Jacobs R, Keirsbilck P, Aly M, Swinnen S, Fieuws S, Willems G. The Effect of Using CBCT In the Diagnosis of Canine Impaction and Its Impact on the Orthodontic Treatment Outcome. *Journal of Orthodontic Science*. 2014; 3(2) 34-40.
- [53] Wriedt S, Jaklin J, Al-Nawas B, Wehrbein H. Impacted Upper Canines: Examination and Treatment Proposal Based On 3D Versus 2D Diagnosis. *Journal of Orofacial Orthopedics* 2011; 73(1) 28-40.
- [54] Algerban A, Jacobs R, Lambrechts P, Loozen G, Willems G. Root Resorption of the Maxillary Lateral Incisor Caused by Impacted Canine: A Literature Review. *Clinical Oral Investigations* 2009; 13(3) 247-255.
- [55] Oberoi S, Knueppel S. Three-Dimensional Assessment of Impacted Canines and Root Resorption Using Cone Beam Computed Tomography. *Oral Surgery Oral Medicine Oral Pathology and Oral Radiology* 2012; 113(2) 260-267.
- [56] Taylor RW. Eruptive Abnormalities In Orthodontic Treatment. *Seminars in Orthodontics* 1998; 4(2) 79-86.
- [57] Mc Sherry PF. The Assessment of and Treatment Options for the Burried Maxillary Canine. *Dental Update* 1996; 23(1) 7-10.

- [58] Machen DE. Legal Aspects of Orthodontic Practice: Risk Management Concepts. The Impacted Canine. *American Journal of Orthodontics and Dentofacial Orthopedics* 1989; 96(3) 270-271.
- [59] Mc Sherry PF. The Ectopic Maxillary Canine: A Review. *British Journal of Orthodontics* 1998; 25(3) 209-216.
- [60] Kurol J, Ericson S, Andreasen JO. The Impacted Maxillary Canine. In: Andreasen JO, Kølsen Petersen J, Laskin D (eds.) *Textbook And Color Atlas Of Tooth Impactions*. Copenhagen: Munksgaard; 1997. p124-164.
- [61] Ericson S, Kurol J. Early Treatment of Palatally Erupting Maxillary Canines by Extraction of the Primary Canines. *European Journal of Orthodontics* 1988; 10(4) 283-295.
- [62] Power SM, Short MB. An Investigation into the Response of Palatally Displaced Canines to the Removal of Deciduous Canines and an Assessment of Factors Contributing to a Favourable Eruption. *British Journal of Orthodontics* 1993; 20(3) 215-223.
- [63] Baccetti T, Leonardi M, Armi P. A Randomized Clinical Study of Two Interceptive Approaches to Palatally Displaced Canines. *European Journal of Orthodontics* 2008; 30(4) 381-385.
- [64] Olive RJ. Orthodontic Treatment of Palatally Impacted Maxillary Canines. *Australian Journal of Orthodontics* 2002; 18(2) 64-70.
- [65] Broadbent BH. Ontogenic Development of Occlusion. *Angle Orthodontist* 1941; 11(4) 223-241.
- [66] Baccetti T, Sigler LM, Mcnamara JA. An RCT on Treatment of Palatally Displaced Canines with RME and/or a Transpalatal Arch. *European Journal of Orthodontics* 2011; 33(6) 601-607.
- [67] Puricelli E, Morganti MA, Azambuja HV, Ponzoni D, Friedrisch CC. Partial Maxillary Osteotomy Following an Unsuccessful Forced Eruption of an Impacted Maxillary Canine-10 Year Follow-Up. Review and Case Report. *Journal of Applied Oral Science* 2012; 20(6) 667-72.
- [68] Mirabella D, Giunta G, Lombardol. Substitution of Impacted Canines by Maxillary First Premolars: A Valid Alternative to Traditional Orthodontic Treatment. *American Journal of Orthodontics and Dentofacial Orthopedics* 2013; 143(1) 125-33.
- [69] Rosa M, Zachrisson B. Integrating Space Closure and Esthetic Dentistry In Patients with Missing Maxillary Lateral Incisors. *Journal of Clinical Orthodontics* 2007; 41(9) 563-573.
- [70] Thoraton L. Anterior Guidance: Group Function/Canine Guidance. A Literature Review. *The Journal of Prosthetic Dentistry* 1990; 64(4) 479-482.
- [71] Huth KC, Nazet M, Paschos E, Linsenmann R, Hickel R, Nolte D. Autotransplantation and Surgical Uprighting of Impacted or Retained Teeth: A Retrospective Clinical

- Study and Evaluation of Patient Satisfaction. *Acta Odontologica Scandinavica* 2013; 71(6) 1538–1546.
- [72] Blomlof L, Lindskog S, Andersson L, Hedstrom KG, Hammarstrom L. Storage of Experimentally Avulsed Teeth In Milk Prior to Replantation. *Journal of Dental Research* 1983; 62(8) 912-916.
- [73] Oswald RJ, Harrington GW, Van Hassel HJ. Replantation 1: The Role of the Socket. *Journal of Endodontics* 1980; 6(3) 479-484.
- [74] Andersson L, Lindskog S, Blomlof L, Hedstrom KG, Hammarstrom L. Effect of Masticatory Stimulation on Dentoalveolar Ankylosis After Experimental Tooth Replantation. *Endodontics Dental Traumatology* 1985; 1(1) 13-6.
- [75] Andreasen JO. The Effect of Pulp Extirpation or Root Canal Treatment on Periodontal Healing After Replantation of Permanent Incisors in Monkeys. *Journal of Endodontics* 1981; 7(6) 245-252.
- [76] Gonnissen H, Politis C, Schepers S, Lambrichts I, Vrielinck L, Sun Y, et al. Long-Term Success and Survival Rates of Autogenously Transplanted Canines. *Oral Surgery Oral Medicine Oral Pathology Oral Radiology and Endodontics* 2010; 110(5) 570–578.
- [77] Patel S, Fanshawe T, Bister D, Cobourne MT. Survival and Success of Maxillary Canine Autotransplantation: A Retrospective Investigation. *European Journal of Orthodontics* 2011; 33(3) 298–304.
- [78] Hall GM, Reade PC. Root Resorption Associated with Autotransplanted Maxillary Canine Teeth. *The British Journal of Oral Surgery* 1983; 21(3) 179-191.
- [79] Andreasen JO. Ectopic Eruption of Permanent Canines Eliciting Resorption of Incisors. *Tandlaegebladet* 1987; 91(11) 487-492.
- [80] Shatz JP, Byloff F, Bernhard JP, Joho JP. Severely Impacted Canines: Autotransplantation as an Alternative. *International Journal of Adult Orthodontics and Orthognathic Surgery* 1992; 7(1) 45-52.
- [81] Kristerson L. Autotransplantation of Human Premolars. *International Journal of Oral Surgery* 1985; 14(2) 200-213.
- [82] Oshimi H. Nemawashi Jigging and Gingival Muffler in Autogenous Tooth Transplantation. *Nippon Dental Review* 1993; 607: 65-74.
- [83] Suzaki Y, Matsumoto Y, Kanno Z, Soma K. Preapplication of Orthodontic Forces to the Donor Teeth Affects Periodontal Healing of Transplanted Teeth. *Angle Orthodontist* 2008; 78(3) 495-501.
- [84] Ru N, Bai Y. Canine Autotransplantation: Effect of Extraction Site Preservation with a Titanium Prosthesis and a Bioresorbable Membrane. *American Journal of Orthodontics and Dentofacial Orthopedics* 2013; 143(5) 724-734.

- [85] Schatz JR, Joho JR. A Clinical and Radiographic Study of Autotransplanted Impacted Canines. *International Journal of Oral and Maxillofacial Surgery* 1993; 22(6) 342-346.
- [86] Arikan F, Nizam N, Sonmez S. 5-Year Longitudinal Study of Survival Rate and Periodontal Parameter Changes at Sites of Maxillary Canine Autotransplantation. *Journal of Periodontology* 2008; 79(4) 595-602.
- [87] Gonnissen H, Politis C, Schepers S, Lambrechts I, Vrielinck L, Sun Y, et al. Long-Term Success and Survival Rates of Autogenously Transplanted Canines. *Oral Surgery Oral Medicine Oral Pathology Oral Radiology and Endodontics* 2010; 110(5) 570-578
- [88] Pogrel MA. Evaluation of Over 400 Autogenous Tooth Transplants. *Journal of Oral and Maxillofacial Surgery* 1987; 45(3) 205-211.
- [89] Ahlberg K, Bystedt H, Eliasson S, Odenrick L. Long-Term Evaluation of Autotransplanted Maxillary Canines with Completed Root Formation. *Acta Odontologica Scandinavica* 1983; 41(1) 23-31.
- [90] Zachrisson BU, Thilander B. *Introduction to Orthodontics*, 5th Edn. Stockholm: Tandlakaförlaget; 1985.
- [91] Lewis PD. Preorthodontic Surgery in the Treatment of Impacted Canines. *American Journal of Orthodontics* 1971; 60(4) 383-397.
- [92] Nordenvall KJ. Glass Ionomer Cement Used as Surgical Dressing After Radical Surgical Exposure of Impacted Teeth. *Swedish Dental Journal* 1992(3) 16: 87-92.
- [93] Kohavi D, Becker A, Zilberman Y. Surgical Exposure, Orthodontic Movement, and Final Tooth Position as Factors in Periodontal Breakdown of Treated Palatally Impacted Canines. *American Journal of Orthodontics* 1984; 85(1) 72-77.
- [94] Fournier A, Turcottej, Bernard C. Orthodontic Considerations in the Treatment of Maxillary Impacted Canines. *American Journal of Orthodontics* 1982; 81(3) 236-239.
- [95] Stellzig A, Basdra EK, Kourposch G. The Etiology of Canine Tooth Impaction: A Space Analysis. *Fortschritte Der Kieferorthopadie* 1994; 55(3) 97-103.
- [96] Vanarsdall RL Jr. Efficient Management of Unerupted Teeth: A Time-Tested Treatment Modality. *Seminars in Orthodontics* 2010; 16(3) 212-221.
- [97] Becker A, Brin I, Ben-Bassat Y, Zilberman Y, Chaushu S. Closed-Eruption Surgical Technique for Impacted Maxillary Incisors: A Postorthodontic Periodontal Evaluation. *American Journal of Orthodontics and Dentofacial Orthopedics* 2002; 122(1) 9-14.
- [98] Vermette M, Kokich V, Kennedy D. Uncovering Labially Impacted Teeth: Closed Eruption and Apically Positioned Flap Techniques. *Angle Orthodontist* 1995; 65(1) 23-32.

- [99] Vanarsdall R, Corn H. Soft Tissue Management of Labially Positioned Unerupted Teeth. *American Journal of Orthodontics* 1977; 72(1) 53-64.
- [100] Kokich VG, Mathews DA. Impacted Teeth: Surgical and Orthodontic Considerations. In: JA McNamara Jr. (ed.) *Orthodontics and Dentofacial Orthopedics*. Ann Arbor, Michigan: Needham Press; 2001.
- [101] Caprioglio A, Vanni A, Bolamperti L. Long-Term Periodontal Response to Orthodontic Treatment of Palatally Impacted Maxillary Canines. *European Journal of Orthodontics* 2013; 35(3) 323–328.
- [102] Kuftinec MM, Stom D, Shapira Y. The Impacted Maxillary Canine: I. Review of Concepts. *ASDS Journal of Dentistry for Children* 1995; 62(5) 317-324.
- [103] Tulcan T. An Evaluation of Treatment Outcomes of Labially Impacted Maxillary Canines. PhD Thesis, Department of Orthodontics, Philadelphia; 1997.
- [104] Graber TM, Vanarsdall RL Jr. *Orthodontics Current Principles and Techniques* 3rd Ed. St Louis: Mosby; 2000.
- [105] Schmidt A. Periodontal Reaction to Early Uncovering, Autonomous Eruption, and Orthodontic Alignment of Palatally Impacted Maxillary Canines. PhD Thesis. University of Washington, Seattle; 2004.
- [106] Schmidt AD, Kokich VG. Periodontal Response to Early Uncovering, Autonomous Eruption, and Orthodontic Alignment of Palatally Impacted Maxillary Canines. *American Journal of Orthodontics and Dentofacial Orthopedics* 2007; 131(4) 449-455.
- [107] Becker A, Shpack N, Shteyer A. Attachment Bonding to Impacted Teeth at the Time of Surgical Exposure. *European Journal of Orthodontics* 1996; 18(5) 457-463.
- [108] Becker A. *The Orthodontic Treatment of Impacted Teeth*. Oxford, London: Wiley-Blackwell; 2012.
- [109] Becker A, Chaushu S. Palatally Impacted Canines: The Case for Closed Surgical Exposure And Immediate Orthodontic Traction 2013; 143(4) 451-459.
- [110] Burden DJ, Mullally BH, Robinson SN. Palatally Ectopic Canines: Closed Eruption Versus Open Eruption. *American Journal of Orthodontics and Dentofacial Orthopedics* 1999; 115(6) 640-644.
- [111] Parkin NA, Milner RS, Deery C, Tinsley, Smith AM, Germain P, Freeman JV, Bell SJ, Benson PE. Periodontal Health of Palatally Displaced Canines Treated with Open Or Closed Surgical Technique: A Multicenter, Randomized Controlled Trial. *American Journal of Orthodontics and Dentofacial Orthopedics* 2013; 144(2) 176-184.
- [112] Parkin N, Benson PE, Thind B, Shah A. Open Versus Closed Surgical Exposure of Canine Teeth That are Displaced in the Roof of the Mouth. *The Cochrane Database of Systematic Reviews* 2008; 8(4) CD006966

- [113] Smailiene D, Kavaliauskiene A, Pacauskiene I, Zasciurinskiene E, Bjerklin K. Palatally Impacted Maxillary Canines: Choice of Surgical Orthodontic Treatment Method Does not Influence Post-Treatment Periodontal Status. A Controlled Prospective Study. *European Journal Of Orthodontics* 2013; 35(6) 803–810.
- [114] Kuftinec MM, Shapiray. The Impacted Maxillary Canine: II. Surgical Consideration and Management. *Quintessence International Dental Digest* 1984; 15(9): 895-897.
- [115] Sinha PK, Nanda RS. Management of Impacted Maxillary Canines Using Mandibular Anchorage. *American Journal of Orthodontics and Dentofacial Orthopedics* 1999; 115(3) 254-257.
- [116] Goodsell JF. Surgical Exposure And Orthodontic Guidance of the Impacted Tooth. *Dental Clinics of North America* 1979; 23(3) 385–392.
- [117] Mclaughlin R, Bennett C, Trevisi HJ. *Systemized Orthodontic Treatment Mechanics* 1st Ed. Barcelona, Spain: Mosby; 2002.
- [118] Crescini A, Clauser C, Giorgetti R, Cortelini P, Pini Prato GP. Tunnel Traction of Infra-Osseous Maxillary Canines: A Three Year Periodontal Follow-Up. *American Journal of Orthodontics and Dentofacial Orthopedics* 1994; 105(1) 61-72.
- [119] Shapira Y, Kuftinec MM. Treatment of Impacted Cuspids the Hazard Lasso. *Angle Orthodontist* 1981 ; 51(3) 203-207.
- [120] Celi D, Catalfamo L, Deli R. Palatally Impacted Canines:The Double Traction Technique. *Progress in Orthodontics* 2007; 8(1) 16-26.
- [121] Bowman SJ, Carano A. The Kilroy Spring for Impacted Teeth. *Journal of Clinical Orthodontics* 2003; 37(12) 683-688.
- [122] Shastri D, Nagar A, Tandon P. Alignment of Palatally Impacted Canine with Open Window Technique and Modified K-9 Spring. *Contemporary Clinical Dentistry* 2014; 5(2) 272–274.
- [123] Vardimon AD, Graber TM, Drescher D, Bourauel C. Rare Earth Magnets and Impaction. *American Journal of Orthodontics and Dentofacial Orthopedics* 1991; 100(6) 494-512.
- [124] Mcdonald E Yap WL. The Surgical Exposure and Application of Direct Traction of Unerupted Teeth. *American Journal of Orthodontics* 1982; 89(4) 331-340.
- [125] Kocsis A, Seres L. Orthodontic Screws to Extrude Impacted Maxillary Canines. *Journal of Orofacial Orthopedics* 2011; 73(1) 19-27.
- [126] Poggio PM, Incorvati C, Velo S, Carano A. "Safe Zones": A Guide for Miniscrew Positioning in the Maxillary and Mandibular Arch. *Angle Orthodontist* 2006; 76(2)191–197.

- [127] Chaushu S, Chaushu G. Skeletal Implant Anchorage in the Treatment of Impacted Teeth—A Review of the State of the Art. *Seminars in Orthodontics* 2010; 16: 234-241.
- [128] Becker A, Kohavi D, Zilberman. Periodontal Status Following the Alignment of Palatally Impacted Canine Teeth. *American Journal of Orthodontics* 1983; 84(4) 332-336.
- [129] Woloshyn H, Årtun J, Kennedy DB, Joondeph DR. Pulpal and Periodontal Reactions to Orthodontic Alignment of Palatally Impacted Canines. *Angle Orthodontist* 1994; 64(4) 257-264.
- [130] Clark D. The Management of Impacted Canines: Free Physiologic Eruption. *Journal of the American Dental Association* 1971; 82(4) 836-840.
- [131] D'Amico RM, Bjerklin K, Kurol J, Falahat B. Long-Term Results of Orthodontic Treatment of Impacted Maxillary Canines. *Angle Orthodontist* 2003; 73(3) 231-238.
- [132] Becker A, Chaushu G, Chaushu S. Analysis of Failure in the Treatment of Impacted Maxillary Canines. *American Journal of Orthodontics and Dentofacial Orthopedics* 2010; 137(6) 743-754.
- [133] Becker A, Chaushu S. Success Rate and Duration of Orthodontic Treatment for Adult Patients with Palatally Impacted Canines. *American Journal of Orthodontics and Dentofacial Orthopedics* 2003; 124(5) 509–514.
- [134] Haney E, Gansky SA, Lee JS, Johnson E, Maki K, Miller AJ, Huang JC. Comparative Analysis of Traditional Radiographs and Cone-Beam Computed Tomography Volumetric Images in the Diagnosis and Treatment Planning of Maxillary Impacted Canines. *American Journal of Orthodontics and Dentofacial Orthopedics* 2010; 137(5) 590-597.
- [135] Koutzoglou SI, Kostaki A. Effect of Surgical Exposure Technique, Age, and Grade of Impaction on Ankylosis of an Impacted Canine, and the Effect of Rapid Palatal Expansion on Eruption: A Prospective Clinical Study. *American Journal of Orthodontics and Dentofacial Orthopedics* 2013; 143(3) 342-352.
- [136] Pithon MM, Bernardes LA. Treatment of Ankylosis of the Mandibular First Molar with Orthodontic Traction Immediately After Surgical Luxation. *American Journal of Orthodontics and Dentofacial Orthopedics* 2011; 140(3) 396-403.
- [137] Turley PK, Crawford LB, Carrington KW. Traumatically Intruded Teeth. *Angle Orthodontist* 1987; 57(3) 234-244.
- [138] Puricelli E. Treatment of Retained Canines by Apicotomy. *RGO* 1987; 35(4) 326-330.
- [139] Puricelli E. Apicotomy: A Root Apical Fracture for Surgical Treatment of Impacted Upper Canines. *Head Face Med* 2007; 6(3) 33.
- [140] Becker A, Abramovitz I, Chaushu S. Failure of Treatment of Impacted Canines Associated with Invasive Cervical Root Resorption. *Angle Orthodontist* 2013; 83(5) 870-876.

