

We are IntechOpen, the world's leading publisher of Open Access books Built by scientists, for scientists

4,400

Open access books available

117,000

International authors and editors

130M

Downloads

Our authors are among the

154

Countries delivered to

TOP 1%

most cited scientists

12.2%

Contributors from top 500 universities



WEB OF SCIENCE™

Selection of our books indexed in the Book Citation Index
in Web of Science™ Core Collection (BKCI)

Interested in publishing with us?
Contact book.department@intechopen.com

Numbers displayed above are based on latest data collected.
For more information visit www.intechopen.com



A New Protocol of Tweed-Merrifield Directional Force Technology Using Micro-Implant Anchorage (M.I.A.)

Jong-Moon Chae

Additional information is available at the end of the chapter

<http://dx.doi.org/10.5772/60106>

1. Introduction

Edward H. Angle [1] introduced the edgewise appliance and presented numerous case reports that supported its efficacy. Charles H. Tweed [2] identified his orthodontic treatment objectives, and presented modifications in both the edgewise appliance and its use. Anchorage preparation was the cornerstone of Tweed's treatment. He prepared anchorage with coordinated bends in the mandibular arch wire, Class III elastics, and maxillary headgear.

L. Lavern Merrifield [3, 4] enhanced, expanded and simplified Tweed's concepts and treatment mechanics. He developed force systems that simplify the use of the edgewise appliance. Directional forces can be defined as controlled forces that place the teeth in the most harmonious relationships with their environment.

A hallmark of Tweed-Merrifield edgewise treatment is the use of directional force systems to control the mandibular anterior and posterior teeth and the maxillary anterior teeth. The resultant vector of all orthodontic forces should be counterclockwise so that the opportunity for a favorable skeletal change is enhanced particularly for dentoalveolar protrusion and Class II malocclusion corrections. Such an upward and forward force system requires that the mandibular incisors be upright over basal bone so that the maxillary incisors can be moved distally and superiorly. For the upward and forward force system to be a reality, vertical control is critical. To control the vertical dimension, the clinician must control the mandibular plane, the occlusal plane, and the palatal plane. If Point B drops down and back, the face becomes lengthened, the mandibular incisor is pushed forward off the basal bone, and the maxillary incisor drops down and back instead of being moved up and back [5, 6].

Vertical control is the key to successful orthodontic treatment. The control of the horizontal movement of the dentition depends on how the vertical dimension of the maxillomandibular

complex is controlled. Vertical control can make horizontal correction possible [7]. This might be the single most important mechanical consideration that has to be accomplished during the treatment of the patient with a high angle Class II malocclusion. Successful correction of various orthodontic problems depends on the control of the horizontal planes, particularly the occlusal plane. The occlusal plane is the key to counterclockwise rotation of the horizontal planes. The clinician should control extrusion of the maxillary and mandibular posterior teeth, and control anterior vertical dimension, particularly the maxillary anterior segment [8] during mechanotherapy to maintain or close the occlusal plane. A large increase in horizontal mandibular response for Class II correction, chin enhancement, and Z-angle improvement can be achieved by vertical control [9].

Tweed-Merrifield directional force technology is a very useful concept, particularly for the treatment Class I and Class II dentoalveolar protrusion malocclusions. It has contributed to creating a favorable counter-clockwise skeletal change and balanced face, while the headgear force, using high pull J-hook (HPJH) in an appropriate direction is also essential to influence such results. Although the headgear force using HPJH in an appropriate direction can be used to provide directional forces and stable anchorage, a high degree of patient compliance is required. Clinicians have encountered some problems concerning patient compliance; however, skeletal anchorage has been used widely because it does not necessitate patient compliance, yet produces absolute anchorage.

To obtain an absolute anchorage without patient cooperation, endosseous implants [10], miniplates [11], and screws [12-22] have been used as orthodontic anchorage. Of those, screws have many advantages such as ease of implantation and removal, low cost, possible immediate loading, and possible placement in most areas of the alveolar bone. Micro-implants are very effective in maintaining or closing the occlusal plane and mandibular plane with counterclockwise movement of the chin by vertical control of maxillomandibular complex.

The present new protocol demonstrates the usefulness of micro-implants as anchorage aid in Tweed-Merrifield directional force technology.

2. New protocol of directional force treatment using MIA – 4 steps

4 steps can achieve tweed-Merrifield Sequential Edgewise Directional Force Treatment: denture preparation, denture correction, denture completion, and denture recovery. During each step of the treatment, there are certain objectives that must be attained prior to initiating the next step.

1. Denture preparation

The first step of treatment is denture preparation. Each case is sequentially banded or bonded with a .22 non-tipped, non-torqued appliance. Sequential banding allows the operator to use edgewise archwire at the outset of treatment. The use of the edgewise archwire enhances control of tooth movement as well as the leveling and the distal tipping of the terminal molar.

During canine retraction, anchorage has always been a major concern for the orthodontist, especially in those cases in which maximum anchorage is needed. Maxillary and mandibular posterior micro-implants (MIs) are installed and elastomers are applied for maximum retraction of canines and anchorage preparation of the terminal molars (Figure 1.A). At the end of the denture preparation step of treatment, the mandibular arch should be leveled, the maxillary and mandibular canines should be retracted, all rotations should be corrected, and the mandibular terminal molars should be tipped distally into an anchorage prepared position of approximately 15° (Figure 1.B).

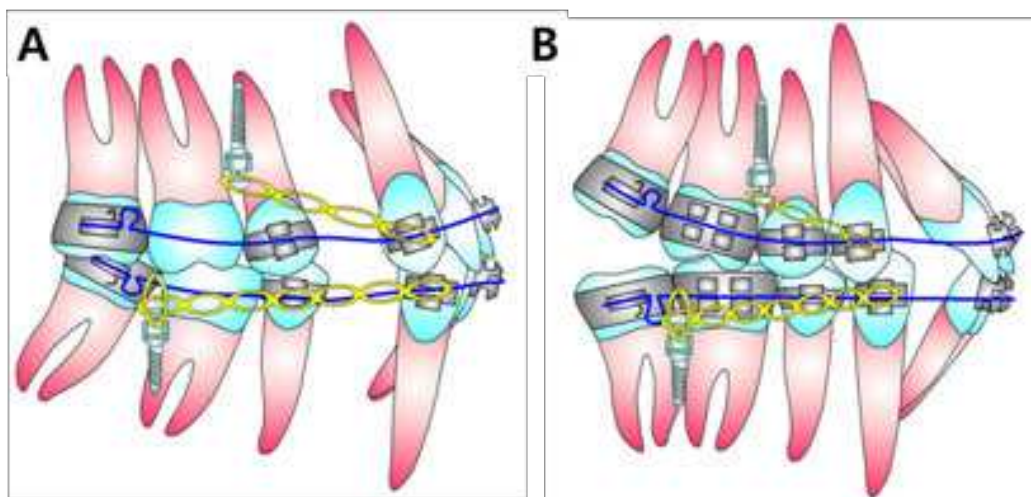


Figure 1. A. Denture preparation : An $.022 \times .028''$ edgewise appliance is sequentially placed. $.017 \times .022''$ maxillary and $.018 \times .025''$ mandibular archwires are inserted. Maxillary and mandibular posterior micro-implants, and elastomers are applied to the canine brackets and mandibular archwire just mesial to omega stop loop. **B. End of denture preparation :** The arches are leveled, the rotations are corrected, the canines have been retracted, and the mandibular terminal molar has been tipped to an anchorage prepared position.

2. Denture correction

The second step of treatment is denture correction. During denture correction, spaces are closed with maxillary and mandibular closing loops which are supported by maxillary anterior micro-implants and elastomers attached to the soldered hooks or main archwire between the maxillary centrals and laterals for control of vertical dimension and torque of the maxillary anterior segment. During en masse retraction of anterior teeth, vertical and horizontal anchorage loss of posterior teeth can be prevented by maxillary and mandibular posterior micro-implants (Figure 2.A).

During en masse retraction of anterior teeth, both arch should be leveled with maintenance of compensating curve in maxillary arch and 15° distal tip of the mandibular second molar (Figure 2.B).

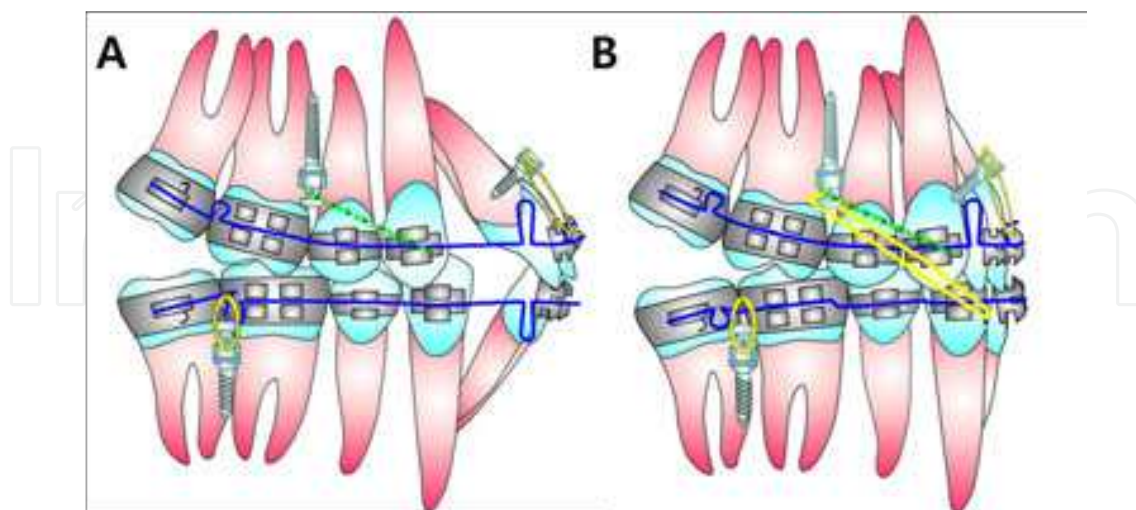


Figure 2. A. Denture correction : A mandibular $.019 \times .025''$ closing loop archwire and a maxillary $.020 \times .025''$ closing loop archwire are fabricated. Maxillary and mandibular posterior micro-implants and elastomers are attached to hooks, brackets and archwires. **B. Mandibular anchorage preparation**: First molar Anchorage preparation : The $.019 \times .025''$ mandibular archwire biases the first molar bracket at a 10° angle. Second premolar anchorage preparation : A compensation bend is placed mesial to the mandibular first molar and an anchorage bend of 5° is placed 1mm mesial to the second premolar bracket. Mandibular anchorage preparation is supported by Class III elastics between maxillary posterior micro-implants and anterior hooks in mandibular archwire and/or elastomers between mandibular posterior micro-implants and mandibular archwire just mesial to omega stop loop.

After space closure, mandibular anchorage is sequentially prepared. This sequential anchorage preparation was initiated by tipping the terminal molar during denture preparation and is continued after space closure by tipping the first molar and second bicuspid.

Each tooth is moved individually into its anchorage prepared position with Class III elastics between maxillary posterior micro-implants and mandibular anterior hooks between mandibular lateral incisors and canines. During anchorage preparation, elastomers are applied on the mandibular posterior dental segment to prevent extrusion of mandibular posterior teeth and to encourage counterclockwise mandibular rotation.

At the end of denture correction, space closure in both arches, sequential anchorage preparation in the mandibular arch, enhanced curve of occlusion in the maxillary arch and Class I relationship should be accomplished.

3. Denture completion

The third step of treatment is denture completion. During this step of treatment, the idealization and finishing of the case is done with elastics attached to cusp seating spurs soldered to archwires with the proper first, second and third order bends (Figure 3.A and 3.B).

At the end of denture completion, well alignment, tight closure of all space, overcorrection to a Class I relationship, Tweed occlusion (slight out of occlusion on the distal cusps of the first molars and second molars) should be accomplished.

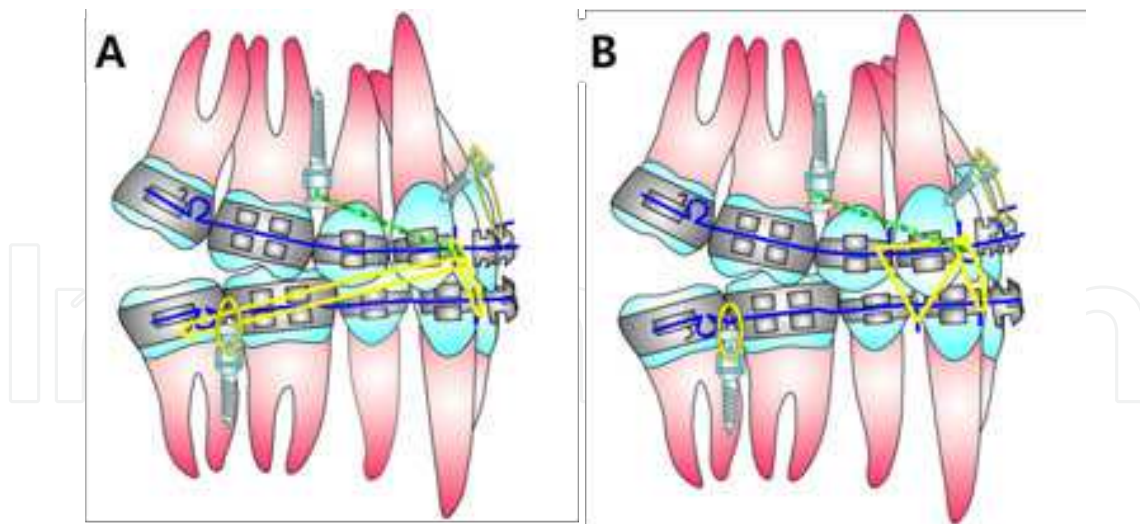


Figure 3. Denture completion: A. Class II elastics, anterior vertical elastics, and micro-screw implants and elastomeric threads or chains are used for directional force control. B. Maxillary and mandibular.0215 x.028" archwires are fabricated. Hooks are soldered for the use of micro-implants and elastomeric threads or chains, cusp seating and anterior vertical elastics. The force system used depends on final tooth positions that need to be achieved.

4. Denture recovery

At the end of the denture completion stage of treatment, the appliances are removed, and Tweed occlusion, anchorage prepared positions of the mandibular posterior teeth, and a gentle curve of Spee in the maxillary arch exists (Figure 4.A). As time goes by, functional forces place the teeth into a beautiful inter-digitation (Figure 4.B).

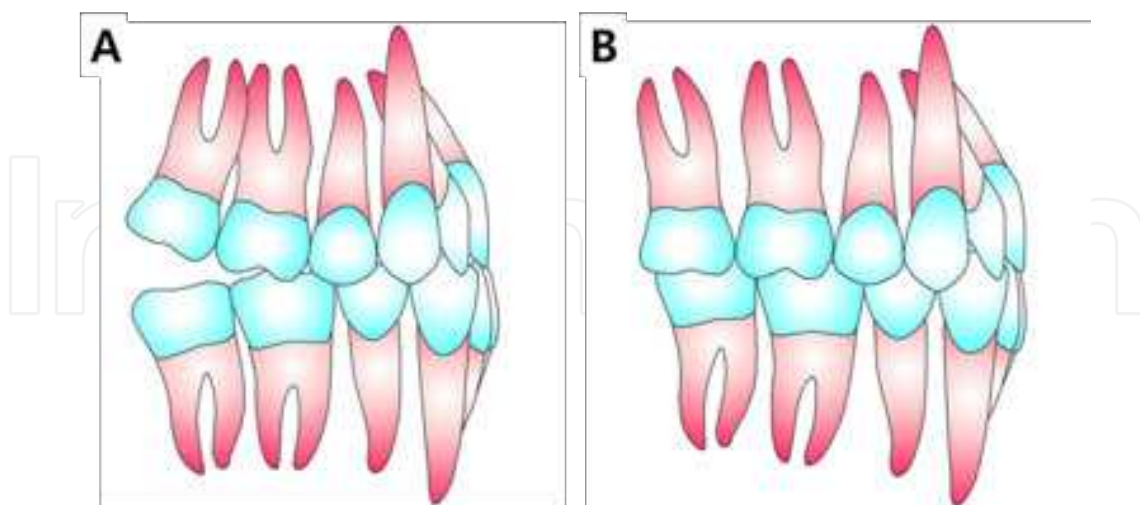


Figure 4. Denture recovery: A. Tweed post-treatment occlusion. Note the distal inclination of the maxillary and mandibular second molars. The maxillary first molar occludes with its mesial buccal cusp in the mesial buccal groove of the mandibular first molar. The canines are in an ideal Angle Class I relationship. The overjet and overbite have been overcorrected. B. Functional occlusion. Settling places both the maxillary and mandibular posterior and anterior teeth into their ideal occlusal relationships.

3. Case report

3.1. Case 1. skeletal class II with lip protrusion, gummy smile and asymmetry [18]

3.1.1. Diagnosis

A 23-year old woman presented with the chief complaints of lip protrusion and gummy smile. She showed a convex profile with marked protrusion of the lips and retrognathic mandible, mentalis strain, excessive lower anterior facial height, facial asymmetry and gummy smile. Intraorally, she had a Class I relationship with minor crowding and anterior edge-to-edge bite; all third molars were present (Figure 5 and Figure 6).

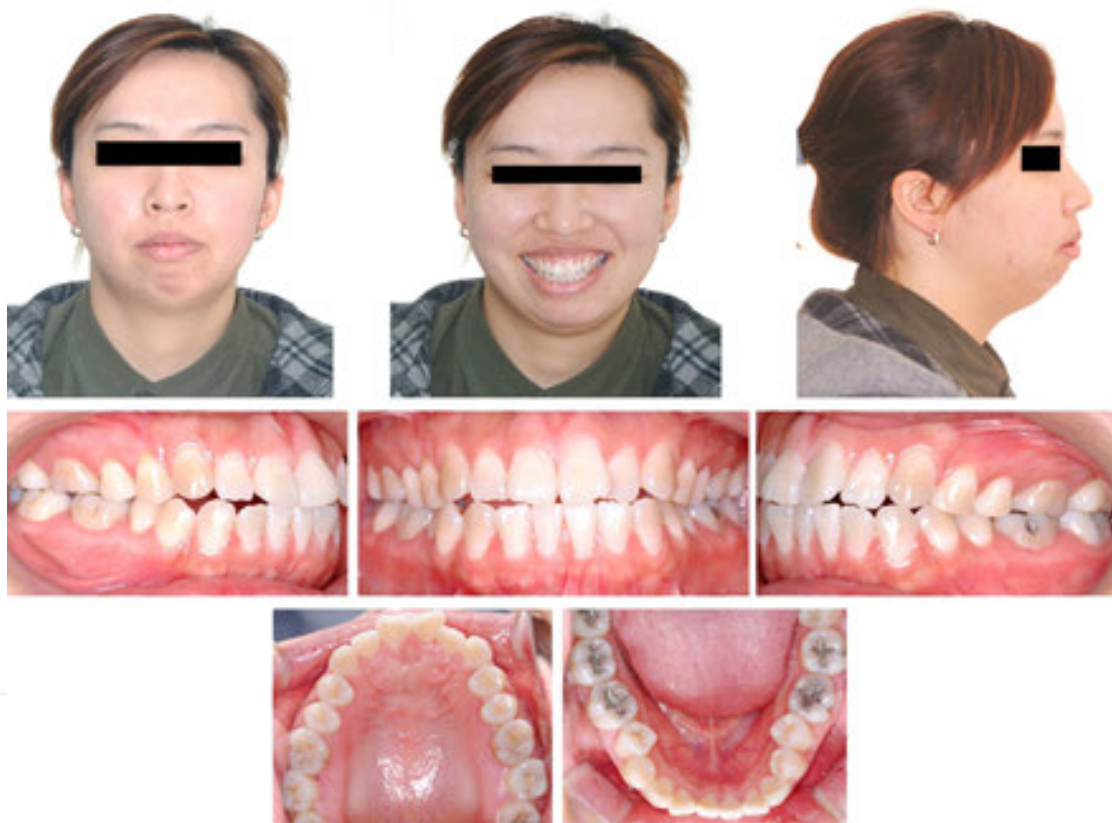

Figure 5. Pretreatment facial and intraoral photographs. (Case 1)

The lateral cephalometric radiograph showed severe facial and skeletal problems (Figure 7). The skeletal pattern was hyperdivergent as indicated by the Frankfort mandibular plane angle (FMA) of 32.0° and the facial height index (FHI) of 65.0%. The ANB angle of 5.5° reflected the class II skeletal problem and the occlusal plane angle of 13.5° showed vertical dental problem. The FH/U1 of 115.5° indicated the normal inclination of upper incisors, and the incisor–mandibular plane angle (IMPA) of 100.5° reflected the proclination of the lower incisors. The Z-angle of 53.0° was a measure of the facial imbalance (Table 1). The posteroanterior cephalogram showed skeletal asymmetry with canting of the maxilla and a deviation of the chin to

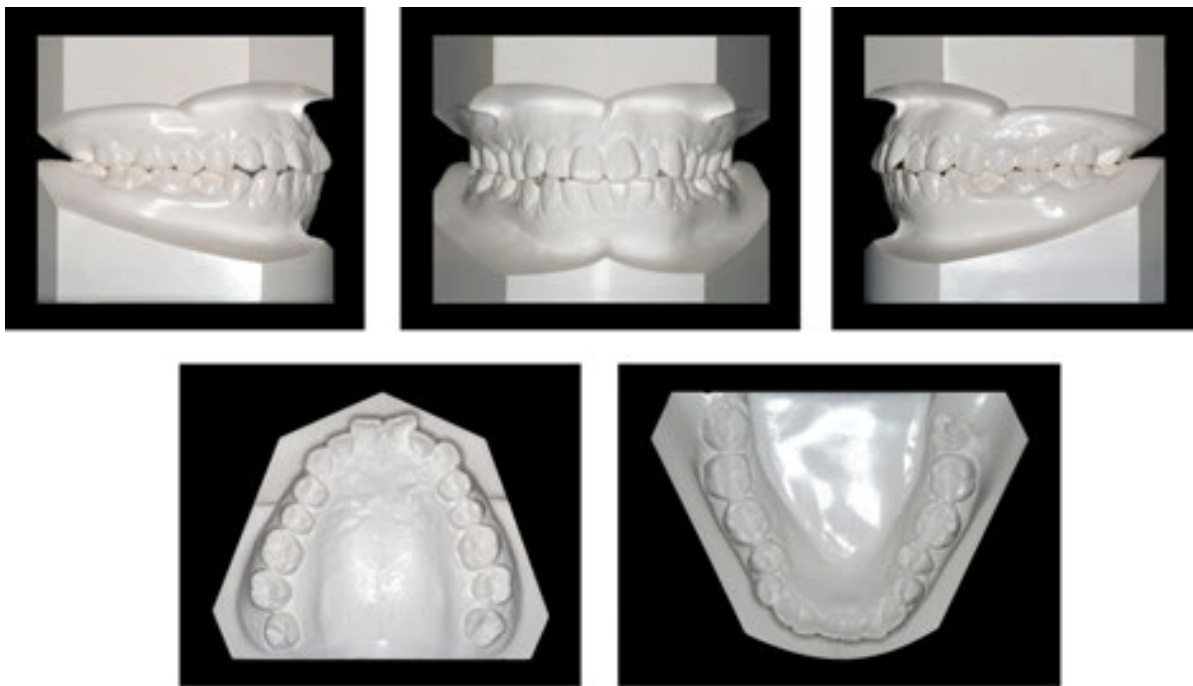

Figure 6. Pretreatment dental casts. (Case 1)

the left, and dental asymmetry with deviation of the upper dental midline to the left of facial midline and 1-mm deviation of the lower dental midline to the left of upper dental midline (Figure 8). The patient was in good general health with no signs or symptoms of temporomandibular dysfunction.

	Pretreatment	Post-treatment
FMIA (°)	47.5	60.0
FMA (°)	32.0	29.5
IMPA (°)	100.5	90.5
SNA (°)	83.0	82.0
SNB (°)	77.5	78.0
ANB (°)	5.5	4.0
AO-BO (mm)	-1.5	1.0
Occlusal plane angle (°)	13.5	7.0
FH to U1(°)	115.5	112.0
Z angle (°)	53.0	67.5
PFH	48.0	48.0
AFH	73.5	71.5
FHI (PFH/AFH) (%)	0.65(48.0/73.5)	0.67(48.0/71.5)

Table 1. Cephalometric measurements (Case 1)

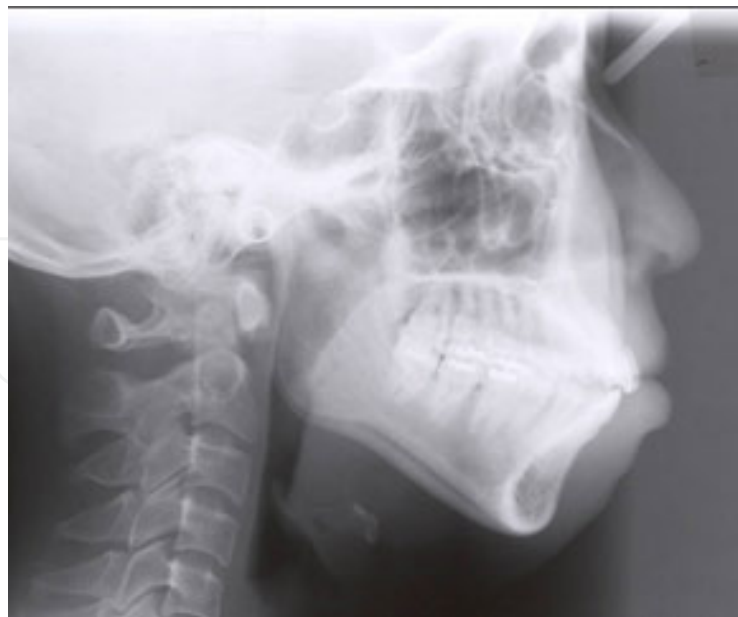

Figure 7. Pretreatment lateral cephalometric radiograph. (Case 1)

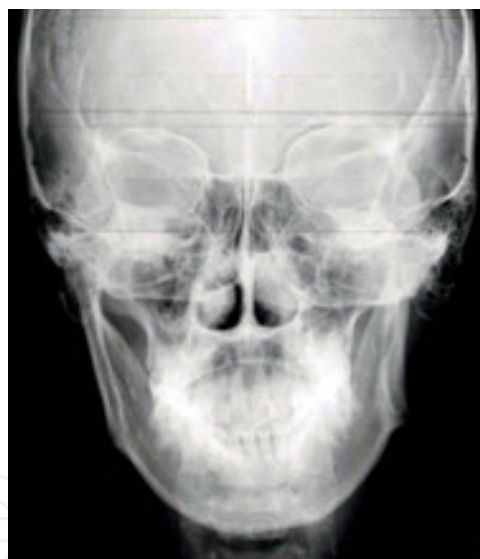

Figure 8. Pretreatment posteroanterior cephalometric radiograph. (Case 1)

3.1.2. Treatment alternatives

The first treatment plan was orthognathic surgery. Extraction of the maxillary second premolars and the mandibular first premolars would be done to resolve the arch-length discrepancy and upright the mandibular anterior teeth. Following this, two jaw surgeries with genioplasty would be necessary for mandibular advancement, reduction of lower anterior facial height and correction of asymmetry. However, the patient not want to undergo orthognathic surgery, therefore another treatment plan was needed.

The second treatment plan was orthodontic camouflage treatment with removal of the four first premolars and four 3rd molars using MIA to achieve a balanced facial profile.

3.1.3. Treatment progress

Before treatment, the mandibular second premolars were inadvertently extracted instead of the mandibular first premolars by an oral surgeon. However, that did not prove to be problematic since our plan was to use micro-implant anchorage (MIA).

.022 × .028-in nontipped, nontorqued standard edgewise appliances were placed in both arches after extraction. Maxillary posterior MIs (1.2 mm in diameter, 8 mm in length; Absoanchor AX12-108, Dentos, Taegu, South Korea) were installed into the buccal alveolar bone between the maxillary second premolars and the first molars, and mandibular posterior MIs (1.2 mm in diameter, 7 mm in length; Absoanchor ATX 1311-107, Dentos) were installed into the buccal alveolar bone between the mandibular first and second molars. Then, elastomers were placed immediately after installation of the MIs, from the maxillary and mandibular posterior MIs to the canine brackets for retraction of the maxillary canines and simultaneously retraction of the mandibular canines and first premolars (Figure 9.A).

Following the retraction of canines and first premolars, closing loop archwires were placed on both arches. Maxillary anterior MIs (1.2 mm in diameter, 6.0 mm in length; Absoanchor ATX1311-106, Dentos) were installed into the labial alveolar bone between the maxillary central and lateral incisors and elastomers were placed for torque control, bodily movement, and intrusion of the maxillary anterior teeth. Elastomers were also placed to the omega stop areas of the mandibular archwire for intruding mandibular posterior teeth (Figure 9.B).

After en-masse retraction of anterior teeth, directional force was applied to achieve mandibular response (Figure 9.C). Ideal archwires were inserted and elastomers were placed for finishing the treatment (Figure 9.D). Fixed lingual retainers were placed on the six anterior teeth and circumferential clear retainers were placed on both arches for retention. Total treatment period was 24 months.

3.1.4. Treatment results

After treatment, she showed a nicely balanced and harmonious face by retracting lips, reducing the mentalis strain, and reducing lower anterior facial height. Excessive gingival display when smiling was successfully reduced by intruding the maxillary anterior segment (Figure 10). Dentally, a good interdigitation of the teeth and acceptable overjet-overbite relationship were achieved (Figure 11). The postero-anterior cephalometric radiograph showed improvement in skeletal and dental asymmetry (Figure 12).

Cephalometric superimposition showed the bodily retraction with intrusion of the maxillary anterior teeth, intrusion and distal movement of the maxillary posterior teeth, retraction with uprighting of the mandibular anterior teeth, and uprighting with intrusion of the mandibular posterior teeth. A good mandibular response with chin advancement was achieved by the counterclockwise autorotation of the mandible caused by vertical control of dentition (Figure

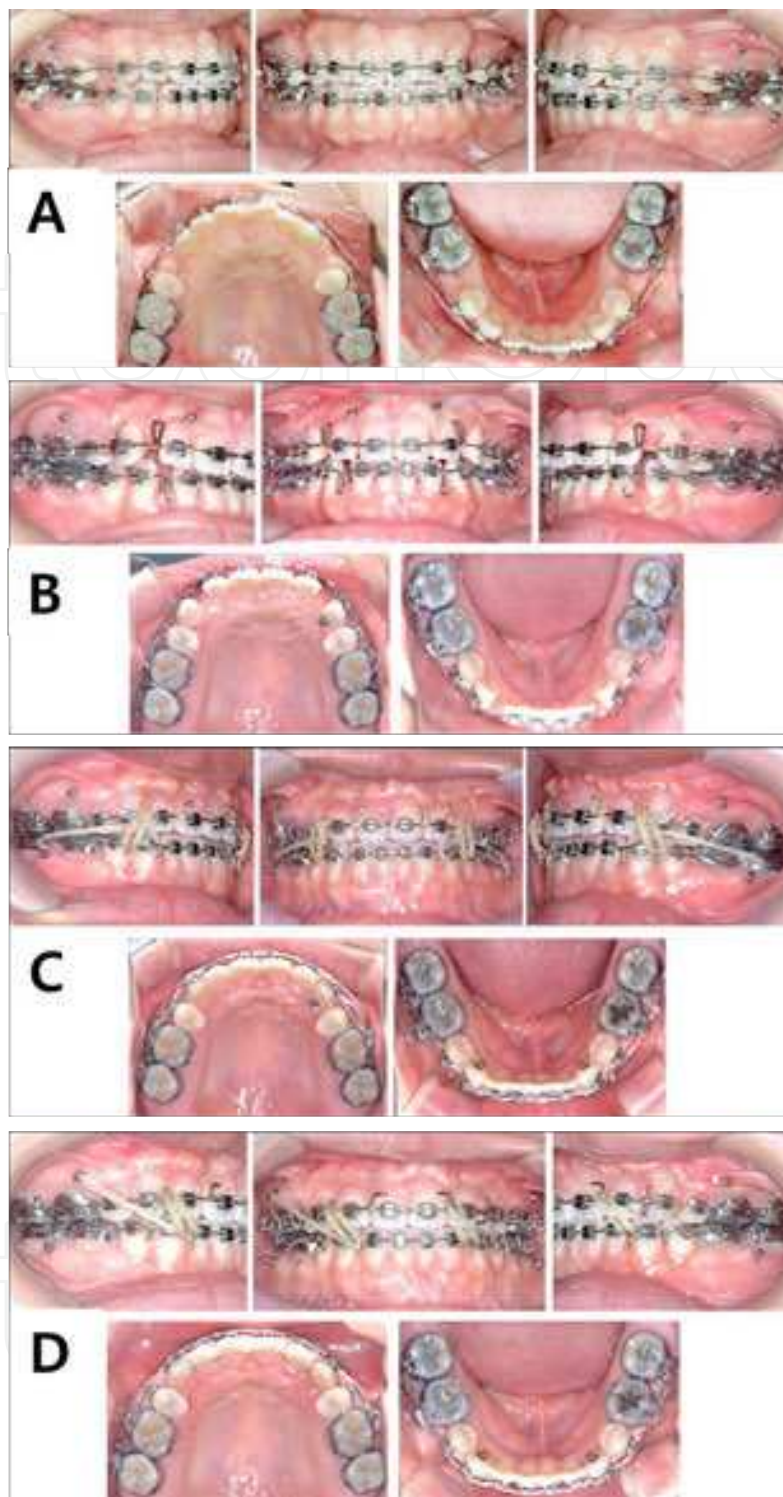

Figure 9. A. Denture preparation: retraction of maxillary and mandibular canines and first premolars with elastomeric chain, and maxillary and mandibular posterior MIs. B. Denture correction: en-masse retraction with closing loop archwires supported by maxillary posterior and anterior MIs and mandibular posterior MIs. C. Denture completion: directional force. D. Denture completion: finishing with cusp-seating elastics for good interdigitation and additional unilateral Class III elastics for correction of asymmetry. (Case 1)

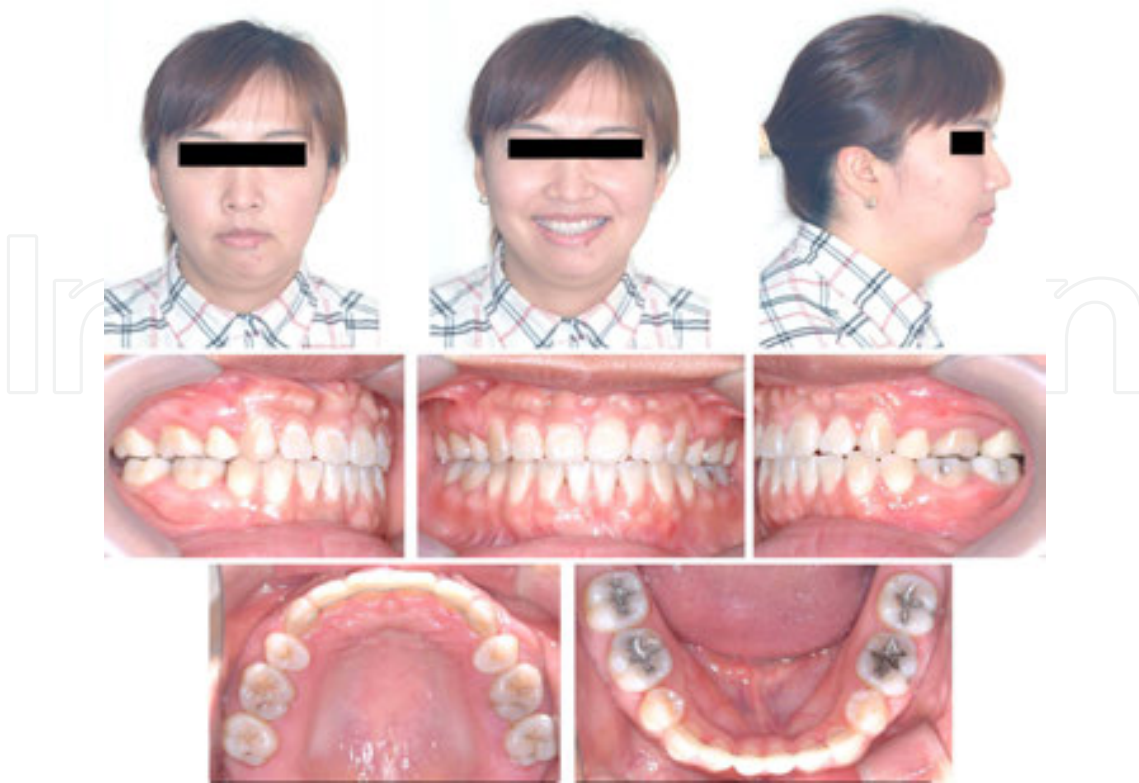

Figure 10. Post-treatment facial and intraoral photographs. (Case 1)

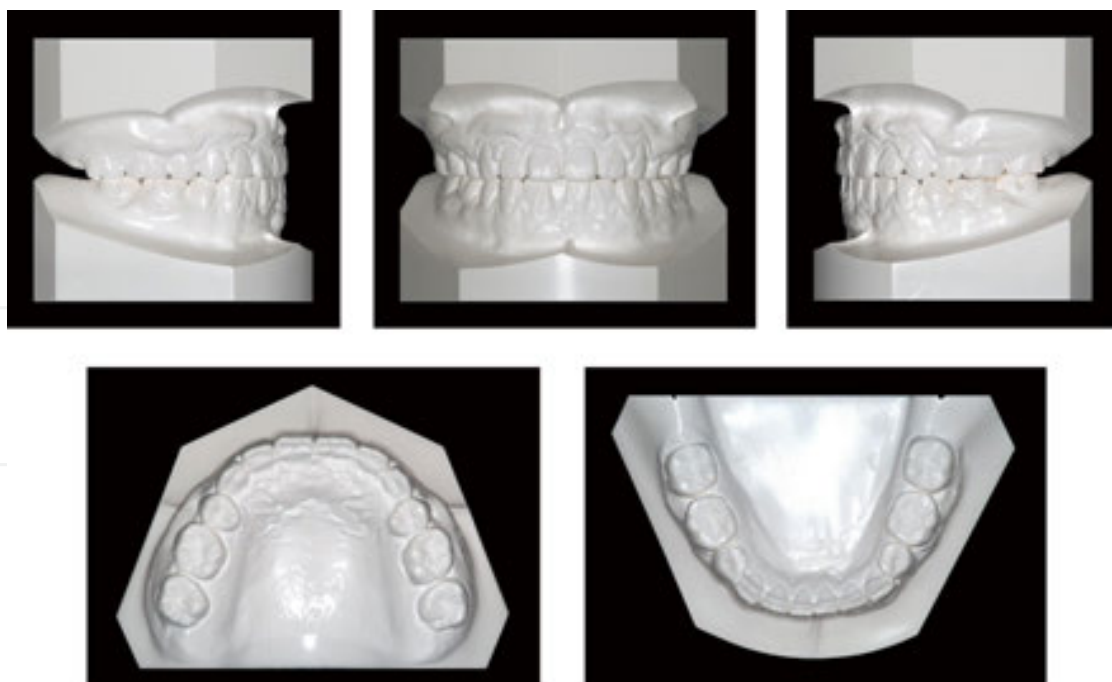

Figure 11. Post-treatment dental casts. (Case 1)

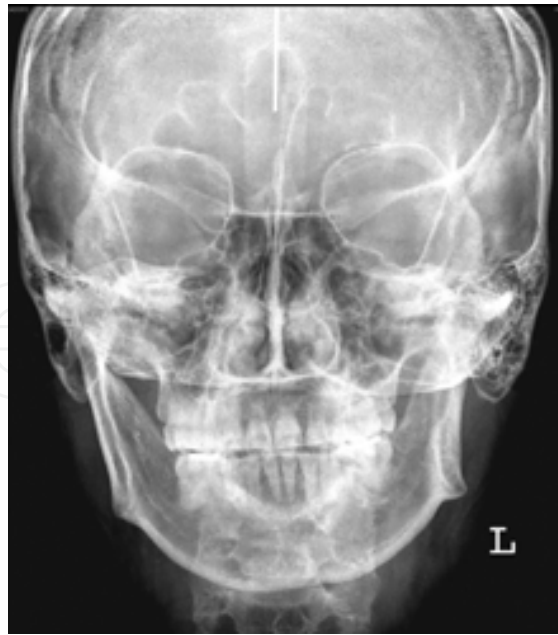

Figure 12. Post-treatment lateral cephalometric radiograph. (Case 1)

13). As a result of vertical control, the FMA, ANB angle, occlusal plane angle, and anterior facial height were reduced by 2.5°, 1.5°, 6.5°, and 2mm, respectively. The IMPA and was reduced by 10° and the Z-angle was increased by 14.5° (Table 1). All of the above changes resulted in significant improvement of the facial profile.

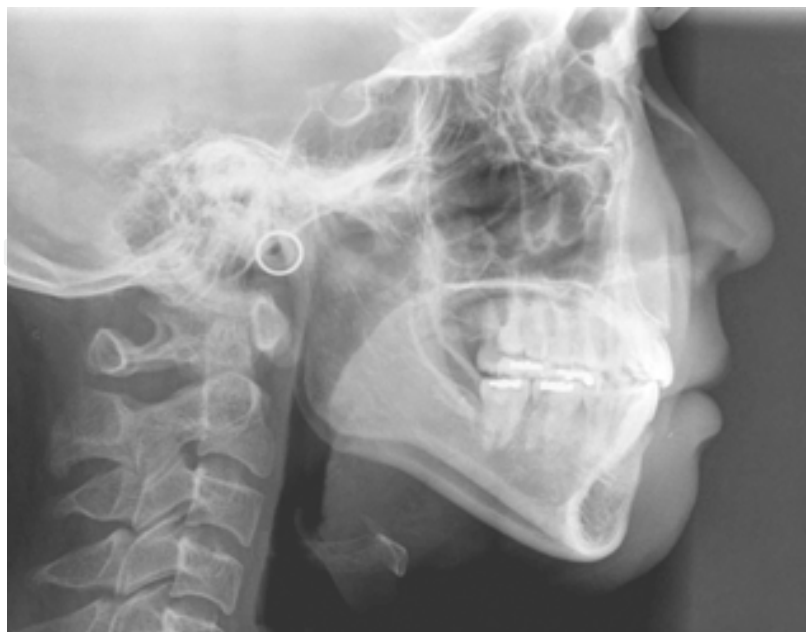

Figure 13. Post-treatment posteroanterior cephalometric radiograph. (Case 1)

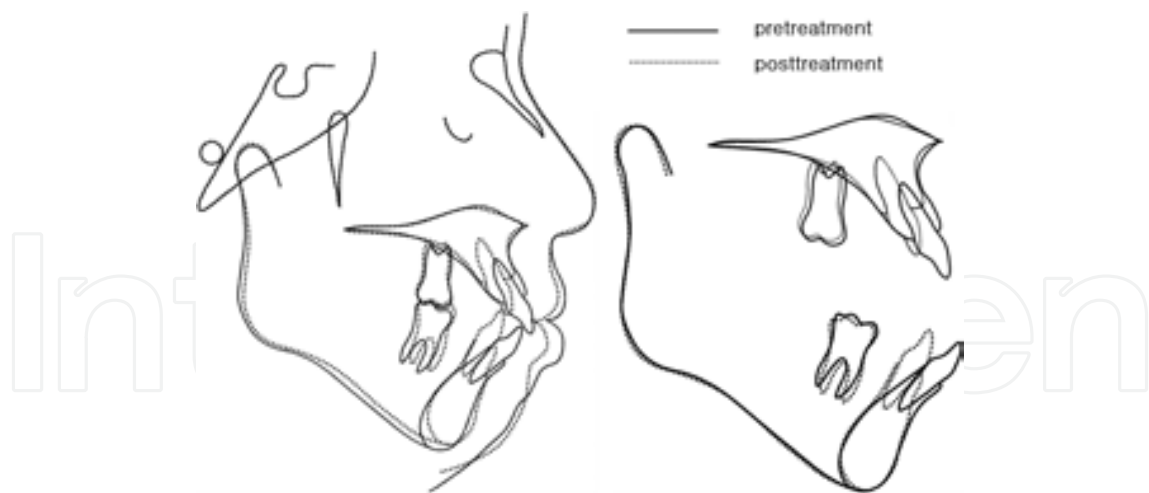


Figure 14. Cephalometric superimposition. (Case 1)

3.2. Case 2. skeletal class II with lip protrusion and nasal airway obstruction [21]

3.2.1. Diagnosis

A 22-year-old male presented with the chief complaints of lip protrusion and difficulty in nasal breathing. Facially, he showed a convex profile with marked protrusion of the lips and retrognathic mandible, mentalis strain, excessive lower anterior facial height and a typical “adenoid face”. He had a Class I relationship with moderate crowding, severe constricted “V” shaped arch forms of both jaws, an anterior open bite, several restorations on the posterior teeth; upper left and lower right third molars were present (Figure 15 and Figure 16).

	Pretreatment	Post-treatment	13-month retention
FMIA (°)	53.5	73.0	71.5
FMA (°)	33.5	30.5	32.0
IMPA (°)	93.0	76.5	76.5
SNA (°)	84.0	83.0	83.0
SNB (°)	79.5	80.0	79.5
ANB (°)	4.5	3.0	3.5
AO-BO (mm)	-2.0	-1.0	-1.5
Occlusal plane angle (°)	10.0	8.0	10.0
FH to U1(°)	112.0	103.0	98.0
Z angle (°)	51.5	61.5	60.5
PFH	54.5	57.5	57.0
AFH	91.0	88.0	89.0
FHI (PFH/AFH) (%)	0.61(54.5/91.0)	0.65(57.5/88.0)	0.64(57.0/89.0)

Table 2. Cephalometric measurements (Case 2)

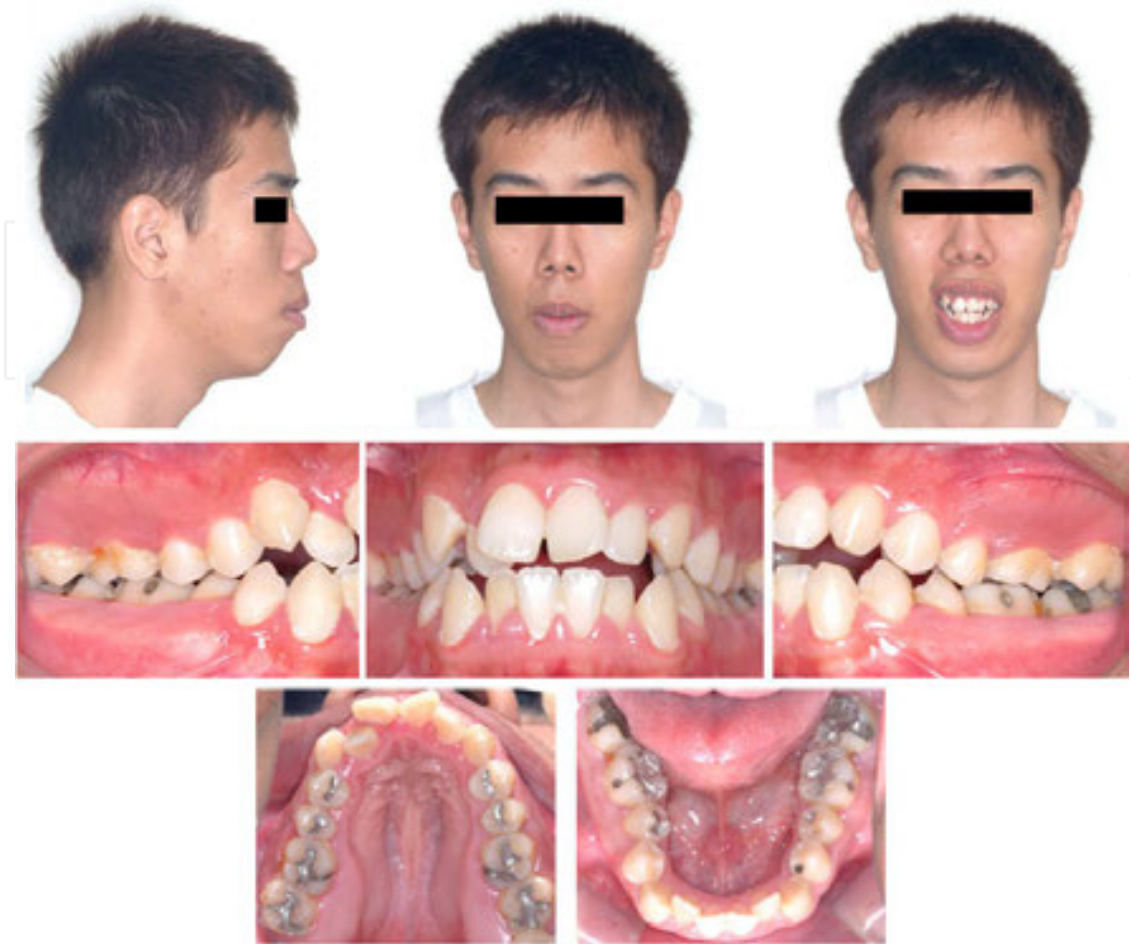

Figure 15. Pretreatment facial and intraoral photographs. (Case 2)

The lateral cephalometric radiograph showed severe facial and skeletal problems (Figure 16). The skeletal pattern was hyperdivergent and Class II as indicated by the FMA of 33.5° , the FHI of 61% and the ANB angle of 4.5° . The FH/U1 of 112.0° and the IMPA of 93.0° indicated the normal inclination of upper and lower incisors. The Z-angle of 51.5° was a measure of the facial imbalance (Table 2). The posteroanterior cephalogram showed a dental midline deviation of 2 mm to the left to the maxillary dental midline which was coincident to the facial midline and slight canting of the maxilla and transverse constriction of both arches (Figure 16). The patient was in good general health with no signs or symptoms of any temporomandibular disorders.

3.2.2. Treatment alternatives

The first treatment plan was orthognathic surgery. Expanding maxillary arch by surgical assisted rapid maxillary expansion (SARME) and mandibular arch by Schwarz appliance would be done to resolve the arch-length discrepancy and achieve normal arch form. Then, two jaw surgeries with genioplasty would be necessary for mandibular advancement and reduction of lower anterior facial height. However, the patient did not want to undergo orthognathic surgery so another treatment plan was chosen.

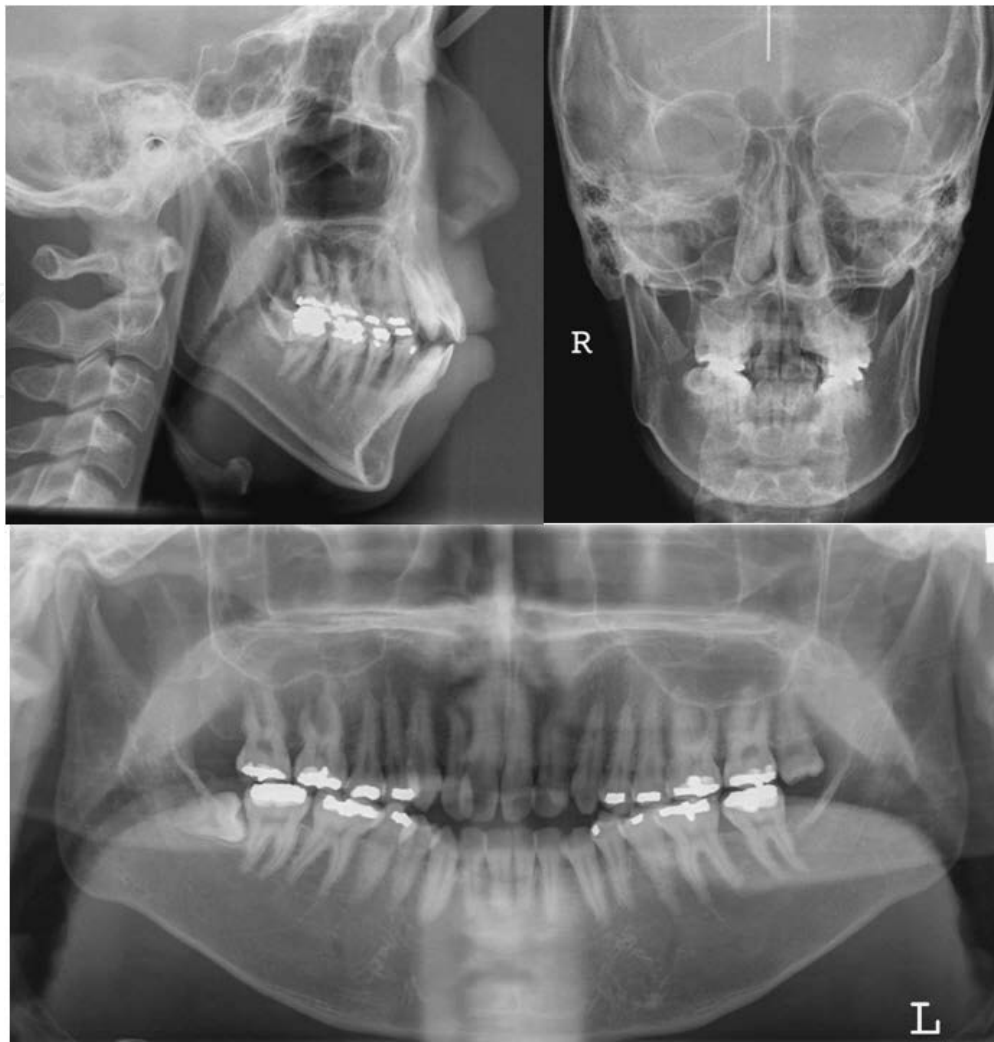


Figure 16. Pretreatment radiographs. (Case 2)

The second treatment plan was orthodontic camouflage treatment with expansion of the constricted upper and lower arches with SARME and Schwarz appliance, respectively, followed by orthodontic treatment with extraction of the four first premolars and all third molars using MIA. As mentioned previously [15], MIA can provide absolute anchorage for vertical control, which would induce a horizontal mandibular response resulting in a balanced facial profile.

3.2.3. Treatment progress

The treatment was divided into 2 phases. Phase I treatment was consisted of SARME in the maxilla and Schwarz appliance in the mandible (Figure 17). Schwarz appliance was activated once a week for about 5 months. SARME with Hyrax palatal expansion appliance cemented to the maxillary first molars and first premolars was activated two turns per day (0.5 mm) for 20 days and then 1 turn per week for a further 28 days until the desired level of expansion was achieved (Figure 18). After the desired expansion, a Hyrax palatal expander in the maxilla

remained in place for an additional 3.5 months during the completion of mandibular expansion (Figure 19).

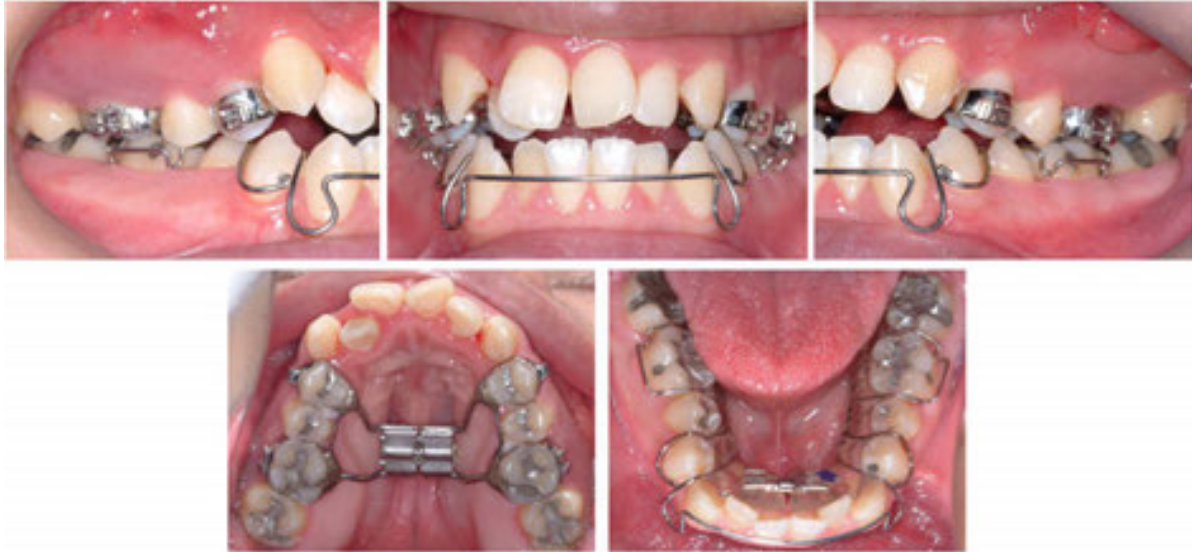

Figure 17. Surgical assisted rapid maxillary expansion on the maxilla and Schwarz appliance on the mandible. (Case 2)

The phase II treatment plan was consisted of Tweed- Merrifield directional force technology with MIA with extraction of four first premolars and two third molars. 0.022 × 0.028-in nontipped, nontorqued edgewise appliances were placed in both arches after the extractions. Maxillary posterior MIs (1.3 - 1.2 mm in diameter, 8 mm in length; Absoanchor SH1312-08, Dentos, Taegu, South Korea) were installed into the buccal alveolar bone between the maxillary second premolars and first molars, and the mandibular posterior MIs (1.3 - 1.2 mm in diameter, 7 mm in length; Absoanchor SH1312-08, Dentos) were installed into the buccal alveolar bone between the mandibular first and second molars. Elastomers were placed immediately after installation of the MIs, from the maxillary and mandibular posterior MIs to the canine brackets for retraction of the canines to level the six anterior teeth (Figure 20.A).

Two months into the treatment, 0.019 × 0.025-in stainless steel closing loop archwire was placed in the lower arch for en masse retraction of the six anterior teeth. Elastomers were applied from the mandibular posterior MIs to the omega loop areas of the mandibular archwire for intruding mandibular posterior teeth. Three months into the treatment, a 0.017 × 0.022-in stainless steel archwire was inserted and elastomers were placed from the maxillary MIs to the maxillary archwire for intrusion of the maxillary posterior teeth. Unilateral Class III elastomer was added from the maxillary posterior MIs to the right-side loop of the mandibular archwire for reduction of the dental asymmetry (Figure 20.B).

Four months into the treatment, 0.020 × 0.025-in stainless steel closing loop archwire was placed in the upper arch for en masse retraction of the six anterior teeth. At this time, maxillary anterior MIs (microimplants, 1.3 - 1.2 mm in diameter, 8 mm in length; Absoanchor SH1312-08, Dentos)

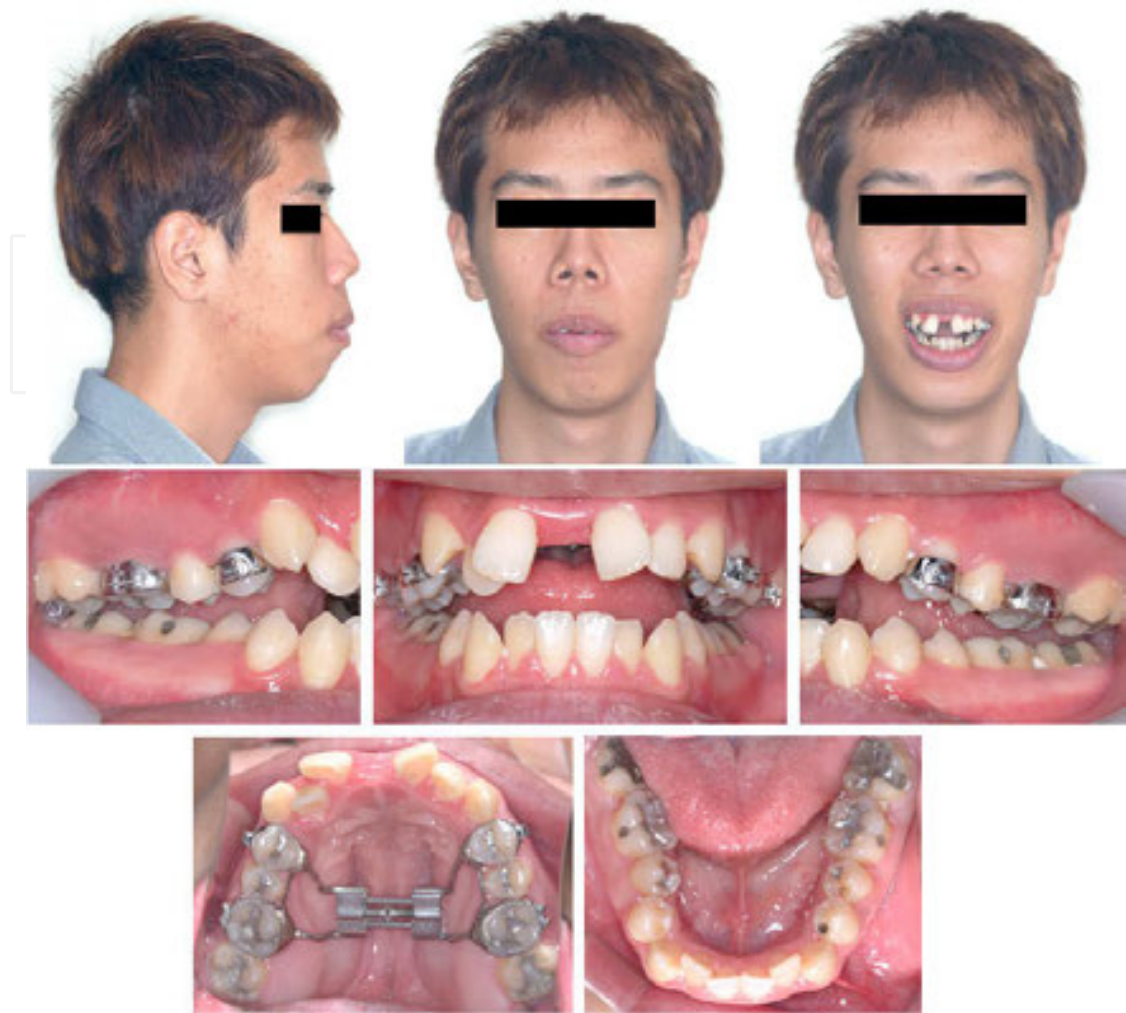

Figure 18. Photographs after 28-day expansion of the maxilla and mandible. (Case 2)

were installed into the labial alveolar bone between the maxillary central incisors for torque control, bodily movement and intrusion of the maxillary anterior teeth (Figure 20.C).

After en masse retraction, directional force was applied to achieve a mandibular response. Ideal archwires (0.020 × 0.025-in stainless steel archwire in the upper arch and 0.019 × 0.025-in stainless steel archwire in the lower arch) were inserted and elastomers were placed for finishing the treatment (Figure 20.D). Fixed lingual retainers were placed on the six anterior teeth and circumferential clear retainers were placed on both arches for retention. Total treatment period of phase II was 24 months.

3.2.4. Treatment results

After phase I treatment, considerable expansion on both arches was achieved in the anterior and posterior segments, which provided the space for dental alignment. The postero-anterior cephalometric radiograph showed a remarkable increase in transverse intermolar width (between the buccal surfaces of the first molar) by 10.0 mm after 1 month of expansion with

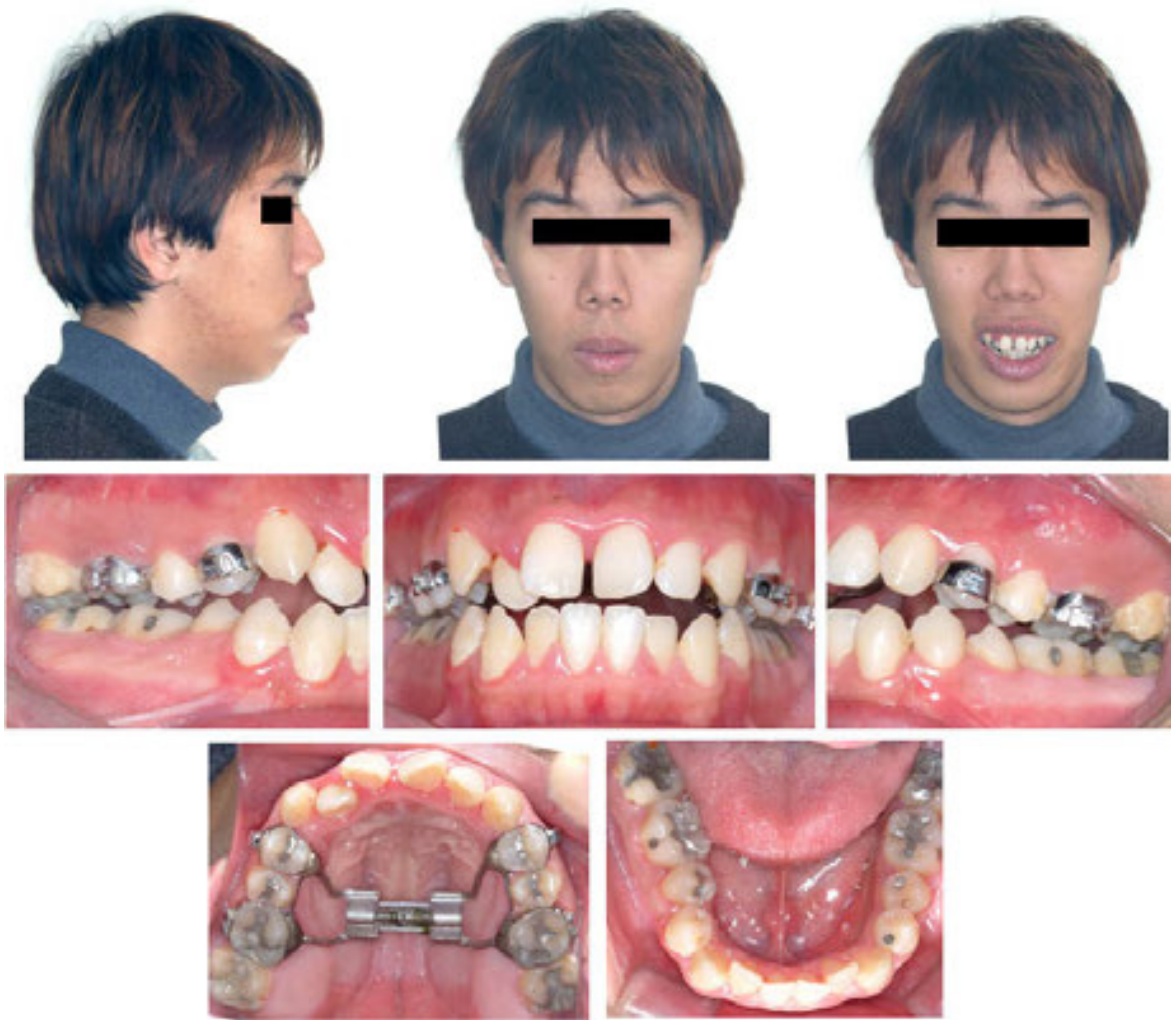

Figure 19. Photographs after 3.5 months of retention of the maxilla and 5 months of expansion of the mandible. (Case 2)

SARME in the maxillary arch and by 5.5 mm after 5 months of expansion with Schwarz appliance in the mandibular arch. Facially, he showed a slightly worsened appearance by the clockwise rotation of the mandible due to molar extrusion as a result of expansion of both arches. However, it was recovered during the retention period of phase I and he was pleased with the slightly peaceful looking facial appearance with easier nasal breathing.

After phase II treatment, he showed a well-balanced and harmonious face by retracting both upper and lower lips, reducing the mentalis muscle strain, and decreasing lower anterior facial height. Excessive gingival display during smiling was successfully reduced by intruding the maxillary anterior segment. Dentally, a good interdigitation of the teeth, acceptable arch form and a normal overjet-overbite relationship, and good overall root parallelism with no significant root resorption was achieved. The postero-anterior cephalometric radiograph showed relapse of transverse dimension of the maxillary intermolar width by 5.5 mm and an additional increase of the mandibular width by 3.5 mm (Figure 21 and Figure 22). After retention of thirteen months, he showed good retention without any obvious relapse (Figure 23).

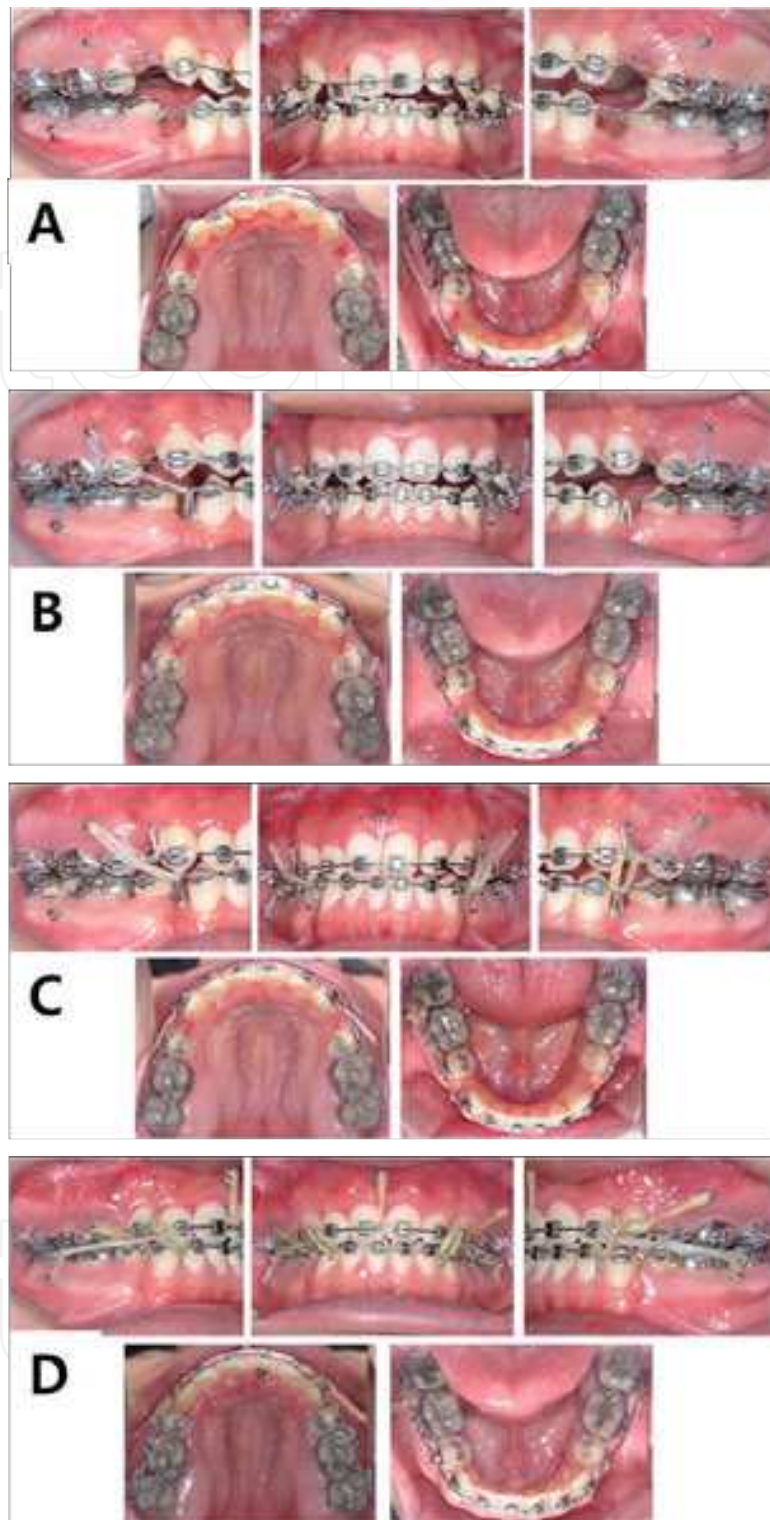


Figure 20. A. Denture preparation: retraction of the maxillary and mandibular canines to level six anterior teeth. (Case 2) B. Denture correction: en masse retraction with a closing loop archwire supported by mandibular posterior MIs, intruding forces with elastomeric chain between the main archwires and maxillary and mandibular posterior MIs, and unilateral Class III elastics to correct asymmetry. (Case 2) C. Denture correction: en masse retraction with closing loop archwire supported by maxillary posterior and anterior MIs. (Case 2) D. Denture completion: directional force and finishing with Class II and cusp seating elastics, and elastomeric chain and MIs. (Case 2)

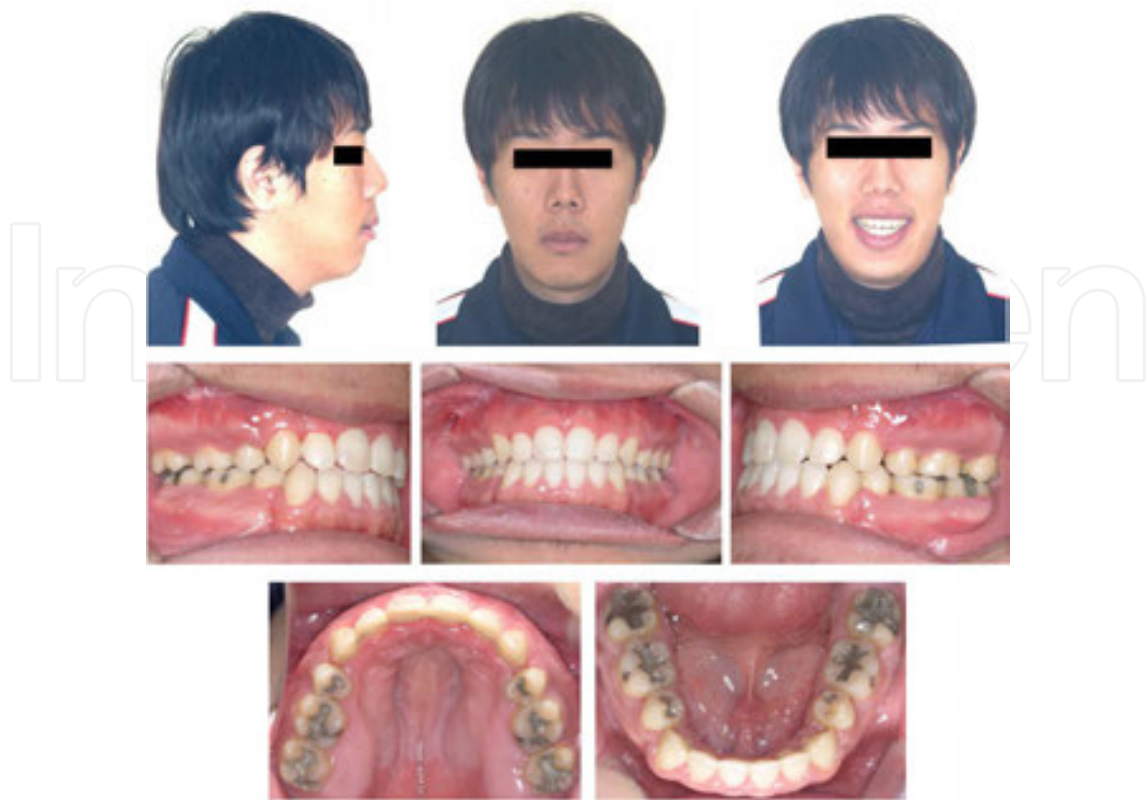

Figure 21. Post-treatment facial and intraoral photographs. (Case 2)

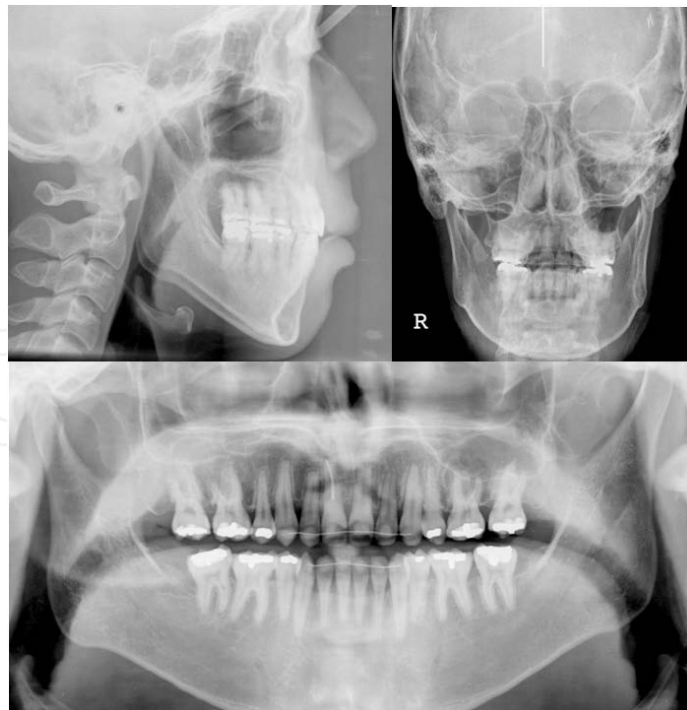


Figure 22. Post-treatment radiographs. (Case 2)

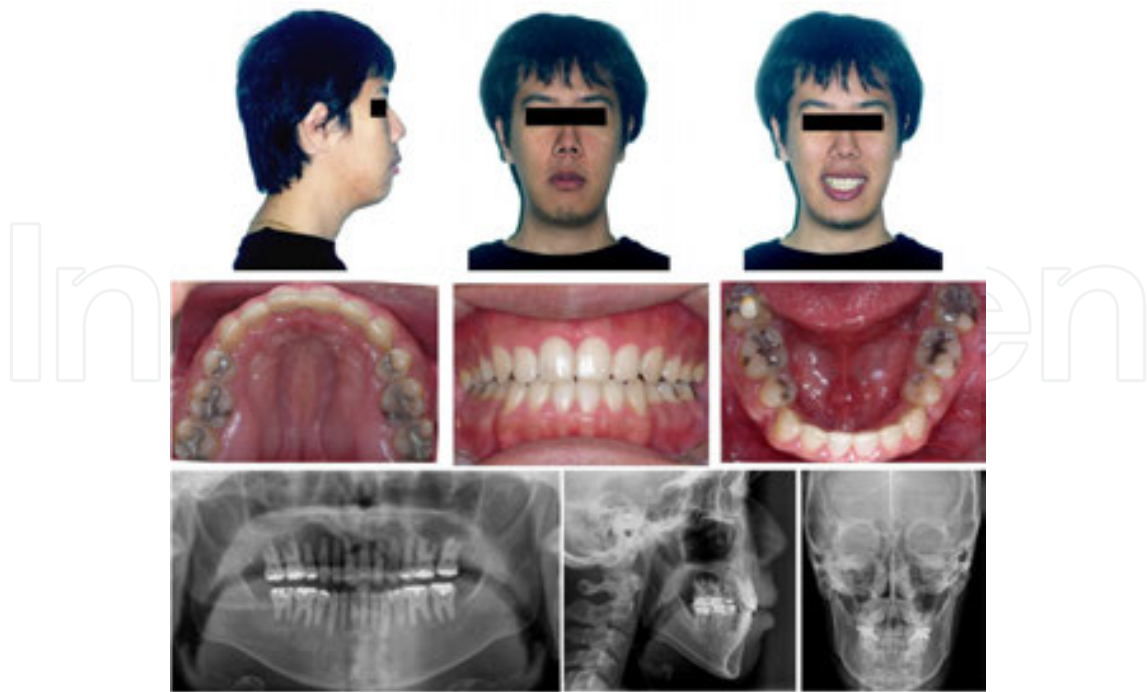

Figure 23. month retention photographs and radiographs. (Case 2)

Cephalometric superimposition showed the bodily retraction with intrusion of the maxillary anterior teeth, intrusion of maxillary posterior teeth, retraction with uprighting of mandibular anterior teeth and uprighting of mandibular posterior teeth. A good mandibular response with chin advancement was obtained by the counterclockwise autorotation of the mandible facilitated by vertical control of dentition (Figure 24.A). As a result of vertical control, the FMA, ANB angle, and anterior facial height were decreased by 3.0° , 1.5° and 3 mm, respectively. The IMPA was decreased by 16.5° and Z-angle was increased by 10° (Table 2). Facial profile was improved by all these changes.

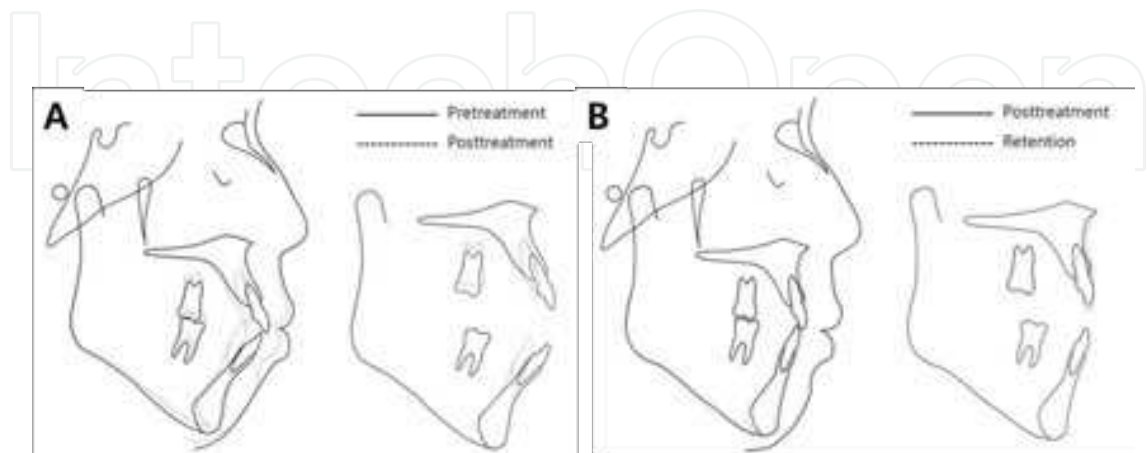


Figure 24. A. Pretreatment and post-treatment cephalometric superimposition; B. post-treatment and 13-month retention cephalometric superimposition. (Case 2)

After 13 months of retention, as a result of relapse due to extrusion of the maxillary anterior and posterior teeth, the FMA, ANB angle, and anterior facial height were increased by 1.5°, 0.5°, and 1 mm, respectively (Figure 24.B and Table 2).

3.3. Case 3. skeletal class II div.1 with lip protrusion, gummy smile and deep bite [16]

3.3.1. Diagnosis

A 13-year-old male presented with the chief complaints of lip protrusion and gummy smile. Facially, he exhibited a convex profile due to a retrognathic mandible. The facial photographs showed a convex facial profile with marked protrusion of the lips, mentalis strain and a gummy smile. Intraorally, he had Class II canine and molar relationships with slight crowding, "V" shaped arch forms of both jaws, an anterior deep bite, deep curve of Spee, caries and restoration on the posterior teeth; all third molars were present (Figure 25).

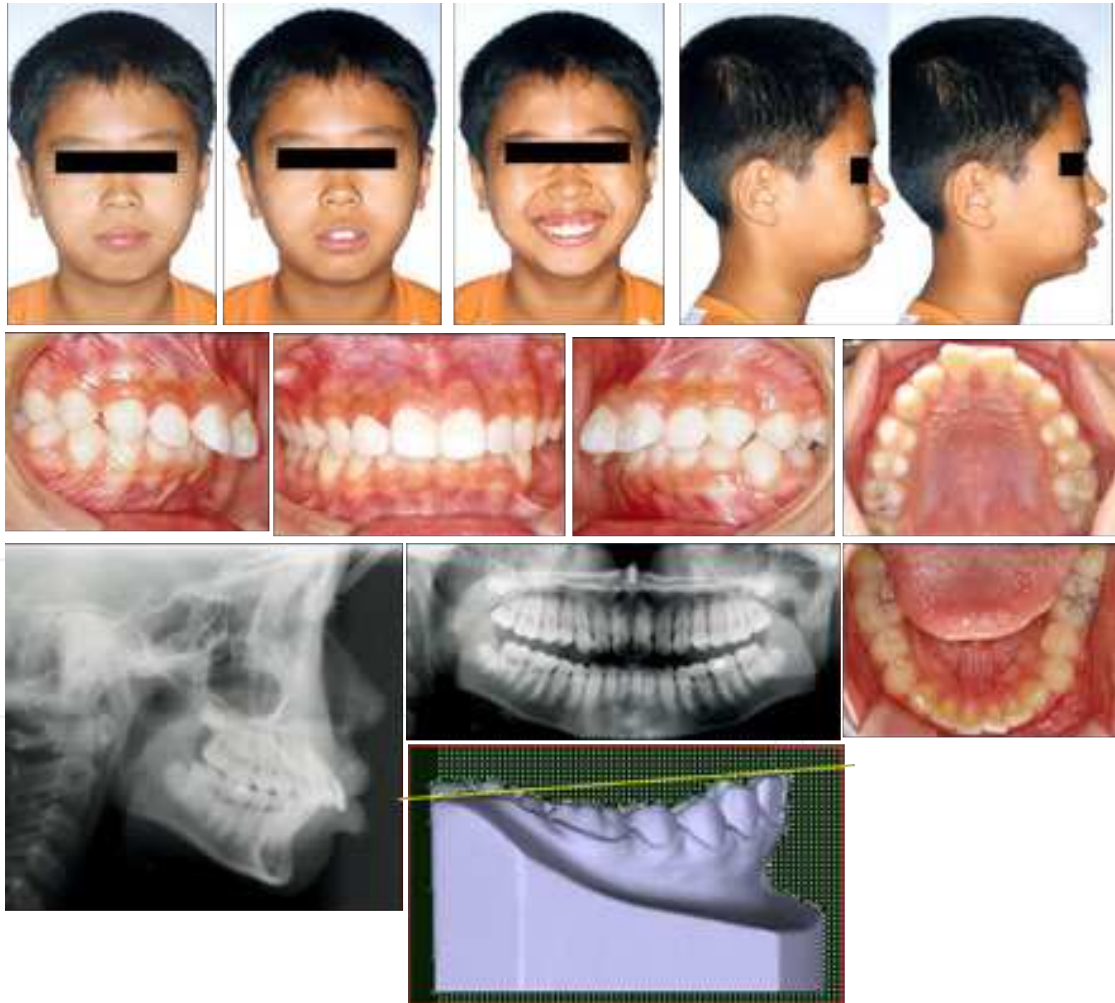


Figure 25. Pretreatment facial and intraoral photographs, mandibular cast, and cephalometric and panoramic radiographs. (Case 3)

The lateral cephalometric radiograph showed severe facial and skeletal problems (Figure 25). The skeletal pattern was hypodivergent and Class II as indicated by the FMA of 22.0° and the FHI of 71.0%, and the ANB angle of 6.5°. The Z-angle of 58.5° was a measure of the facial imbalance. The IMPA of 106.0° indicated severe protrusion of mandibular incisors (Table 3). There were no significant signs or symptoms of any temporomandibular disorders.

	Pretreatment	Post-treatment	30-month retention
FMIA (°)	52.0	60.0	57.5
FMA (°)	22.0	20.0	17.0
IMPA (°)	106.0	100.0	105.5
SNA (°)	83.5	81.5	82.0
SNB (°)	77.0	78.5	80.0
ANB (°)	6.5	3.0	2.0
AO-BO (mm)	5.0	2.0	1.0
Occlusal plane angle (°)	6.0	3.5	2.5
FH to U1(°)	124.5	121.5	122.5
Z angle (°)	58.5	78.0	79.0
PFH	44.0	48.5	53.5
AFH	62.0	65.5	68.0
FHI (PFH/AFH) (%)	0.71(44.0/62.0)	0.72(48.5/65.5)	0.79(53.5/68.0)

^a FMIA indicates angle between Frankfort plane and mandibular incisor axis; FMA, angle between Frankfort plane and mandibular plane; IMPA, angle between lower incisor axis and mandibular plane; SNA, angle between SN and NA; SNB, angle between SN and NB; ANB, difference between the SNA and SNB angles; AOBO, distance between perpendiculars drawn from point A and point B onto the occlusal plane; FH, Frankfort horizontal plane; UI, maxillary incisor axis; FH to UI, angle between Frankfort plane and maxillary incisor axis; Z angle, angle between FH and Z line; Z line, profile line tangent to the chin and the more anterior vermilion border of both lips; FHI, ratio of PFH to AFH; PFH, linear measurement from articulare, along a line tangent to the posterior border of the mandible, to the intersection with the mandibular plane; and AFH, linear measurement from palatal plane to menton, measured perpendicular to palatal plane.

Table 3. Cephalometric measurements (Case 3)

3.3.2. Treatment alternatives

The first alternative was orthodontic treatment with retraction and intrusion of the maxillary anterior teeth by using headgear for maximum anchorage after extraction of maxillary first premolars and mandibular second premolars. This approach can be used to reduce the patient’s lip protrusion, but it also depends considerably on patient cooperation.

The second alternative was orthodontic treatment with retraction and intrusion of the maxillary anterior teeth by using MIA and headgear for absolute and maximum anchorage after extraction of maxillary first premolars and mandibular second premolars, respectively.

The second option would provide good results with minimum patient compliance. Therefore, this treatment plan was chosen.

3.3.3. Treatment progress

The treatment plan involved Tweed-Merrifield directional force technology with MIA and HPJH, after the extraction of the maxillary first premolars and mandibular second premolars.

After the extractions, .022 × .028-in pre-adjusted appliances and .022 × .028-in nontipped, nontorqued edgewise appliances were placed in upper and lower arches, respectively. And leveling began with a .014-in nickel-titanium archwire and .018 stainless steel archwires. Maxillary posterior MIs (2.0 mm in diameter, 7 mm in length; Martin, Tuttlingen, Germany) were implanted into the buccal alveolar bone between the maxillary second premolars and the first molars (Figure 26).

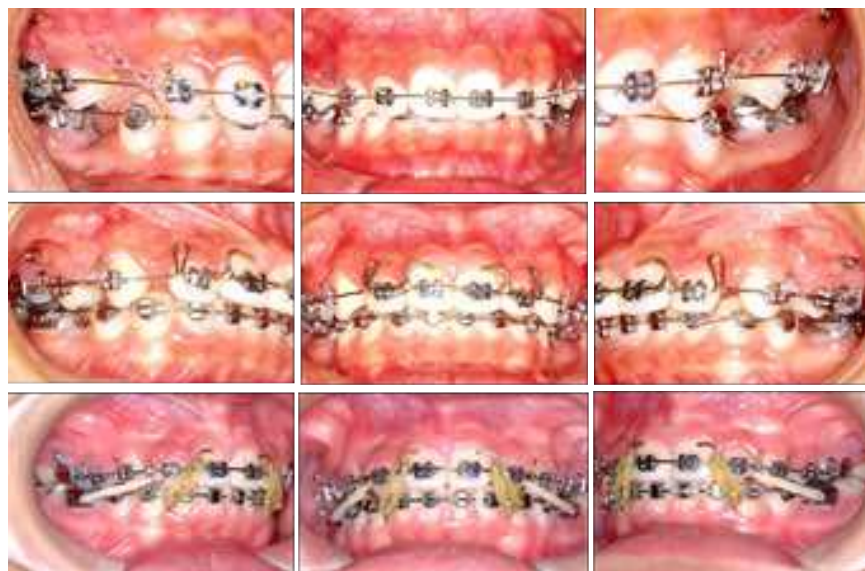

Figure 26. Intraoral photographs during treatment showing micro-implants implanted in the maxilla, elastomeric chains, class II and up and down elastics, soldered hooks for elastics and J-hook. (Case 3)

Elastic chain force was loaded one month after placement of the MIs, from the maxillary MIs to the maxillary canine brackets, to retract the maxillary canines. Two months into treatment, .018 × .025-in stainless steel archwire with running loops and elastomers were placed in the lower arch, for retracting to level mandibular anterior teeth, uprighting and mesial movement of mandibular first molars, and closing the spaces (Figure 26). During the retraction of maxillary canines and en masse retraction of maxillary anterior teeth, maxillary posterior MIs were loosened twice, so they were re-implanted into the buccal alveolar bone between the maxillary second premolars and the first molars (1.2mm in diameter, 8mm in length; Osteomed Co, Addison, Texas, U.S.A.) and between the maxillary first molars and the second molars (1.2mm in diameter, 7mm in length; Dentos Co, Taegu, Korea). During the period of bone healing, HPJH was substituted for MIs.

After the retraction of the maxillary canines into half of the extraction space, closing loop archwire was placed and was supported by the HPJH for torque control, bodily movement, and intrusion of the maxillary anterior teeth. After en-masse movement, directional force control was performed to promote mandibular response (Figure 26). The treatment was completed with ideal archwires and cusp-seating elastics. Total treatment time was 31 months.

3.3.4. Treatment results

The post-treatment facial photographs and lateral cephalometric radiograph showed a well-balanced and harmonious face through retraction of the upper and lower lips, reduction of the mentalis muscle strain, and favorable nasal and mandibular growth. The intrusive forces used on the maxillary anterior segment successfully reduced the excessive gingival display during smiling. The post-treatment intraoral photographs and dental casts showed a good interdigi-tation of the teeth, an acceptable arch form, a normal overjet-overbite relationship and a flat curve of Spee. The post-treatment panoramic radiograph showed good overall root parallelism with no significant resorption of root and alveolar bone (Figure 27). After retention of thirty-month retention, the patient showed good retention without any obvious relapse (Figure 28).

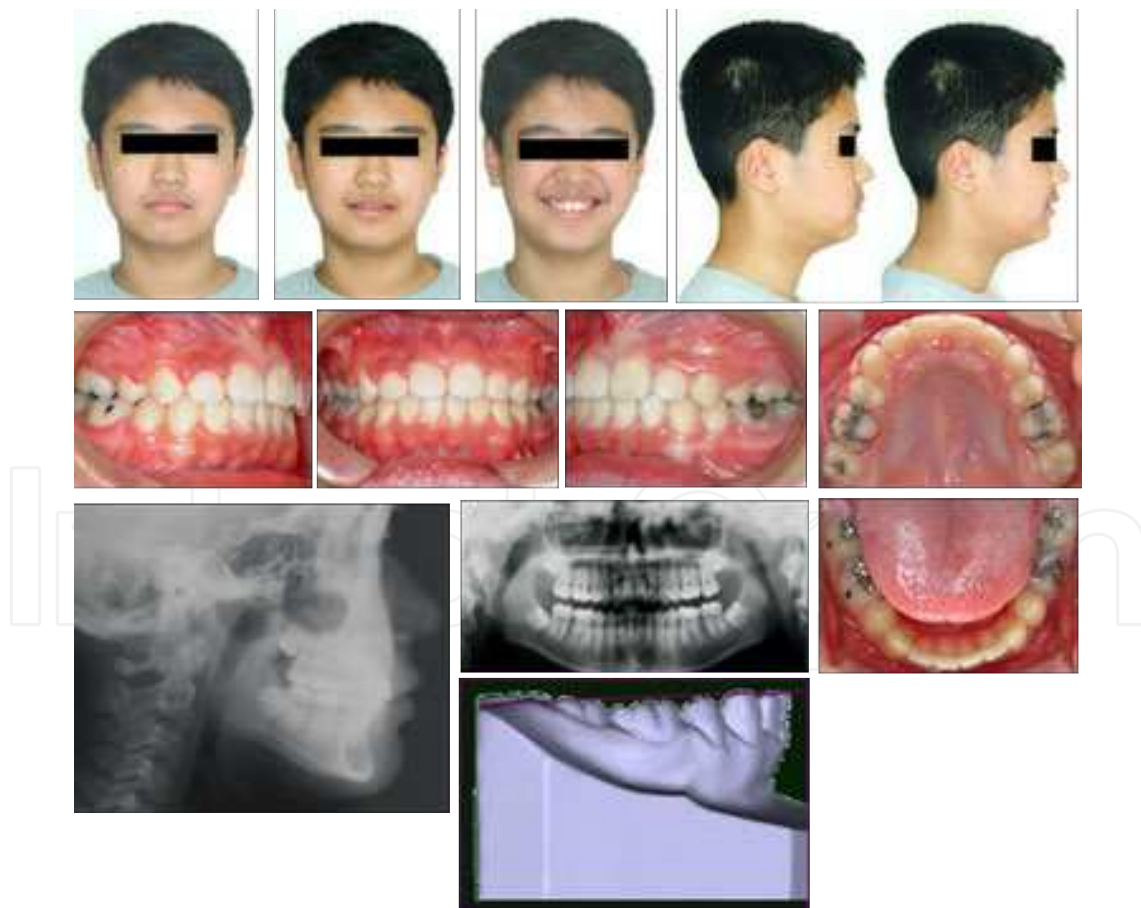


Figure 27. Post-treatment facial and intraoral photographs, mandibular cast, and cephalometric and panoramic radiographs. (Case 3)

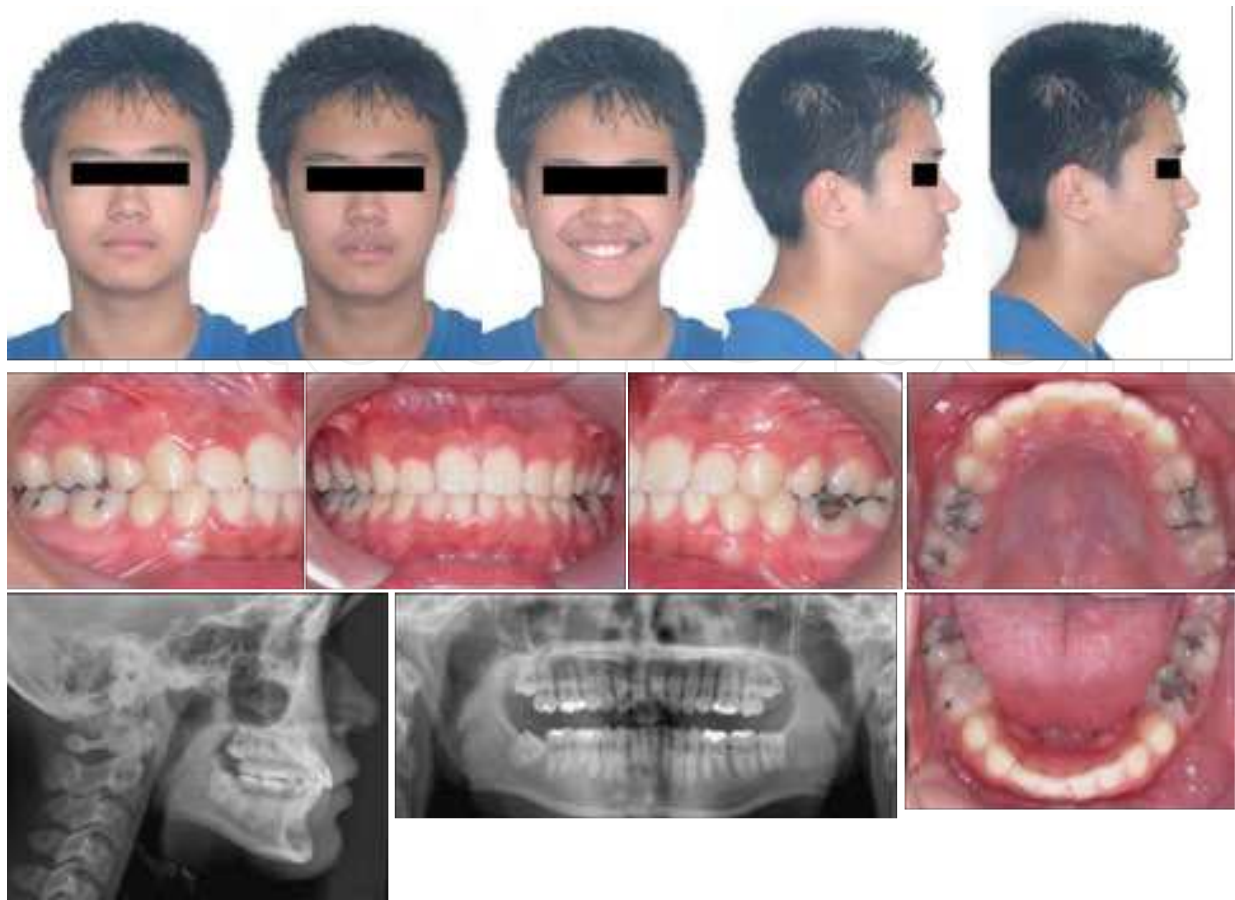


Figure 28. 30-month retention facial and intraoral photographs and cephalometric and panoramic radiographs. (Case 3)

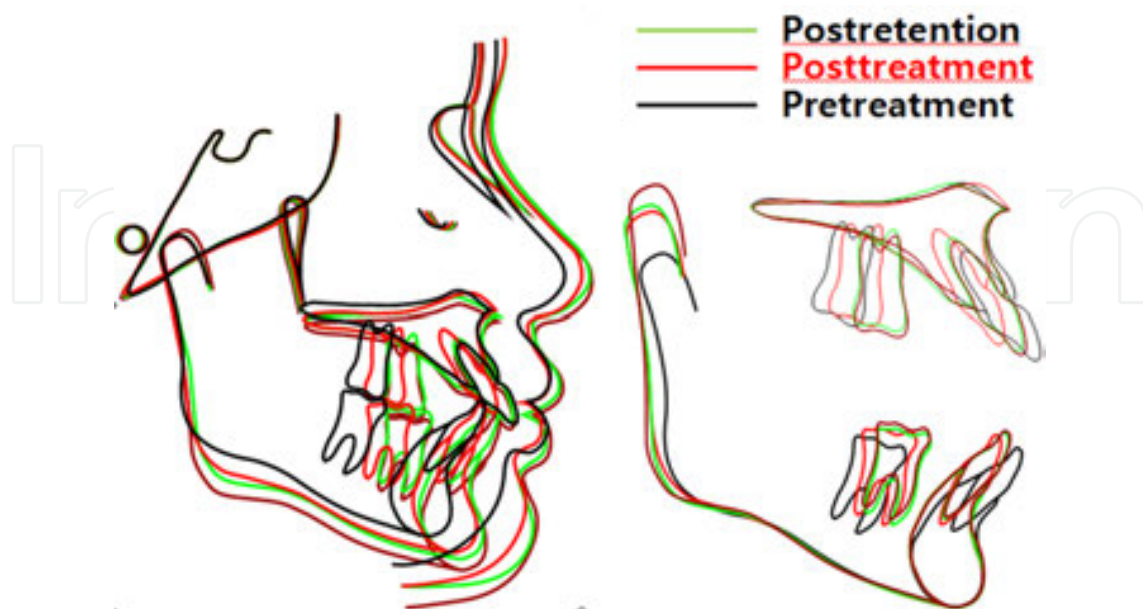


Figure 29. Pretreatment, post-treatment 30-month retention cephalometric superimposition. (Case 3)

Pretreatment and post-treatment cephalometric superimposition showed the bodily retraction with intrusion of the maxillary anterior teeth, slight intrusion of maxillary posterior teeth, retraction with uprighting of the mandibular anterior teeth, and uprighting with mesially extrusion of the mandibular posterior teeth. A good mandibular response with chin advancement was achieved by the counterclockwise rotation of the mandible caused by the vertical control of the maxillary dentition and favorable growth of mandible, resulting in a 2.0° decrease in the FMA, and a 3.5° reduction of the ANB angle. The mandibular incisors were uprighted from 106.0° to 100.0° . The Z-angle was improved from 58.5° to 78.0° and the Frankfort-mandibular incisor angle (FMIA) was increased by 8.0° . All these changes contributed to improving the facial profile. The post-treatment and 30-month retention cephalometric superimposition showed favorable growth such as maintenance of ANB and Z-angle (Figure 29 and Table 3).

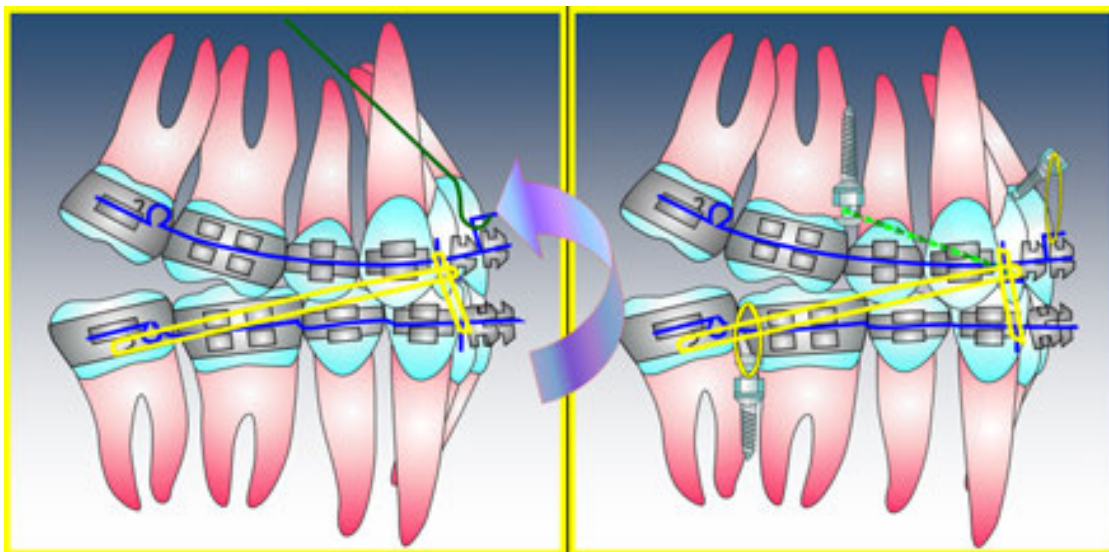


Figure 30. Counterclockwise directional force technology with HPJH and MIA.

4. Conclusion

A good facial balance could be obtained by Tweed-Merrifield directional force technology using HPJH together with skeletal anchorage, which provide anchorage control in the maxillary and mandibular posterior area, torque control in the maxillary anterior area, and mandibular response. These indicate that skeletal anchorage could be used to reinforce anchorage for directional force instead of high pull J-hook (HPJH). Consequently, Tweed-Merrifield directional force technology using M.I.A. for the treatment of Class I and Class II bialveolar protrusion not only maximizes the result of treatment but can also minimize patient compliance (Figure 30).

Author details

Jong-Moon Chae^{1,2,3}

Address all correspondence to: jongmoon@wonkwang.ac.kr

1 Department of Orthodontics, School of Dentistry, University of Wonkwang, Daejeon Dental Hospital, Wonkwang Dental Research Institute, Iksan, South Korea

2 The Korean Orthodontic Research Institute Inc, Daejeon and Seoul, South Korea

3 The Charles H. Tweed International Foundation, Tucson, Arizona, USA

References

- [1] Angle EH. The latest and best in orthodontic mechanism. *Dent Cosmos*; 1928. p1154.
- [2] Tweed CH. *Clinical Orthodontics*, vol 1 and 2. St. Louis: C.V. Mosby; 1966.
- [3] Merrifield LL, Cross JJ. Directional forces. *Am J Orthod* 1970;57:435-64.
- [4] Merrifield L. The systems of directional force. *J Charles H. Tweed Int Found* 1982;10:15-29.
- [5] Gebeck TR, Merrifield LL. Orthodontic diagnosis and treatment analysis— concepts and values: part I. *Am J Orthod Dentofacial Orthop* 1995;107:434-43.
- [6] Gebeck TR, Merrifield LL. Orthodontic diagnosis and treatment analysis— concepts and values: part II. *Am J Orthod Dentofacial Orthop* 1995;107:541-7.
- [7] Ward DM. Angle Class II, Division 1 malocclusion. *Am J Orthod Dentofacial Orthop* 1994;106:428-33.
- [8] Lamarque S. The importance of occlusal plane control during orthodontic mechanotherapy. *Am J Orthod Dentofacial Orthop* 1995;107:548-58.
- [9] Vaden JL, Harris EF, Behrents RG. Adult versus adolescent Class II correction: a comparison. *Am J Orthod Dentofacial Orthop* 1995;107:651-61.
- [10] Roberts WE, Nelson CL, Goodacre CJ. Ridgid Implant Anchorage to Close a Mandibular First Molar Extraction site. *J Clin Orthod* 1994;28:693-704.
- [11] Umemori M, Sugawara J, Mitani H, Nagasaka H, Kawamura H. Skeletal anchorage system for open-bite correction. *Am J Orthod Dentofacial Orthop* 1999;115:166-74.
- [12] Creekmore TD, Eklund MK. The possibility of skeletal anchorage. *J Clin Orthod* 1983;17:266-69.

- [13] Kanomi R. Mini-implant for Orthodontic Anchorage. *J Clin Orthod* 1997;31:763-7.
- [14] Park HS, Bae SM, Kyung HM, Sung JH. Micro-implant anchorage for treatment of skeletal Class I bialveolar protrusion. *J Clin Orthod* 2001;35:417-22.
- [15] Park HS, Kwon TG, Kwon OW. Treatment of open bite with microscrew implants anchorage. *Am J Orthod Dentofacial Orthop* 2004;126:627-36.
- [16] Chae JM. Directional forces using skeletal anchorage for treatment of skeletal Class II div.1 malocclusion. *Korean J Orthod* 2004;34(2):197-203.
- [17] Chae JM. Indirect palatal skeletal anchorage (PSA) for treatment of skeletal Class I bialveolar protrusion. *Korean J Orthod* 2004;34(5):458-64.
- [18] Chae JM. A new protocol of Tweed-Merrifield directional force technology with microimplant anchorage. *Am J Orthod Dentofacial Orthop* 2006;130(1):100-9.
- [19] Chae JM. Unusual extraction treatment of Class I bialveolar protrusion using micro-implant anchorage. *Angle Orthod* 2007;77(2):367-76.
- [20] Chae J, Kim S. Running loop in unusual molar extraction treatment. *Am J Orthod Dentofacial Orthop* 2007;132(4):528-39.
- [21] Chae JM, Chang NY, Cho JH, Kang KH, Kim SC. Treatment of skeletal Class II adult patient with vertical and transverse problems caused by nasal airway obstruction using microimplant anchorage. *Korean J Orthod* 2009;39(4):257-72.
- [22] Chae JM, Paeng JY. Orthodontic treatment of an ankylosed maxillary central incisor through single-tooth osteotomy by using interdental space regained from microimplant anchorage. *Am J Orthod Dentofacial Orthop* 2012;141(2):e39-51.

