

We are IntechOpen, the world's leading publisher of Open Access books Built by scientists, for scientists

4,400

Open access books available

117,000

International authors and editors

130M

Downloads

Our authors are among the

154

Countries delivered to

TOP 1%

most cited scientists

12.2%

Contributors from top 500 universities



WEB OF SCIENCE™

Selection of our books indexed in the Book Citation Index
in Web of Science™ Core Collection (BKCI)

Interested in publishing with us?
Contact book.department@intechopen.com

Numbers displayed above are based on latest data collected.
For more information visit www.intechopen.com



Clinical Complications of Dental Implants

Su-Gwan Kim

*Dept. of Oral and Maxillofacial Surgery, School of Dentistry, Chosun University
Republic of Korea*

1. Introduction

Dental implant surgery has become routine treatment in dentistry and is generally considered to be a safe surgical procedure with a high success rate. However, complications should be taken into consideration because they can follow dental implant surgery as with any other surgical procedure. Many of the complications can be resolved without severe problems; however, in some cases, they can cause dental implant failure or even life-threatening circumstances. Avoiding complications begins with careful treatment planning based on accurate preoperative anatomic evaluations and an understanding of all potential problems. This chapter contains surgical complications associated with dental implant surgery and management.

2. Complications associated with implant surgery

2.1 Hemorrhage

The submental artery (2mm in average diameter) (Greenstein et al., 2008 as cited in Hofschneider et al., 1999) is a branch of the facial artery. The sublingual artery (2 mm in average diameter) arises from the lingual artery and is found coronal to the mylohyoid muscle (Greenstein et al., 2008 as cited in Martin et al., 1993). The arterial blood supply of the floor of the mouth is formed by an anastomosis of the sublingual and submental arteries. In the canine area, the vessels are located closer to the lingual plate and alveolar crest than they are in more posterior areas (Dubois et al., 2010). Intraosseous hemorrhage is not a serious event, and control of the hemorrhage can be ensured by compressing the area with a directional indicator, an abutment, or the implant (Annibali et al., 2009). However, severe bleeding and the formation of massive hematomas in the floor of the mouth are the result of an arterial trauma. A vascular wound may occur after detrimental surgical manipulations or tearing of the lingual periosteum, but in most cases, it is attributed to perforations of the lingual cortical plate. Mechanical pressure exerted by the expanding hematomas displaces the tongue and floor of the mouth both superiorly and posteriorly (Kalpidis & Setayesh, 2004). This occurrence may lead to extensive bleeding into the submandibular space, resulting in a life-threatening acute airway obstruction within the first few hours after surgery (Goodacre et al., 1999). The hemorrhage can easily spread in the loose tissues of the floor of the mouth (Fig. 1.), the sublingual area, and the space between the lingual muscles, which may require intubation or an emergency tracheostomy (Dubois et al., 2010). The surgeons also should consider other sources of potential hemorrhage and subsequent hematoma formation, including injuries to muscles or other soft tissues (Isaacson, 2004) (Fig.

2.). The escalating symptomatology of massive bleeding and progressive respiratory distress strongly resemble the clinical development of Ludwig's angina. Most important is the immediate bimanual compression at the suspected site of perforation and transport of the patient to the nearest hospital to secure the airway without delay (Dubois et al., 2010).

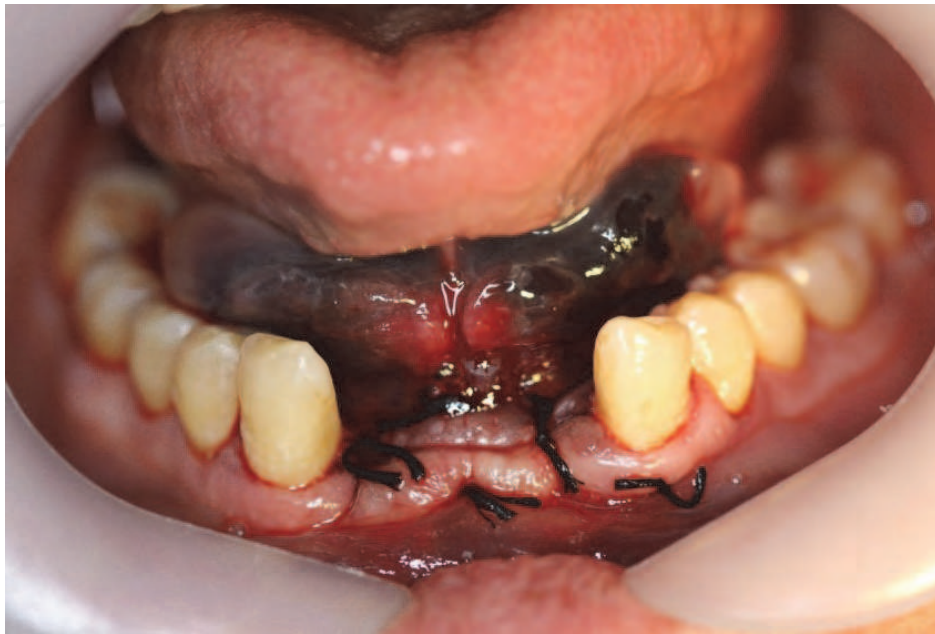

Fig. 1. A severe hematoma on the anterior floor of the mouth after implant placement in the anterior mandible.

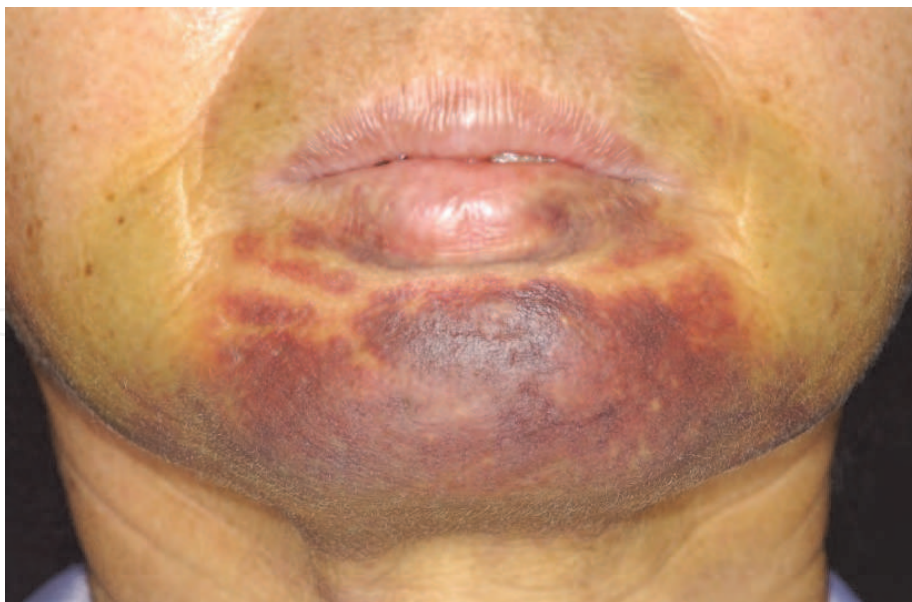


Fig. 2. Ecchymosis on the chin after implant placement in the anterior mandible.

Once the airway is controlled, efforts are undertaken for the definitive resolution of the hemorrhage (Kalpidis & Setayesh, 2004 as cited in Givol, 2000). Hemorrhages can be controlled by gauze tamponage, application of hemostatic agents, cauterization, or digital compression. If a hemorrhage cannot be controlled by these methods, ligation of the

bleeding vessel should be performed. An endovascular angiography is an alternative diagnostic tool that can overcome unsuccessful attempts to define and isolate the bleeding source (Fig. 3.) (Kalpidis & Setayesh, 2004). Incisions in the mucosa to relieve the hematoma should be avoided because they may promote further bleeding. The removal of an already inserted implant would also be ineffective (Fig. 4.) (Kalpidis & Setayesh, 2004) (Table 1).

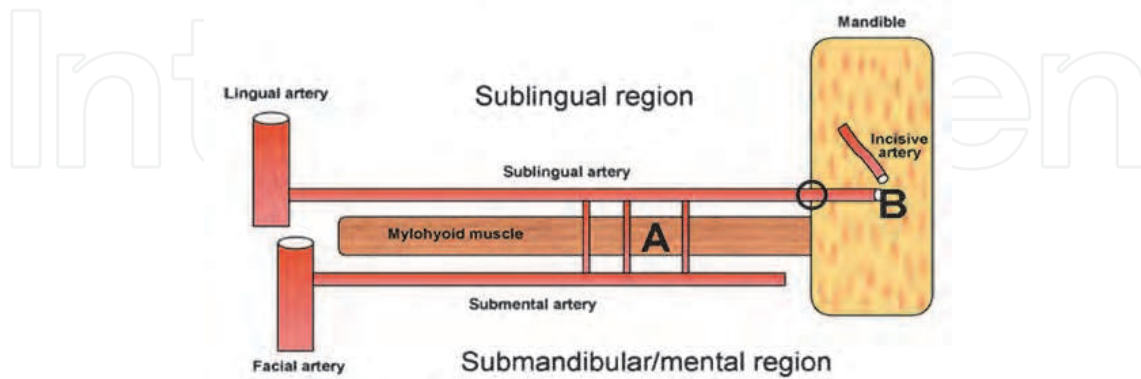


Fig. 3. A schematic representation of the arterial anatomy in the floor of the mouth (Kalpidis & Setayesh, 2004).

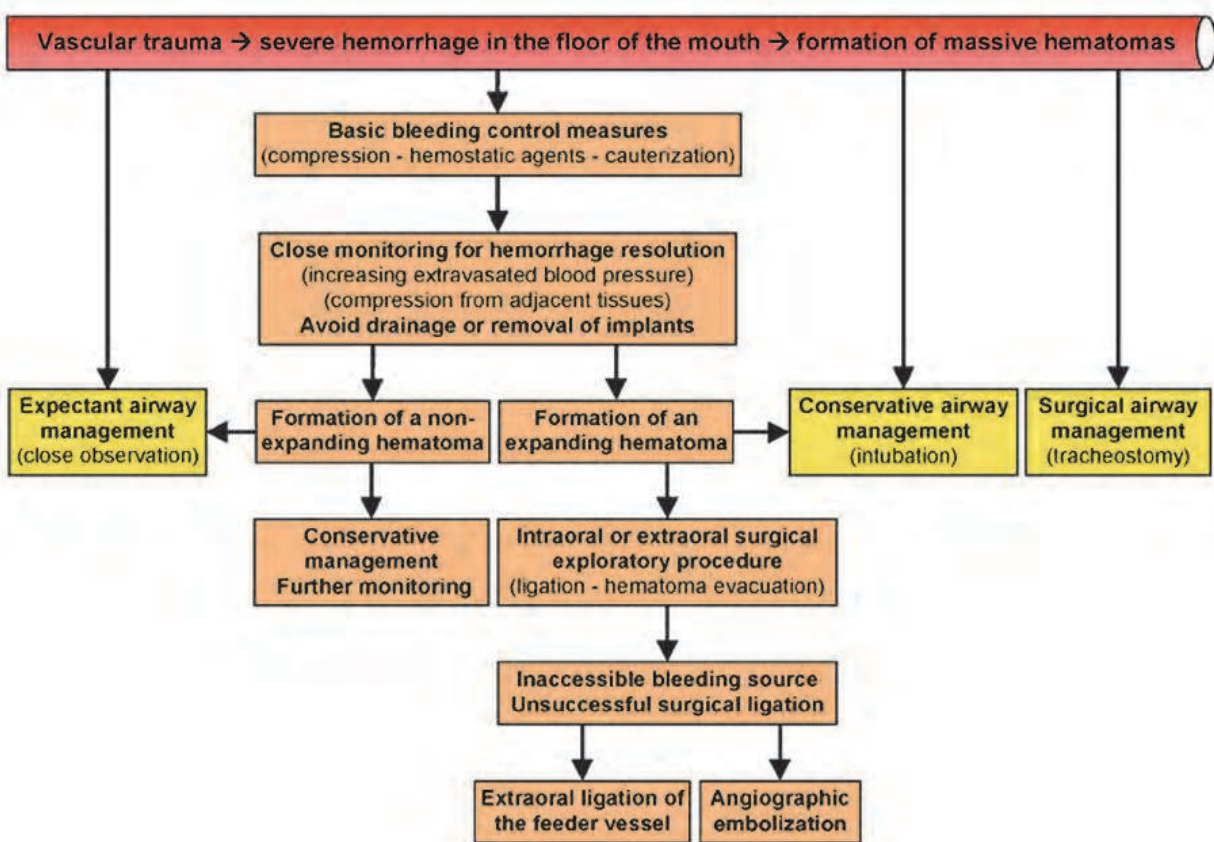


Fig. 4. A flow diagram of airway management and control of massive hemorrhage in the floor of mouth associated with implant placement in the anterior mandibular region (Kalpidis & Setayesh, 2004).

Bleeding site during implant osteotomy	Arteries	Treatments
Posterior mandible	Mylohyoid	Finger pressure at the site
Middle lingual of mandible	Submental	Surgical ligation of facial and lingual arteries
Anterior lingual of mandible	Terminal branch of sublingual or submental	Compression, vasoconstriction, cauterization, or ligation
Invading the mandibular canal	Inferior alveolar artery	Bone graft

Table 1. Treatment of a hemorrhage at an implant osteotomy site (Park & Wang, 2005)

To prevent unintentional hemorrhages in cases involving the immediate placement of implants or recent tooth extractions, the practitioner should be careful not to use the extraction socket as a guide for angulation because this may lead to the perforation of the lingual cortex (Isaacson, 2004 as cited in Givol, 2000). Soft-tissue management during the procedure is essential, and clinicians should make every attempt to avoid subperiosteal tears (Isaacson, 2004).

2.2 Neurosensory disturbances

The inferior alveolar nerve is midway between the buccal and lingual cortical plates in the first molar region (Tammisalo et al., 1992). In about 1% of patients, however, the mandibular canal bifurcates in the inferior superior or medial lateral planes. Thus, a bifurcated mandibular canal will manifest more than one mental foramen. This may or may not be seen on panoramic or periapical films. Accordingly, Dario suggested that clinicians should consider obtaining a preoperative tomogram to avoid nerve injuries prior to implant placement above the inferior alveolar canal (Greenstein & Tarnow, 2006 as cited in Dario, 2002).

A mean incidence of neurosensory disturbance incidence after implant surgery was 6.1% (Goodacre et al., 1999) to 7% (Goodacre et al., 2003), with a range between 0.6% and 39%. Nerve damage can have results ranging from mild paresthesia to complete anesthesia or even disabling dysesthesia (Table 2).

Neurapraxia	There is no loss of continuity of the nerve; it has been stretched or has undergone blunt trauma. The parasthesia will subside, and feeling will return in days to weeks.
Axonotmesis	Nerve is damaged but not severed; feeling returns within 2 to 6 months.
Neurotmesis	Severed nerve; poor prognosis for resolution of parasthesia.

Table 2. Classification of nerve injuries (Greenstein & Tarnow, 2006 as cited in Jalbout & Tabourian, 2004)

Possible causes of nerve injury include poor flap design, traumatic flap reflection, accidental intraneural injection, traction on the mental nerve in an elevated flap, penetration of the osteotomy preparation and compression of the implant body into the canal (Fig. 5.) (Misch & Wang, 2008). Nerve injuries may be caused indirectly by postsurgical intra-alveolar edema or hematomas that produce a temporary pressure increase, especially inside the mandibular canal. Direct traumas are the most frequent causes of nerve injury, and they may occur through five mechanisms: compression, stretch, cut, overheating, and accidental puncture

(Annibali et al., 2009). Finally, prolonged pressure from neuritis may lead to the permanent degeneration of the affected nerve (Park & Wang, 2005).

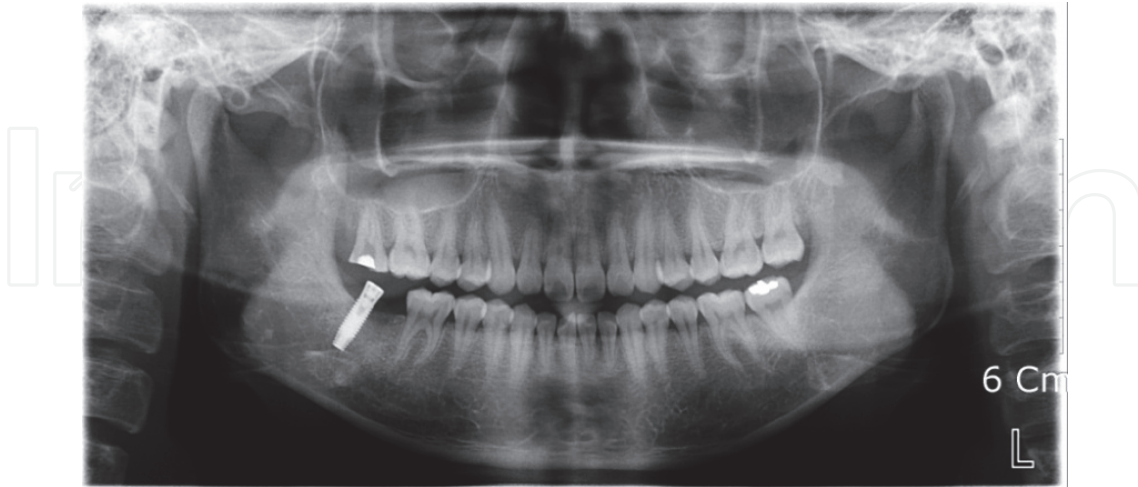


Fig. 5. An inferior alveolar nerve injury after implant placement of #47.

The mental nerve is at particular risk of iatrogenic injury because it arises from asymmetric foramina and forms a concave loop anteriorly. In edentulous patients, it may be very close to the bone surface or the top of the crest.

The nerve injury may cause one of the following conditions: parasthesia (numb feeling), hypoesthesia (reduced feeling), hyperesthesia (increased sensitivity), dyesthesia (painful sensation), or anesthesia (complete loss of feeling) of the teeth, the lower lip, or the surrounding skin and mucosa (Greenstein & Tarnow, 2006 as cited in Sharawy & Misch, 1999).

Overpenetration occurs when the cortical portion of the alveolar crest places resistance on the drill. However, as it enters the marrow spaces, a drill may drop into the neurovascular bundle unless the surgeon has excellent control (Misch & Wang, 2008).

For implants placed in the atrophic posterior mandible, the routine use of intraoperative periapical radiographs during the drilling sequence can help avoid the risk of injury to the inferior alveolar nerve. Periapical radiographs used intraoperatively to obtain working length measurements are similar in concept to techniques used in root canal therapy. This method can reliably determine safe distances between the implant and the inferior alveolar canal, thus avoiding the risk of injury to the nerve altogether (Burstein et al., 2008).

The appropriate magnification correction factor should be used, and drill guards can be placed on burs to avoid the unintentional overpenetration of the drill. A safety margin of 2 mm between the entire implant body and any nerve canal should be maintained (Greenstein et al., 2008, as cited in Greenstein & Tarnow, 2006; Worthington, 2004). Additionally, surgical placements of implants should be at least 3 mm in front of the mental foramen (Greenstein & Tarnow, 2006). When placing implants in proximity to the mental foramen, the clinician must take into consideration the anterior loop of the nerve and the available bone above the mental foramen, because the inferior alveolar nerve often rises as it approaches the mental foramen (Kraut & Chahal, 2002). Finally, although the depths of the implant bur are variable, the drill bur may be longer than the implant according to the manufacturers (Table 3).

<p>Be sure to include nerve injury as an item in the informed consent document.</p> <p>Measure the radiograph with care.</p> <p>Apply the correct magnification factor.</p> <p>Consider the bony crestal anatomy:</p> <p>If the ridge is thin buccolingually, is this useless bone or should an augmentation procedure be done?</p> <p>Is the buccolingual position of the crestal peak of bone influencing the measurement of available bone?</p> <p>Consider the buccolingual position of the nerve canal.</p>	<p>Use coronal true-size tomograms where needed.</p> <p>Allow a 1 to 2 mm safety zone.</p> <p>Use a drill guard.</p> <p>Take care with countersinking not to lose support of the crestal cortical bone.</p> <p>Use the aforementioned formula to calculate implant length.</p> <p>Keep the radiograph and the calculation in the patient's chart as powerful evidence of meticulous patient care.</p>
--	---

Table 3. Recommendations to avoid nerve injuries during implant placement (Worthington, 2004)

The mental foramen may be located at or near the crest of an atrophic mandible. To avoid damage to the mental nerve in patients with atrophic mandibles, the clinician may need to make incisions in the area of the mental foramen that are lingual to the crest of the mandible (Kraut & Chahal, 2002).

If an implant is in danger of violating the canal, its depth should be decreased in the bone (i.e., by unscrewing it a few turns) and left short of the canal or removed. Because the altered sensation may be due to an inflammatory reaction, a course of steroid treatment or a high dose of nonsteroidal anti-inflammatory medication (e.g., ibuprofen [800 milligrams] three times per day) should be prescribed for three weeks (Kraut & Chahal, 2002). Adjunct drugs such as clonazepam, carbamazepine, or vitamin B-complex might alleviate neuritis via their known neuronal anti-inflammatory actions.

If improvement is noted at three weeks on the basis of a repeated neurosensory examination, the clinician can prescribe an additional three weeks of anti-inflammatory drug treatment. If the improvement is seen, however, the patient should be referred to a microneurosurgeon (Kraut & Chahal, 2002).

The patient should be referred for microsurgery if total anesthesia persists, or if after 16 weeks, dysesthesia is ongoing (Misch & Wang, 2008, as cited in Day, 1994; Nazarian et al., 2003).

Many studies have reported favorable patient responses to inferior alveolar nerve repairs. All have emphasized the need for repair before Wallerian degeneration of the distal portion of the inferior alveolar nerve has occurred; because this degeneration is a slow process, repair is possible four to six months after the injury has occurred (Kraut & Chahal, 2002).

2.3 Injury to adjacent teeth

Damage to teeth adjacent to the implant site may occur subsequent to the insertion of implants along an improper axis or after placement of excessively large implants (Figs. 6, 7.). This problem arises more frequently with single implants (Annibali et al., 2009). Adjacent teeth should be evaluated before implant placement. Pulpal and periradicular conditions such as small periapical radiolucencies, root resorption and large restorations in/near the vital pulp are often misdiagnosed. Dilacerated roots and excessive tilting in the mesiodistal direction that invades the implant space often prevent ideal placement (Misch & Wang, 2008). The tilt of adjacent teeth should be assessed before drilling. The damage of an

adjacent tooth by implant placement may cause the tooth to become non-vital, and the tooth may require subsequent endodontic treatment. This will not only result in damage to an adjacent tooth but also implant failure (Sussman, 1998). Use of a surgical guide, radiographic analysis and CT scan can help locate the implant placement, thereby avoiding damage to adjacent teeth. The angulation of adjacent teeth and dilacerations of roots must be radiographically assessed prior to implant placement. Ideally, 1.5 to 2 mm of bone should be present between an implant and the adjacent tooth. Furthermore, inspection of a radiograph with a guide pin at a depth of 5 mm will facilitate osteotomy angulation corrections (Greenstein et al., 2008). To prevent a latent infection of the implant from the potential endodontic lesion, endodontic treatment should be performed (Sussman, 1998). Discrepancies between the apical and crestal interdental spaces as a result of mesial or distal tipping of the roots can be corrected orthodontically (Annibali et al., 2009).

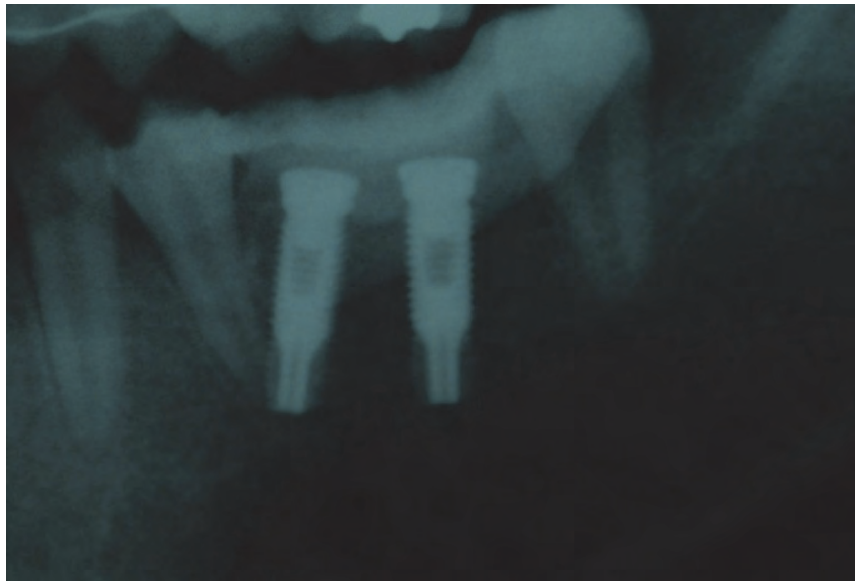


Fig. 6. Injury of an adjacent tooth by a malpositioned implant.

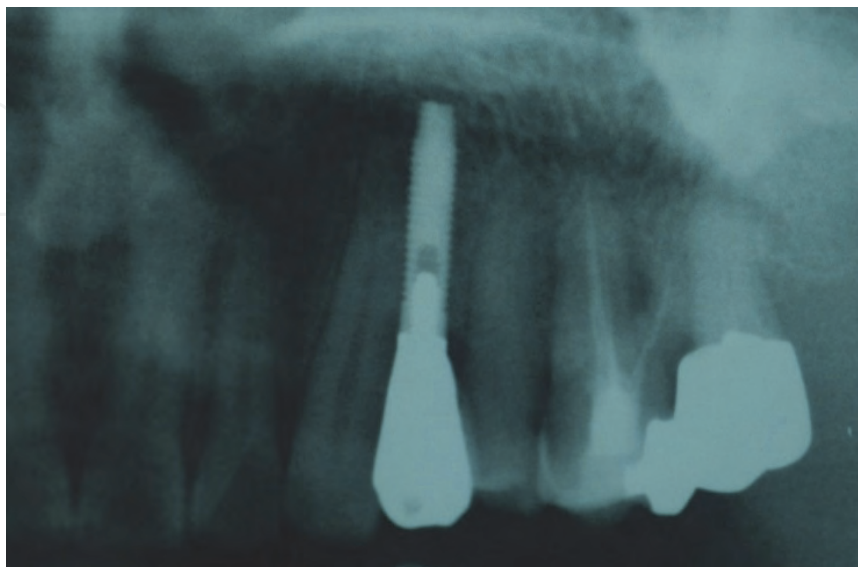


Fig. 7. A malpositioned implant hitting an adjacent tooth.

2.4 Flap dehiscence and exposure of graft material or barrier membrane

The most common postoperative complication is wound dehiscence, which sometimes occurs during the first 10 days (Greenstein et al., 2008). Contributing factors of dehiscence and exposure of the graft material or barrier membrane include flap tension, continuous mechanical trauma or irritation associated with the loosening of the cover screw, incorrect incisions and formation of sequestration of bone debris (Park & Wang, 2005). Premature exposure of barrier membranes may also cause contamination of the graft and its eventual loss (Figs. 8, 9.).

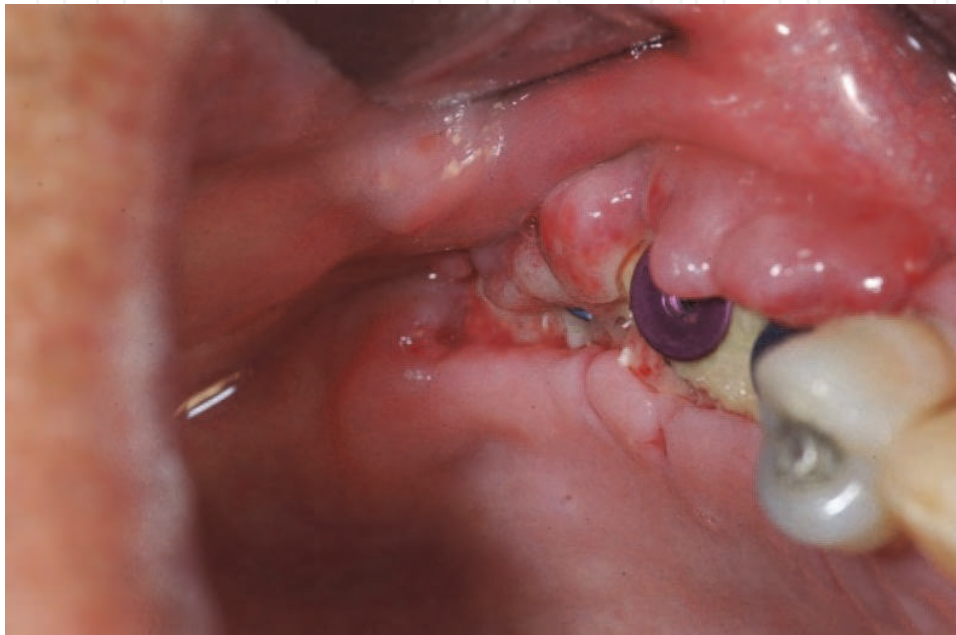

Fig. 8. A dehiscence after guided bone regeneration and implant placement using a non-resorbable membrane.

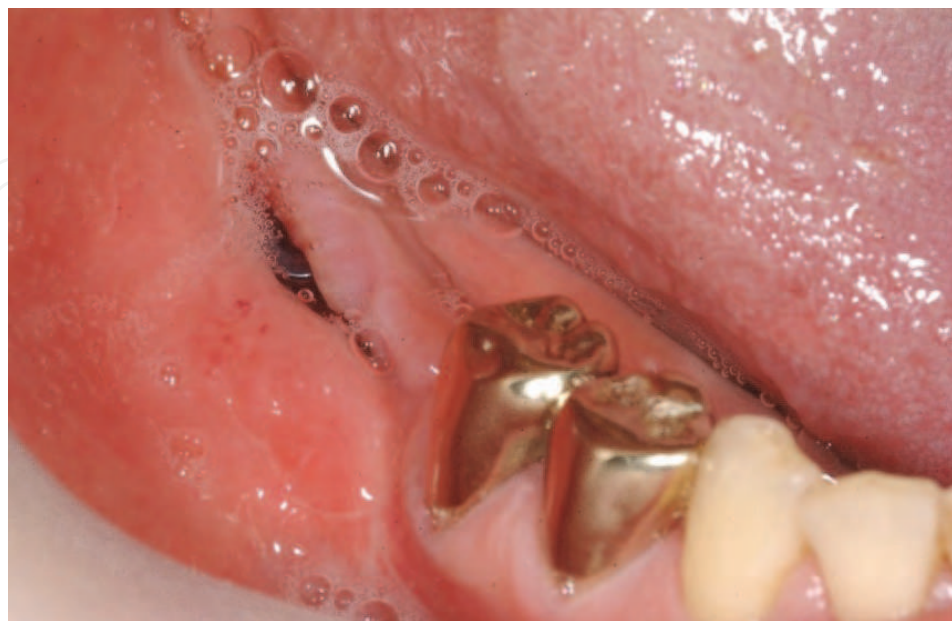

Fig. 9. A dehiscence after implant placement.

To avoid wound dehiscence, tension-free closure using a buccal releasing incision is most important. Dentures should be relieved with a tissue conditioner. Mattress sutures combined with interrupted sutures are also useful. When the dehiscence is small and occurs within 24 to 48 hours, the clinician can immediately resuture the dehiscence. Once the diameter of the wound is large (2 to 3 cm) or the time elapsed is > 2 days, it is suggested that the margins of the wound be excised and resutured (Fig. 10.) (Greenstein et al., 2008 as cited in Sadig & Almas, 2004). If the suture is not possible, chlorhexidine rinses twice a day and/or systemic antibiotics should be considered.

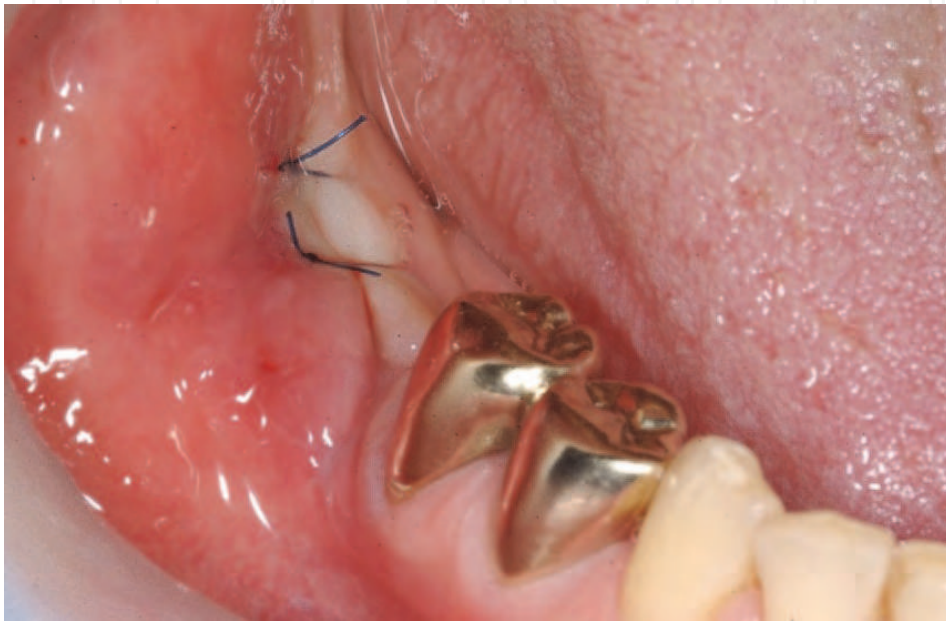

Fig. 10. Resuturing was performed to achieve closure of the dehiscence.

2.5 Bisphosphonate-related osteonecrosis

Bisphosphonates are drugs that inhibit bone resorption; they are widely used for the treatment of osteoporosis, multiple myeloma and skeletal complications of bone metastases (Table 4). The American Association of Oral and Maxillofacial Surgeons (AAOMS) states that patients are considered to have bisphosphonate-related osteonecrosis of the jaw (BRONJ) if they have the following three characteristics: current or previous treatment with a bisphosphonate, exposed or necrotic bone in the maxillofacial region that has persisted for more than 8 weeks, and no history of localized radiotherapy to the jaws (Advisory Task Force on Bisphosphonate-Related Osteonecrosis of the Jaws, 2007). The risk of BRONJ associated with oral bisphosphonates appears to increase when the duration of therapy more than 3 years. This time may be shortened in the presence of certain comorbidities. Type 2 diabetes mellitus (Abu-Id et al., 2008), prolonged steroid therapy (Advisory Task Force on Bisphosphonate-Related Osteonecrosis of the Jaws, 2007), and health-threatening habits such as smoking (Wessel et al., 2008; Yarom et al., 2007) were suggested as predisposing conditions for the development of BRONJ.

If systemic conditions permit, discontinuation of oral bisphosphonates for a period of 3 months prior to and 3 months after elective invasive dental surgery may lower the risk of BRONJ. The risk reduction may vary depending on the duration of bisphosphonate exposure (Advisory Task Force on Bisphosphonate-Related Osteonecrosis of the Jaws, 2007).

Active ingredient	Trade name	Administered
Alendronate	Fosamax [®] , Fosavance [®]	Orally
Etidronate	Osteum [®] , Difosfen [®]	Orally
Resedronate	Actonel [®] , Acrel [®]	Orally
Tiludronate	Skelid [®]	Orally
Zoledronate	Zometa [®] , Aclasta [®]	Intravenously
Pamidronate	Aredia [®] , Linoten [®] , Pamifos [®] , Xinsidona [®]	Intravenously
Ibandronate	Bondronat [®]	Orally, Intravenously
Clodronate	Bonefos [®]	Orally, Intravenously

Table 4. Different types of bisphosphonates in current usage (Montoya-Carralero et al., 2010)

Currently, there are no reliable or widely available tests for the risk of BRONJ. Marx et al. recommend a blood test, specifically involving a serum C-terminal telopeptide test (CTX) to assess a surrogate marker of bone turnover in patients taking oral bisphosphonates. Categorization of <100 pg/mL as high risk, 100 pg/mL to 150 pg/mL as moderate risk, and >150 pg/mL as minimal risk provides the clinician (Marx et al., 2007).

Many articles have confirmed that implant surgery in patients receiving oral bisphosphonate therapy does not result in BRONJ. (Bell & Bell, 2008; Fugazzotto et al., 2007; Grant et al., 2008; Jeffcoat, 2006) Nevertheless, patients taking bisphosphonates who either had implants that failed to integrate or had integrated implants that subsequently failed have been reported (Goss & Backhaus, 2007; Stark & Epker, 1995; Wang et al., 2007).

The prognosis of dental implants that have been placed remains uncertain, and the use of osseointegrated dental implants is controversial.

AAOMS does not contraindicate dental implant placement in patients who have been taking bisphosphonates orally for less than three years prior to surgery, provided that they do not present other risk factors such as medications with corticosteroids or advanced age (e.g., older than seventy years). It has been reported that oral bisphosphonates had a lower risk because they took longer to develop bisphosphonate-induced osteonecrosis given their slower accumulation rates in bone (Ruggiero et al., 2004). Moreover, a drug holiday is recommended 3 to 6 months in duration before dental implant placement in patients with a history of oral bisphosphonate use for longer than 3 years (Ruggiero et al., 2009). Finally, current guidelines contraindicate the placement of dental implants in cancer patients treated with intravenous bisphosphonates (Ruggiero et al., 2009; Khan et al., 2008).

Although bisphosphonates tend to accumulate in sites of active bone remodeling like the jaws, surgical trauma to the alveolar bone during implant surgery could further stimulate the postoperative accumulation of the drug in the implanted site. The localized interference of bisphosphonates on areas of bone turnover may reduce the peri-implant bone resistance to oral bacteria in the long term, thus increasing the risk of peri-implantitis. The potential role of infection on implant failure and BRONJ occurrence is still debated. However, at least one study has reported a reduced incidence of BRONJ in patients who were given prophylactic antibiotics (Montefusco et al., 2008). In addition, the use of perioperative antibiotics and a chlorhexidine mouth wash have been suggested. Great attention should be paid to the oral hygiene and plaque control of implant-prosthetic restorations (Bedogni et al., 2010). Patients treated with bisphosphonates who receive implants should be followed for long periods of time. All patients treated with

oral bisphosphonates must be informed of the potential complications of implant failure and BRONJ development in both the short and long term before the placement of dental implants (Bedogni et al., 2010).

AAOMS has proposed the use of the following staging categories and treatment guidelines regarding BRONJ (Table 5).

BRONJ Staging	Treatment Strategies
At risk category: No apparent exposed/necrotic bone in patients who have been treated with either oral or IV bisphosphonates	No treatment indicated Patient education
Stage 1: Exposed/necrotic bone in patients who are asymptomatic and have no evidence of infection	Antibacterial mouth rinse Clinical follow-up on a quarterly basis Patient education and review of indications for continued bisphosphonate therapy
Stage 2: Exposed/necrotic bone associated with infection as evidenced by pain and erythema in the region of the exposed bone with or without purulent drainage	Symptomatic treatment with broad-spectrum oral antibiotics, e.g., penicillin, cephalexin, clindamycin, or first generation fluoroquinolone Oral antibacterial mouth rinse Pain control Only superficial debridements to relieve soft tissue irritation
Stage 3: Exposed/necrotic bone in patients with pain, infection, and one or more of the following: pathologic fracture, extraoral fistula, or osteolysis extending to the inferior border	Antibacterial mouth rinse Antibiotic therapy and pain control Surgical debridement/resection for longer term palliation of infection and pain

Table 5. Staging and treatment strategies (Advisory Task Force on Bisphosphonate-Related Osteonecrosis of the Jaws, 2007)

3. Complications associated with maxillary sinus lift

3.1 Schneiderian membrane perforation

The Schneiderian membrane, which is characterized by periosteum overlaid with a thin layer of pseudociliated stratified respiratory epithelium, constitutes an important barrier for the protection and defense of the sinus cavity. The integrity of the sinus membrane is essential in maintaining the healthy and normal function of the maxillary sinus (Ardekian et al., 2006).

The mucociliary apparatus protects the sinus against infection while the membrane also acts as a biologic barrier. If a perforation occurs, the membrane perforation could represent a window for bacterial penetration and invasion into the grafted area (Zijderveld et al., 2008). Failure to atraumatically elevate the Schneiderian membrane may result in graft migration or loss, exposure of the graft or the implant to the sinus, and postoperative site infection. In addition to contaminating the recipient site, disruption of the mucosa may alter the normal

mucociliary flow patterns, causing retention of secretions and infections around the foreign body (Ward et al., 2008).

The most common intraoperative complication seems to be Schneiderian membrane perforation, which occurs in 10% to 60% of all procedures (Ardekian et al., 2006; Pikos, 1999; Proussaefs et al., 2004). The risk of membrane perforation increases when anatomical variations such as a maxillary sinus septum, spine, or sharp edge are present (Chanavaz, 1990; van den Bergh et al., 2000). Very thin or thick maxillary sinus walls create higher risks of perforating the Schneiderian membrane. The angulation between the medial and lateral walls of the maxillary sinus seemed to exert an especially large influence on the incidence of membrane perforation. For example, sharper angles observed at the inner walls of the sinus in the vicinity of the second upper bicuspid presents a higher risk of perforation (Zijderveld et al., 2008).

The occurrence of iatrogenic sinus membrane perforations during surgery does not seem to be related to sinusitis in healthy people (Ardekian et al., 2006). However, large tears can cause sinusitis, graft infection, or graft displacement into the sinus, which could compromise new bone formation and implant survival (Reiser et al., 2001).

To minimize Schneiderian membrane perforations, surgeons must evaluate the maxillary sinus anatomy while considering the lateral thickness of the lateral wall, slope of the sinus wall, location of septa, membrane thickness through the radiography and CT analysis before maxillary sinus augmentation. Piezoelectric surgery is usually more time-consuming than other techniques, though the frequency and number of Schneiderian membrane perforations or lacerations are generally lower. If the bony lateral wall is thick, a reduction of the thickness of the wall before formation of the lateral window is recommended. In cases involving a very thin maxillary sinus wall, careful reflection of the mucoperiosteum is recommended while the Schneiderian membrane already shines a dark grayish-bluish color through the sinus wall. It is advised that clinicians not begin the lateral door preparation with a round stainless-steel burr; they should use a round diamond bur directly, thereby reducing the risk of a membrane perforation (Zijderveld et al., 2008). To prevent a perforation, some additional small holes in the suction device are recommended to diminish the suction power and to avoid the direct contact of the suction device with the Schneiderian membrane (Zijderveld et al., 2008).

If a tear in the membrane occurs along the periphery of the osteotomy and it is difficult to reengage the membrane, this situation can be managed by extending the outline of the osteotomy several millimeters past the original window and reestablishing contact with the membrane (Greenstein et al., 2008). In general, small tears (<5 to 8 mm) are mitigated simply by folding the membrane up against itself as the membrane is elevated (Chanavaz, 1990). Larger tears do not lend themselves to closure by infolding, and they would need additional methods to contain the graft in its desired position. It has been reported that large sinus membrane perforations should be repaired with collagen or a fibrin adhesive. In severe perforations, some investigators have even suggested abandoning the procedure for 6 to 9 months while the membrane regenerates (Karabuda et al., 2006).

3.2 Hemorrhage

The blood supply of the maxillary sinus is derived from the infraorbital artery, the greater palatine artery and the posterior superior alveolar artery (Chanavaz, 1990; Uchida et al., 1998a). Bleeding during sinus augmentation is rare because the main arteries are not within

the surgical area. Although accidental laceration of the vessel is not life-threatening because of the small size of the artery, an impaired visualisation may compromise the elevation of the Schneiderian membrane and interfere with the placement of the graft material (Elian et al., 2005; Testori et al., 2010).

The blood supply to the buccal antral portions relevant to sinus floor elevation surgery occurs via two arteries: the posterior superior alveolar artery and the infraorbital artery, as well as their intraosseous branches and anastomoses (Solar et al., 1999). Anatomically, anastomosis between the posterior superior alveolar artery and infraorbital artery is always found at the lateral antral wall (Traxler et al., 1999); bleeding via damage to these arteries may occur during the formation of the lateral window. The average distance from the artery to the alveolar crest was 16.4 mm (Elian et al., 2005) to 18.9 mm (± 2.82 mm) (Solar et al., 1999).

The height of the residual bony ridge appears to play a significant role in the location of the vessel. In classes A, B and C (Lekholm & Zarb classification (Lekholm & Zarb, 1985)), the vessel was found >15 mm from the alveolar crest, but in classes D and E, the value was >7 mm (mean 10.4 mm). It is recommended, therefore, to place the superior border of the osteotomy up to 15 mm from the alveolar crest in classes A, B and C, which is sufficient for sinus exposure and placement of long dental implants. In severely atrophic ridges, or classes D and E, where the surgeon has a tendency to place the osteotomy of the sinus wall too far cranially, there is a high probability of transecting the vessel (Mardinger et al., 2007b). Such bleeding can usually be controlled by pressure with a moist gauze pad (Fig. 11.) (Elian et al., 2005).

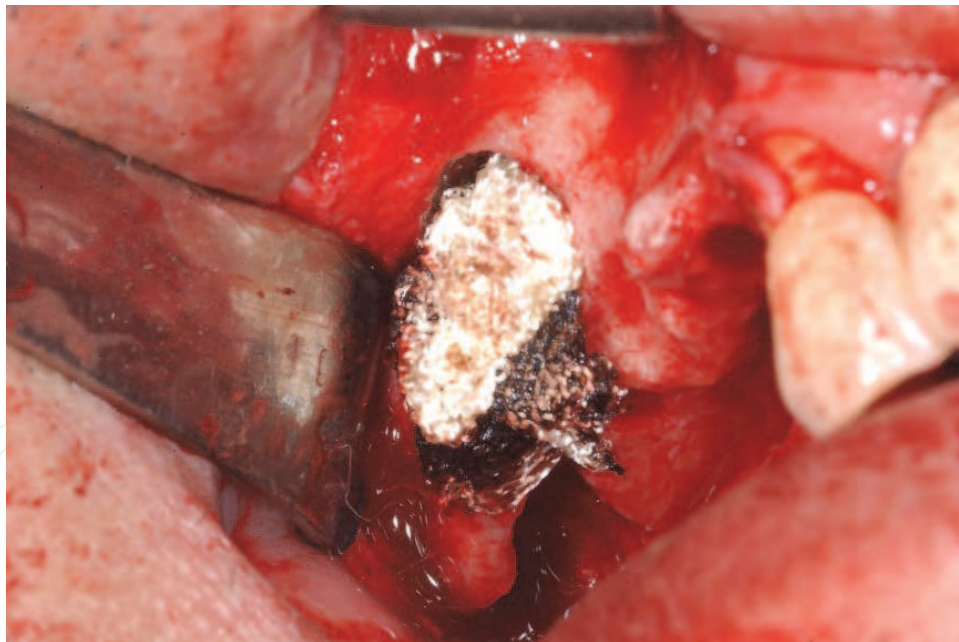

Fig. 11. Hemostasis was achieved using Surgicel during maxillary sinus augmentation.

A preoperative CT examination is essential to detect the location of the intraosseous anastomoses. In addition, piezoelectric surgical inserts may be beneficial in minimizing lacerations of vessels and membrane (Testori et al., 2010). A vestibular extraosseous anastomosis runs below the zygomatic process (Solar et al., 1999). This anastomosis is located in the area of the periosteum overlying the lateral wall at a higher level than the intraosseous anastomosis. The vascular compromise would be the result of an inappropriate

anterior releasing incision or vertical incision (Elian et al., 2005). To avoid damage to the extraosseous anastomosis, vertical mucosal incisions should extend superiorly as little as possible, and the periosteum should be prepared carefully (Solar et al., 1999).

3.3 Loss of the implant or graft materials into the maxillary sinus

The displacement of implants or graft materials into the maxillary sinus can result in a foreign-body reaction and cause serious complications. Migration of a dental implant into the maxillary sinus may present a risk for the development of maxillary sinusitis. Immediate implant insertion should be performed only if the residual bone is stable and high enough to ascertain high primary stability (Becker et al., 2008).

An implant can easily migrate into the sinus without apparent force in the posterior maxilla, clearly showing a lack of osseointegration (Fig. 12.). Various mechanisms have been proposed to explain the migration of an implant into the maxillary sinus, which fall under three main categories: changes in intrasinal and nasal pressures; autoimmune reaction to the implant, causing peri-implant bone destruction and compromising osseointegration; and resorption produced by an incorrect distribution of occlusal forces (Galindo et al., 2005). The changes in intrasinal and nasal air pressures produce a suction effect because of the negative pressure exerted by these cavities. A portion of the bone grafting material can become dislodged in the maxillary sinus at either the initial ridge augmentation or during the implant placement surgery. The natural ciliary movement in the maxillary sinus will transport foreign material toward the ostium (Hunter et al., 2009). In cases with less than 5 mm of bone, mastication can cause the implants to move during the graft maturation timeframe (Peleg et al., 2006). The implants must be immediately retrieved surgically via an intraoral approach or endoscopically via the transnasal route to avoid inflammatory complications (Ueda & Kaneda, 1992). To avoid complications when bone volume is inadequate to support an implant with sufficient length, a bone reconstruction procedure of the maxilla should be performed.

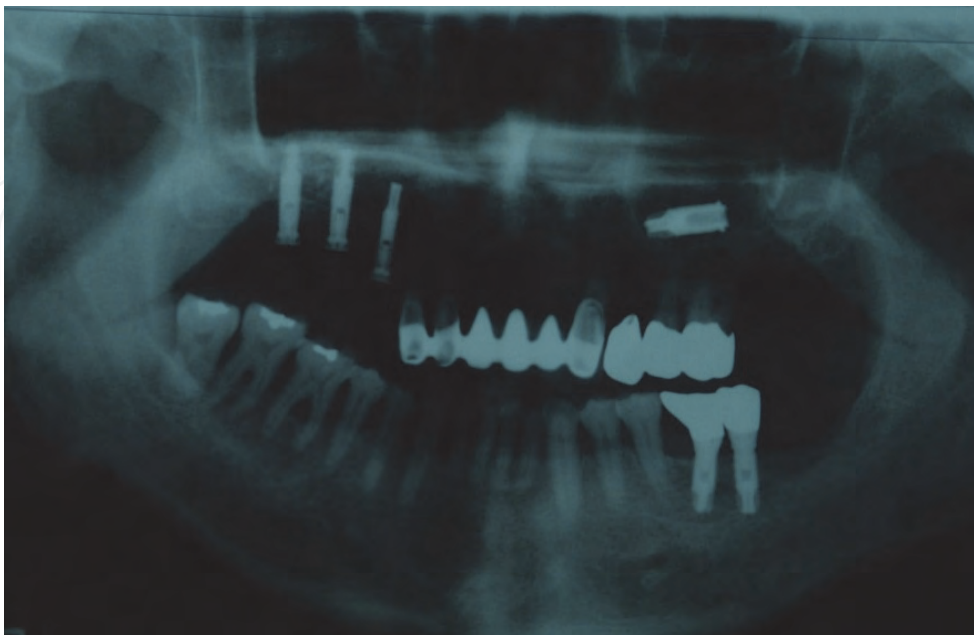

Fig. 12. Displacement of an implant into the maxillary sinus.

3.4 Postoperative maxillary sinusitis

The mean height of the maxillary sinus is 36 to 45 mm, the mean width mesiodistally is 25 to 35 mm, and the mean depth is 38 to 45 mm (laterally–medially). The average total maxillary sinus volume is 13.6 ± 6.4 cc. The minimum maxillary sinus volume is 3.5 cc, while the maximum is 31.8 cc (Uchida, 1998b). The ostium is located on the superior aspect of the medial wall of the maxillary sinus above the first molar (van den Bergh et al., 2000). The normal drainage pattern of the maxillary sinus is into the middle nasal meatus by way of a naturally occurring ostium.

The ostium is usually 35 mm superior to the floor of the maxillary sinus (Zinner et al., 2008). This information can be used to prevent maxillary sinus complications such as sinusitis by the obstruction of the ostium. Radiographic imaging of the osteo-meatal complex is crucial in fully evaluating the physiologic health of the maxillary sinus and the likelihood of avoiding infections following maxillary bone grafting (Zinner et al., 2008).

Maxillary sinusitis can occur as a result of contamination of the maxillary sinus with oral or nasal pathogens or via ostial obstruction caused by postoperative swelling of the maxillary mucosa, hematoma and seroma. Mucosal swelling may lead to the reduction of the patency of the ostio-meatal unit (Figs. 13, 14.). This unit plays a key role in the development of sinusitis, through impairment of the mucociliary cleansing system (Bertrand & Eloy, 1992). Maxillary sinusitis can also occur because of non-vital bony fragments floating freely in the maxillary sinus. Another cause is the lack of asepsis during sinus augmentation (Timmenga et al., 2001). Maintenance of normal maxillary sinus physiology should be a major goal while ostium patency must be preserved. Therefore, the use of a systemic decongestant, such as pseudoephedrine, and a nasal spray containing a vasoconstrictor, such as phenylephrine, is recommended after implant surgery (Regev et al., 1995).

The development of sinusitis following sinus augmentation can be directly related to drainage disturbances, mainly as a result of septal deviation and allergies combined with oversized inferior and middle turbinates (Mardinger, 2007a). In the event of an inadvertent laceration or puncture of the Schneiderian membrane and inoculation of the maxillary sinus

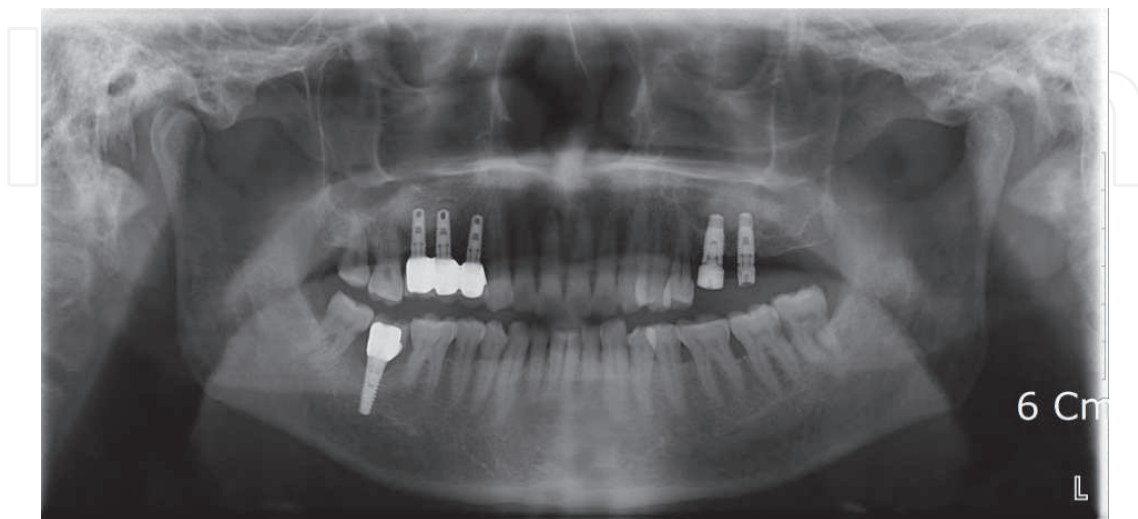


Fig. 13. Panoramic view showing an area of opacification on the left maxillary sinus.

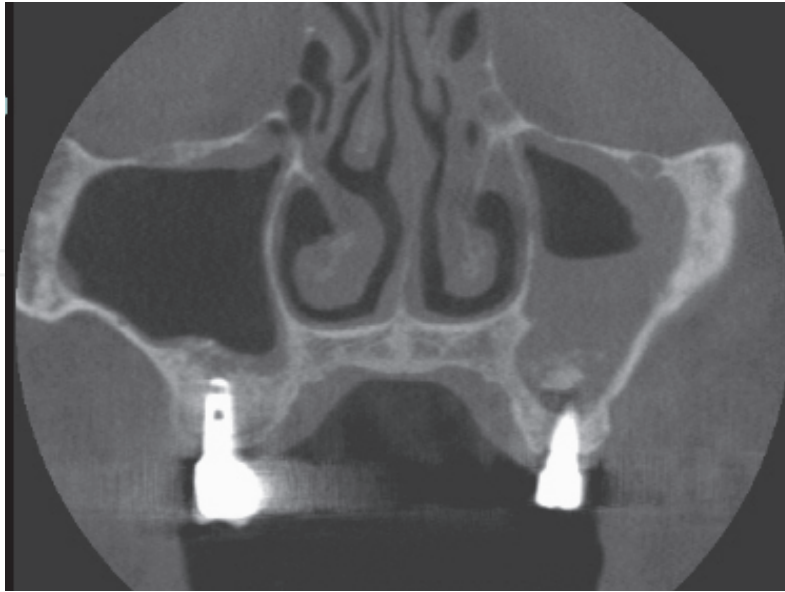


Fig. 14. Computed tomography scan clearly shows significant mucosal thickening along the entire lining of the sinus.

with oral bacteria, a healthy sinus with a patent osteo-meatal complex will usually remove the offending bacteria and remain healthy (Zinner et al., 2008). With no patent drainage pathway, the maxillary sinus quickly became obstructed, inflamed, and then infected (Hunter et al., 2009).

Timmenga et al. reported that the occurrence of postoperative sinusitis after bone grafting of the sinus floor is limited to patients with a predisposition for sinusitis (Timmenga et al., 1997). To minimize the occurrence of a postoperative infection, possible causes should be removed prior to sinus augmentation.

A history of excessive yellow or green nasal discharge, particularly with worsening nasal obstruction, is a relatively strong predictor of possible chronic bacterial sinusitis and may warrant further assessment for chronic sinusitis (Ward et al., 2008). A nasoendoscopic evaluation should be considered for patients with a history of frequent sinusitis to rule out the presence of an obstructive phenomenon as a risk factor before undergoing sinus augmentation (Manor et al., 2010).

Most implant failures occur 3 to 6 months after surgery, and they are usually not associated with an infection of the maxillary sinus (Becker et al., 2008). The clinical diagnosis of sinusitis is characterized by a triad of symptoms: nasal congestion, secretion or obstruction, and headache (Manor et al., 2010). If an infection develops (e.g., pain, redness, and tenderness) without fluctuance, antibiotics are administered. Once there is fluctuance, incision and drainage are performed in conjunction with systemic antibiotics (Barone et al., 2006; Regev et al., 1995).

Pathogens found have included *β-hemolytic Streptococcus*, *Enterococcus*, *Peptostreptococcus*, *Pneumococcus*, *Staphylococcus* (Doud Galli et al., 2001) and *Actinomycosis* (Roth & Montone, 1996). The antibiotics most effective in alleviating sinus infections are amoxicillin, trimethoprim sulfamethoxazole, and cefaclor. Amoxicillin with clavulanic acid and clindamycin also are commonly used (Regev et al., 1995). General guidelines for treatment of sinusitis was represented in Tables 6, 7.

Transient sinusitis	Chronic sinusitis
<ol style="list-style-type: none"> 1. Use of decongestants and antibiotics 2. Follow-up after 2 weeks 3. If no recovery, transient sinusitis has possibly evolved into subacute sinusitis needing further treatment: <ol style="list-style-type: none"> a. Continuation of decongestants and antibiotics b. Maxillary drains for sinus irrigation c. CT scanning and consideration of functional endoscopic sinus surgery if no recovery within 3 weeks 	<ol style="list-style-type: none"> 1. Use of decongestants and antibiotics 2. CT scanning and functional endoscopic sinus surgery

Table 6. General guidelines for the treatment of transient and chronic maxillary sinusitis after maxillary sinus augmentation (Timmenga et al., 2001)

<ol style="list-style-type: none"> 1. Preoperative evaluation of sinus clearance-related factors 2. Postsurgery: a nasal decongestant (xylomethazoline 0.05%) and topical corticosteroid (dexamethasone 0.01%) to prevent postsurgery obstruction of the ostium 3. Perioperative antibiotic prophylaxis (cephradine 1 g 3 times daily, starting 1 hour before surgery and continued for 48 hours after surgery)
--

Table 7. General guidelines for the prevention of transient and chronic maxillary sinusitis after maxillary sinus augmentation (Timmenga et al., 2001)

4. Conclusions

Although serious complications are uncommon, dental implant placement is not free of complications, as complications may occur at any stage (Table 8). Therefore, careful analysis via imaging, precise surgical techniques and an understanding of the anatomy of the surgical area are essential in preventing complications. One should be aware of the possible complications related to implant placement so that the patient can be properly informed. Prompt recognition of a developing problem and proper management are needed to minimize postoperative complications.

Problems	Possible causes	Solutions
Nerve injury	Mechanical injury by stretching, compression, and partial or total transection	Remove implant Wait for a period Rivotril®, Tegretol®, Vitamin B6
Hemorrhage during drilling	Injury of an artery	Extraoral pressure from the submental against the body of mandible Implant placement will stop bleeding

Fracture of mandible	Atrophic mandible	Immediate implant retrieval Bone graft Monocortical miniplates
Penetration of nasal/sinus floor	Type IV bone	Primary closure Antibiotic, decongestant, chlorhexidine
Lack of primary stability	Type IV bone, grafted bone, imprecise preparation, excessive countersinking	Remove implant, replace with larger diameter or longer implant
Maxillary sinus lift	Preexisting condition, surgical handling	Seal by folding the excess membrane, collagen membrane, bone graft, primary closure Antibiotics, decongestant, chlorhexidine
Significant bleeding	Subclinical bleeding diathesis, surgical handling	Atraumatic surgical technique, compression for >10min
Devitalization of adjacent teeth	Not enough space in between implant and adjacent tooth	Endodontic treatment

Table 8. Intraoperative surgical-related complications (Park & Wang, 2005)

5. References

- Abu-Id, MH.; Warnke, PH. & Gottschalk J. (2008). "Bis-phosphy jaws"- High and low risk factors for bisphosphonate-induced osteonecrosis of the jaw. *J Craniomaxillofac Surg*, Vol. 36, No. 2, (January 2008), pp. 95-103, ISSN 1010-5182, Edinburgh, Scotland
- American Association of Oral and Maxillofacial Surgeons. (2007). Advisory Task Force on Bisphosphonate-Related Osteonecrosis of the Jaws, American Association of Oral and Maxillofacial Surgeons position paper on bisphosphonate-related osteonecrosis of the jaws. *J Oral Maxillofac Surg*, Vol. 65, No. 3, (March 2007), pp. 369-76, ISSN 0278-2391, Philadelphia, Pennsylvania, USA
- Annibaldi, S.; Ripari, M., La Monaca, G., Tonoli, F. & Cristalli MP. (2009). Local accidents in dental implant surgery: prevention and treatment. *Int J Periodontics Restorative Dent* Vol. 29, No. 3, (June 2009), pp. 325-31, ISSN 0278-2391, Philadelphia, Pennsylvania, USA
- Ardekian, L.; Oved-Peleg, E., Mactei, E. & Peled, M. (2006). The clinical significance of sinus membrane perforation during augmentation of the maxillary sinus. *J Oral Maxillofac Surg*, Vol. 64, No. 2, (February 2006), pp. 277-82, ISSN 0278-2391, Philadelphia, Pennsylvania, USA
- Barone, A.; Santini, S., Sbordone, L., Crespi, R. & Covani, U. (2006). A clinical study of the outcomes and complications associated with maxillary sinus augmentation. *Int J*

- Oral Maxillofac Implants*, Vol. 21, No. 1, (Jan-Feb 2006), pp. 81-5, ISSN 0882-2786, Illinois, USA
- Becker, ST.; Terheyden, H., Steinriede, A., Behrens, E., Springer, I. & Wiltfang, J. (2008). Prospective observation of 41 perforations of the Schneiderian membrane during sinus floor elevation. *Clin Oral Implants Res*, Vol. 19, No. 12, pp. 1285-9, ISSN 0905-7161, Oxford, England
- Bedogni, A.; Bettini, G., Totola, A., Saia, G. & Nocini, PF. (2010). Oral bisphosphonate-associated osteonecrosis of the jaw after implant surgery: a case report and literature review. *J Oral Maxillofac Surg*, Vol. 68, No. 7, pp. 1662-6, ISSN 0278-2391, Philadelphia, Pennsylvania, USA
- Bell, BM.; Bell R. (2008). Oral bisphosphonates and dental implants: A retrospective study. *J Oral Maxillofac Surg*, Vol. 66, Vol. 5, pp. 1022-4, ISSN 0278-2391, Philadelphia, Pennsylvania, USA
- Bertrand, B.; Eloy, P. (1992). Relationship of chronic ethmoidal sinusitis, maxillary sinusitis, and ostial permeability controlled by sinusomanometry: statistical study. *Laryngoscope*, Vol. 102, No. 11, (Nov 1992), pp. 1281-4, ISSN 0023-852X, Philadelphia, Pennsylvania, USA
- Burstein, J.; Mastin, C. & Le, B. (2008). Avoiding injury to the inferior alveolar nerve by routine use of intraoperative radiographs during implant placement. *J Oral Implantol*, Vol. 34, No. 1, pp. 34-8, ISSN 0160-6972, Kansas, USA
- Chanavaz, M. (1990). Maxillary sinus: Anatomy, physiology, surgery, and bone grafting related to implantology – Eleven years of surgical experience. *J Oral Implantol*, Vol. 16, No. 3, pp. 199-209, ISSN 0160-6972, Kansas, USA
- Dario, LJ. (2002). Implant placement above a bifurcated mandibular canal: a case report. *Implant Dent*, Vol. 11, No. 3, pp. 258-61, ISSN 1056-6163, Philadelphia, Pennsylvania, USA
- Day, RH. (1994). Microneurosurgery of the injured trigeminal nerve. *Oral Maxillofac Surg Knowledge Update*, Vol. 1, pp. 91-116
- Doud Galli, SK.; Lebowitz, RA., Giacchi, RJ., Glickman, R. & Jacobs, JB. (2001). Chronic sinusitis complicating sinus lift surgery. *Am J Rhinol*, Vol. 15, No. 3, (May-Jun 2001), pp. 181-6, ISSN 1050-6586, Rhode Island, USA
- Dubois, L.; de Lange, J., Baas, E. & Van Ingen, J. (2010). Excessive bleeding in the floor of the mouth after endosseous implant placement: a report of two cases. *Int J Oral Maxillofac Surg*, Vol. 39, No. 4, (Apr 2010), pp. 412-5, ISSN 0901-5027, Edinburgh, Scotland
- Elian, N.; Wallace, S., Cho, SC., Jalbout, ZN. & Froum, S. (2005). Distribution of the maxillary artery as it relates to sinus floor augmentation. *Int J Oral Maxillofac Implants*, Vol. 20, No. 5, (Sep-Oct), pp. 784-7, ISSN 0882-2786, Illinois, USA
- Fugazzotto, PA.; Lightfoot, WS., Jaffin, R. & Kumar, A. (2007). Implant placement with or without simultaneous tooth extraction in patients taking oral bisphosphonates: Postoperative healing, early follow-up, and the incidence of complications in two private practices. *J Periodontol*, Vol. 78, No. 9, (Sep 2007), pp. 1664-9, ISSN 0022-3492, Chicago, Illinois, USA


- Galindo, P.; Sánchez-Fernández, E., Avila, G., Cutando, A. & Fernandez, JE. (2005). Migration of implants into the maxillary sinus: two clinical cases. *Int J Oral Maxillofac Implants*, Vol.20, No. 2, (Mar-Apr 2005), pp. 291-5, ISSN 0882-2786 Illinois, USA
- Givol, N.; Chaushu, G., Halamish-Shani, T. & Taicher, S. (2000). Emergency tracheostomy following life-threatening hemorrhage in the floor of the mouth during immediate implant placement in the mandibular canine region. *J Periodontol*, Vol. 71, No. 12, (Dec 2000), pp. 1893-5, ISSN 0022-3492, Chicago, Illinois, USA
- Goodacre, CJ.; Kan, JY. & Rungcharassaeng, K. (1999). Clinical complications of osseointegrated implants. *J Prosthet Dent*, Vol. 81, No. 5, (May 1999), pp. 537-52, ISSN 0022-3913, New York, USA
- Goodacre, CJ.; Bernal, G., Rungcharassaeng, K. & Kan, JY. (2003). Clinical complications with implants and implant prostheses. *J Prosthet Dent*, Vol. 90, No. 2, (Aug 2003), pp. 121-32, ISSN 0022-3913, New York, USA
- Goss, AN.; Backhouse, P. (2007). Bisphosphonates and osteonecrosis of the jaws. *Aust Prescriber*, Vol. 30, pp. 96-7, ISSN 0312-8008, Deakin, Australia
- Grant, BT.; Amenedo, C., Freeman, K. & Kraut, RA. (2008). Outcomes of placing dental implants in patients taking oral bisphosphonates: A review of 115 cases. *J Oral Maxillofac Surg*, Vol. 66, No. 2, (Feb 2008), pp. 223-30, ISSN 0278-2391, Philadelphia, Pennsylvania, USA
- Greenstein, G.; Tarnow, D. (2006). The mental foramen and nerve: clinical and anatomical factors related to dental implant placement: a literature review. *J Periodontol*, Vol. 77, No. 12, (Dec 2006), pp. 1933-43, ISSN 0022-3492, Chicago, Illinois, USA
- Greenstein, G.; Cavallaro, J., Romanos, G. & Tarnow, D. (2008). Clinical recommendations for avoiding and managing surgical complications associated with implant dentistry: a review. *J Periodontol*, Vol. 79, No. 8, pp.1317-29, ISSN 0022-3492, Chicago, Illinois, USA
- Hofschneider, U.; Tepper, G., Gahleitner, A. & Ulm, C. (1999). Assessment of the blood supply to the mental region for reduction of bleeding complications during implant surgery in the interforaminal region. *Int J Oral Maxillofac Implants*, Vol. 14, No. 3, (May-Jun 1999), pp. 379-83, ISSN 0882-2786, Illinois, USA
- Hunter, WL 4th.; Bradrick, JP., Houser, SM., Patel, JB. & Sawady, J. (2009). Maxillary sinusitis resulting from ostium plugging by dislodged bone graft: case report. *J Oral Maxillofac Surg*, Vol. 67, No. 7, pp. 1495-8, ISSN 0278-2391, Philadelphia, Pennsylvania, USA
- Isaacson, TJ. (2004). Sublingual hematoma formation during immediate placement of mandibular endosseous implants. *J Am Dent Assoc*, Vol. 135, No. 2, (Feb 2004), pp. 168-72, ISSN 0002-8177, Chicago, Illinois, USA
- Jalbout, Z.; Tabourian, G. (2004). Glossary of Implant Dentistry, *Proceedings of International Congress of Oral Implantologists*, Upper Montclair, New Jersey 2004
- Jeffcoat, MK. (2006). Safety of oral bisphosphonates: Controlled studies on alveolar bone. *Int J Oral Maxillofac Implants*, Vol. 21, No. 3, (May-Jun 2006), pp. 349-53, ISSN 0882-2786, Illinois, USA

- Kalpidis, CD.; Setayesh, RM. (2004). Hemorrhaging associated with endosseous implant placement in the anterior mandible: a review of the literature. *J Periodontol*, Vol. 75, No. 5, (May 2004), pp. 631-45, ISSN 0022-3492, Chicago, Illinois, USA
- Karabuda, C.; Arisan, V. & Ozyuvaci, H. (2006). Effects of sinus membrane perforations on the success of dental implants placed in the augmented sinus. *J Periodontol*, Vol. 77, No. 12, (Dec 2006), pp. 1991-7, ISSN 0022-3492, Chicago, Illinois, USA
- Khan, AA.; Sándor, GK., Dore, E., Morrison, AD., Alsahli, M., Amin, F., Peters, E., Hanley, DA., Chaudry, SR., Dempster, DW., Glorieux, FH., Neville, AJ., Talwar, RM., Clokie, CM., Al Mardini, M., Paul, T., Khosla, S., Josse, RG., Sutherland, S., Lam, DK., Carmichael, RP., Blanas, N., Kendler, D., Petak, S., St-Marie, LG., Brown, J., Evans, AW., Rios, L. & Compston, JE. (2008). Canadian consensus practice guidelines for bisphosphonate associated osteonecrosis of the jaw. *J Rheumatol* Vol. 35, No. 7, pp. 1391-7, ISSN 0315-162X, Toronto, Ontario, Canada
- Kraut, RA.; Chahal, O. (2002). Management of patients with trigeminal nerve injuries after mandibular implant placement. *J Am Dent Assoc*, Vol. 133, No. 10, (Oct 2002), pp. 1351-4, ISSN 0002-8177, Chicago, Illinois, USA
- Lekholm, U.; Zarb, GA. (1985). Patient selection and preparation, In: *Tissue- Integrated Prostheses: Osseointegration in Clinical Dentistry*, Bra°nemark, PL., Zarb, GA. & Albrektsson, T., pp. 199-209, Quintessence, ISBN: 0-86715-129-3, Illinois, USA
- Manor, Y.; Mardinger, O., Bietlitum, I., Nashef, A., Nissan, J. & Chaushu, G. (2010). Late signs and symptoms of maxillary sinusitis after sinus augmentation. *Oral Surg Oral Med Oral Pathol Oral Radiol Endod*, Vol. 110, No. 1, (Jul 2010), pp. e1-4, ISSN 1079-2104, New York, USA
- Mardinger, O.; Manor, I., Mijiritsky, E. & Hirshberg, A. (2007). Maxillary sinus augmentation in the presence of antral pseudocyst: a clinical approach. *Oral Surg Oral Med Oral Pathol Oral Radiol Endod*, Vol. 103, No. 2, (Feb 2007), pp. 180-4, ISSN 1079-2104, New York, USA
- Mardinger, O.; Abba, M., Hirshberg, A. & Schwartz-Arad, D. (2007). Prevalence, diameter and course of the maxillary intraosseous vascular canal with relation to sinus augmentation procedure: a radiographic study. *Int J Oral Maxillofac Surg*, Vol. 36, No. 8, (Aug 2007), pp. 735-8, ISSN 0901-5027, Edinburgh, Scotland
- Martin, D.; Pascal, JF., Baudet, J., Mondie, JM., Farhat, JB., Athoum, A., Le Gaillard, P. & Peri, G. (1993). The submental island flap: a new donor site. Anatomy and clinical applications as a free or pedicled flap. *Plast Reconstr Surg*, Vol. 92, No. 5, (Oct 1993), pp. 867-73, ISSN 0032-1052, Philadelphia, Pennsylvania, USA
- Marx, RE. ; Cillo, JE. Jr. & Ulloa, JJ. (2007). Oral bisphosphonate-induced osteonecrosis: risk factors, prediction of risk using serum CTX testing, prevention, and treatment. *J Oral Maxillofac Surg*, Vol. 65, No. 12, (Dec 2007), pp. 2397-410, ISSN 0278-2391, Philadelphia, Pennsylvania, USA
- Misch, K.; Wang, HL. (2008). Implant surgery complications: etiology and treatment. *Implant Dent*, Vol. 17, No. 2, (Jun 2008), pp. 159-68, ISSN 1056-6163, Philadelphia, Pennsylvania, USA
- Montefusco, V.; Gay, F., Spina, F., Miceli, R., Maniezzo, M., Teresa Ambrosini, M., Farina, L., Piva, S., Palumbo, A., Boccadoro, M. & Corradini, P. (2008). Antibiotic prophylaxis

- before dental procedures may reduce the incidence of osteonecrosis of the jaw in patients with multiple myeloma treated with bisphosphonates. *Leuk Lymphoma* Vol. 49, No. 11, (Nov 2008), pp. 2156-62, ISSN 1042-8194, Ebingdon, England
- Montoya-Carralero, JM.; Parra-Mino, P., Ramírez-Fernández, P., Morata-Murcia, IM., Mompeán-Gambín Mdel, C. & Calvo-Guirado, JL. (2010). Dental implants in patients treated with oral bisphosphonates: a bibliographic review. *Med Oral Patol Oral Cir Bucal*, Vol. 15, No. 1, (Jan 2010), pp. e65-9, ISSN 1698-4447, Valencia, Spain
- Nazarian, Y.; Eliav, E. & Nahlieli, O. (2003). Nerve injury following implant placement: Prevention, diagnosis and treatment modalities. *Refuat Hapeh Vehashinayim*, Vol. 20, No. 3, (Jul 2003), pp. 44-50, ISSN 0792-9935, Israel
- Park, SH.; Wang, HL. (2005). Implant reversible complications: classification and treatments. *Implant Dent*, Vol. 14, No. 3, pp. 211-20, ISSN 1056-6163, Philadelphia, Pennsylvania, USA
- Peleg, M.; Garg, AK. & Mazor, Z. (2006). Predictability of simultaneous implant placement in the severely atrophic posterior maxilla: A 9-year longitudinal experience study of 2132 implants placed into 731 human sinus grafts. *Int J Oral Maxillofac Implants*, Vol. 21, No. 1, pp. 94-102, ISSN 0882-2786, Illinois, USA
- Pikos, M. (1999). Maxillary sinus membrane repair. Report of a technique for large perforations. *Implant Dent*, Vol. 8, No. 1, pp. 29- 34, ISSN 1056-6163, Philadelphia, Pennsylvania, USA
- Proussaefs, P. ; Lozada, J., Kim, J. & Rohrer, MD. (2004). Repair of the perforated sinus membrane with a resorbable collagen membrane: A human study. *Int J Oral Maxillofac Impl*, Vol. 19, No. 3, (May-Jun 2004) pp. 413-420, ISSN 0882-2786, Illinois, USA
- Regev, E.; Smith, RA., Perrott, DH. & Pogrel, MA. (1995). Maxillary sinus complications related to endosseous implants. *Int J Oral Maxillofac Implants*, Vol. 10, No. 4, (Jul-Aug 1995), pp. 451-61, ISSN 0882-2786, Illinois, USA
- Reiser, GM.; Rabinovitz, Z., Bruno, J., Damoulis, PD. & Griffin, TJ. (2001). Evaluation of maxillary sinus membrane response following elevation with the crestal osteotome technique in human cadavers. *Int J Oral Maxillofac Implants*, Vol. 16, No. 6, (Nov-Dec 2001), pp. 833-40, ISSN 0882-2786, Illinois, USA
- Roth, M.; Montone, KT. (1996). Actinomycosis of the paranasal sinuses: a case report and review. *Otolaryngol Head Neck Surg*, Vol. 114, No. 6, pp. 818-21, ISSN 0194-5998, New York, USA
- Ruggiero, SL.; Mehrotra, B., Rosenberg, TJ. & Engroff, SL. (2004). Osteonecrosis of the jaws associated with the use of bisphosphonates: a review of 63 cases. *J Oral Maxillofac Surg*, Vol. 62, No. 5, (May 2004), pp. 527-34, ISSN 0278-2391, Philadelphia, Pennsylvania, USA
- Ruggiero, SL.; Dodson, TB., Assael, LA., Landesberg, R., Marx, RE. & Mehrotra, B. (2009). American Association of Oral and Maxillofacial Surgeons: Position paper on bisphosphonate-related osteonecrosis of the jaws—2009 update. *J Oral Maxillofac Surg*, Vol. 67, No. 5 suppl, pp. 2-12, ISSN 0278-2391, Philadelphia, Pennsylvania, USA

- Sadig, W.; Almas, K. (2004). Risk factors and management of dehiscence wounds in implant dentistry. *Implant Dent*, Vol. 13, No. 2, pp. 140-147, ISSN 1056-6163, Philadelphia, Pennsylvania, USA
- Schwartz-Arad, D.; Herzberg, R. & Dolev, E. (2004). The prevalence of surgical complications of the sinus graft procedure and their impact on implant survival. *Journal of Periodontology*, Vol. 75, No. 4, (Apr 2004), pp. 511-516, ISSN 0022-3492, Chicago, Illinois, USA
- Sharawy, M.; Misch, CE. (1999). Anatomy for dental implants. In: *Contemporary Implant Dentistry, 2nd ed*, Misch, CE. pp. 217-224, The CV Mosby Company, ISBN 0815170599, St. Louis, USA
- Shlomi, B.; Horowitz, I., Kahn, A., Dobriyan, A. & Chaushu, G. (2004). The effect of sinus membrane perforation and repair with Lambone sheet on the outcome of maxillary sinus floor augmentation: A radiographic assessment. *Int J Oral Maxillofac Implants*, Vol. 19, No. 4, (Jul-Aug 2004), pp. 559-62, ISSN 0882-2786, Illinois, USA
- Solar, P.; Geyerhofer, U., Traxler, H., Windisch, A., Ulm, C. & Watzek, G. (1999). Blood supply to the maxillary sinus relevant to sinus floor elevation procedures. *Clin Oral Implants Res*, Vol. 10, No. 1, (Feb 1999), pp. 34-44, ISSN 0905-7161, Oxford, England
- Stark, WJ.; Epker, BN. (1995). Failure of osseointegrated dental implants after bisphosphonate therapy for osteoporosis. A case report. *Int J Oral Maxillofac Implants*, Vol. 10, No. 1, (Jan-Feb), pp. 74-8, ISSN 0882-2786, Illinois, USA
- Sussman, HI. (1998). Tooth devitalization via implant placement: a case report. *Periodontal Clin Investig*, Vol. 20, No. 1, pp. 22-4, ISSN 1065-2418, USA
- Tammisalo, T.; Happonen, RP. & Tammisalo, EH. (1992). Stereographic assessment of mandibular canal in relation to the roots of impacted lower third molar using multiprojection narrow beam radiography. *Int J Oral Maxillofac Surg*. Vol. 21, No. 2, (Apr 1992), pp. 85-9, ISSN 0901-5027, Edinburgh, Scotland
- Testori, T.; Rosano, G., Taschieri, S. & Del Fabbro, M. (2010). Ligation of an unusually large vessel during maxillary sinus floor augmentation. A case report. *Eur J Oral Implantol*, Vol. 3, No. 3, (Autumn 2010), pp. 255-8, ISSN 1756-2406
- Timmenga, NM.; Raghoobar, GM., Boering, G. & Weissenbruch, R. (1997). Maxillary sinus function after sinus lifts for the insertion of dental implants. *J Oral Maxillofac Surg*, Vol. 55, No. 9, pp. 936-9, ISSN 0278-2391, Philadelphia, Pennsylvania, USA
- Timmenga, NM.; Raghoobar, GM., van Weissenbruch, R. & Vissink, A. (2001). Maxillary sinusitis after augmentation of the maxillary sinus floor: a report of 2 cases. *J Oral Maxillofac Surg*, Vol. 59, No. 2, Feb 2001), pp. 200-4, ISSN 0278-2391, Philadelphia, Pennsylvania, USA
- Traxler, H.; Windisch, A., Geyerhofer, U., Surd, R., Solar, P. & Firbas, W. (1999). Arterial blood supply of the maxillary sinus. *Clin Anat*, Vol. 12, No. 6, pp. 417-421, ISSN 0897-3806, New Jersey, USA
- Uchida, Y.; Goto, M., Katsuki, T. & Akiyoshi, T. (1998) A cadaveric study of maxillary sinus size and aid in bone grafting of the maxillary sinus floor. *Journal of Oral and Maxillofacial Surgery*, Vol. 56, No. 10, (Oct 1998), pp. 1158-1163, ISSN 0278-2391, Philadelphia, Pennsylvania, USA

- Uchida, Y.; Goto, M., Katsuki, T. & Soejima, Y. (1998). Measurement of maxillary sinus volume using computerized tomographic images. *Int J Oral Maxillofac Implants*, Vol. 13, No. 6, (Nov-Dec 1998), pp. 811-8, ISSN 0882-2786, Illinois, USA
- Ueda, M.; Kaneda, T. (1992). Maxillary sinusitis caused by dental implants: report of two cases. *J Oral Maxillofac Surg*, Vol. 50, No. 3, (Mar 1992), pp. 285-7, ISSN 0278-2391, Philadelphia, Pennsylvania, USA
- van den Bergh, JP.; ten Bruggenkate, CM., Disch, FJ. & Tuinzing, DB. (2000). Anatomical aspects of sinus floor elevations. *Clin Oral Implants Res*, Vol. 11, No. 3, (Jun 2000), pp. 256-265, ISSN 0905-7161, Oxford, England
- Wang, HL.; Weber, D. & McCauley, LK. (2007). Effect of long-term oral bisphosphonates on implant wound healing: Literature review and a case report. *J Periodontol*, Vol. 78, No. 3, (Mar 2007), pp. 584-94, ISSN 0022-3492, Chicago, Illinois, USA
- Ward, BB.; Terrell, JE. & Collins, JK. (2008). Methicillin-resistant *Staphylococcus aureus* sinusitis associated with sinus lift bone grafting and dental implants: a case report. *J Oral Maxillofac Surg*, Vol. 66, No. 2, (Feb 2008), pp. 231-4, ISSN 0278-2391, Philadelphia, Pennsylvania, USA
- Wessel, JH.; Dodson, TB. & Zavras, AI. (2008). Zoledronate, smoking, and obesity are strong risk factors for osteonecrosis of the jaw: A case-control study. *J Oral Maxillofac Surg*, Vol. 66, No. 4, pp. 625-31, ISSN 0278-2391, Philadelphia, Pennsylvania, USA
- Worthington, P. (2004). Injury to the inferior alveolar nerve during implant placement: a formula for protection of the patient and clinician. *Int J Oral Maxillofac Implants*, Vol. 19, No. 5, (Sep-Oct 2004), pp. 731-4, ISSN 0882-2786, Illinois, USA
- Yarom, N.; Yahalom, R., Shoshani, Y., Hamed, W., Regev, E. & Elad, S. (2007). Osteonecrosis of the jaw induced by orally administered bisphosphonates: Incidence, clinical features, predisposing factors and treatment outcome. *Osteoporos Int*, Vol. 18, No. 10, (Oct 2007), pp. 1363-70, ISSN 0937-941X, Godalming, England
- Zijderveld, SA.; van den Bergh, JP., Schulten, EA. & ten Bruggenkate, CM. (2008). Anatomical and surgical findings and complications in 100 consecutive maxillary sinus floor elevation procedures. *J Oral Maxillofac Surg*, Vol. 66, No. 7, (Jul 2008), pp. 1426-38, ISSN 0278-2391, Philadelphia, Pennsylvania, USA
- Zinner, ID.; Shapiro, HJ., Gold, SD. (2008). Sinus graft complications. Problem solving. *N Y State Dent J*, Vol. 74, No. 4, (Jun-Jul 2008), pp. 40-3, ISSN 0028-7571, New York, USA



Implant Dentistry - A Rapidly Evolving Practice

Edited by Prof. Ilser Turkyilmaz

ISBN 978-953-307-658-4

Hard cover, 544 pages

Publisher InTech

Published online 29, August, 2011

Published in print edition August, 2011

Implant dentistry has come a long way since Dr. Branemark introduced the osseointegration concept with endosseous implants. The use of dental implants has increased exponentially in the last three decades. As implant treatment became more predictable, the benefits of therapy became evident. The demand for dental implants has fueled a rapid expansion of the market. Presently, general dentists and a variety of specialists offer implants as a solution to partial and complete edentulism. Implant dentistry continues to evolve and expand with the development of new surgical and prosthodontic techniques. The aim of *Implant Dentistry - A Rapidly Evolving Practice*, is to provide a contemporary clinic resource for dentists who want to replace missing teeth with dental implants. It is a text that relates one chapter to every other chapter and integrates common threads among science, clinical experience and future concepts. This book consists of 23 chapters divided into five sections. We believe that, *Implant Dentistry: A Rapidly Evolving Practice*, will be a valuable source for dental students, post-graduate residents, general dentists and specialists who want to know more about dental implants.

How to reference

In order to correctly reference this scholarly work, feel free to copy and paste the following:

Su-Gwan Kim (2011). Clinical Complications of Dental Implants, *Implant Dentistry - A Rapidly Evolving Practice*, Prof. Ilser Turkyilmaz (Ed.), ISBN: 978-953-307-658-4, InTech, Available from:
<http://www.intechopen.com/books/implant-dentistry-a-rapidly-evolving-practice/clinical-complications-of-dental-implants>

INTECH
open science | open minds

InTech Europe

University Campus STeP Ri
Slavka Krautzeka 83/A
51000 Rijeka, Croatia
Phone: +385 (51) 770 447
Fax: +385 (51) 686 166
www.intechopen.com

InTech China

Unit 405, Office Block, Hotel Equatorial Shanghai
No.65, Yan An Road (West), Shanghai, 200040, China
中国上海市延安西路65号上海国际贵都大饭店办公楼405单元
Phone: +86-21-62489820
Fax: +86-21-62489821

© 2011 The Author(s). Licensee IntechOpen. This chapter is distributed under the terms of the [Creative Commons Attribution-NonCommercial-ShareAlike-3.0 License](https://creativecommons.org/licenses/by-nc-sa/3.0/), which permits use, distribution and reproduction for non-commercial purposes, provided the original is properly cited and derivative works building on this content are distributed under the same license.

IntechOpen

IntechOpen