

Ultraviolet B (UVB) Phototherapy in the Treatment of Vitiligo

Kelly KyungHwa Park¹ and Jenny Eileen Murase^{1,2}

¹University of California San Francisco

Department of Dermatology, San Francisco, California

²Palo Alto Foundation Medical Group

*Department of Dermatology, Mountain View, California
USA*

1. Introduction

Vitiligo is a common, acquired pigmentary disorder of unknown pathogenesis that presents a therapeutic challenge to many dermatologists (Figure 1). Although surgery in the form of grafting or transplantation is generally the most definitive treatment option, these procedures are limited by concerns of post-procedure cosmesis. Photochemotherapy using psoralen and ultraviolet A (PUVA) therapy, topical and oral immunosuppressants, as well as cosmetic camouflage are also commonly employed with varying clinical efficacy. Phototherapy is a popular treatment option, which includes both of the generalized ultraviolet B (UVB) therapies, broadband UVB (BB-UVB) and narrowband UVB (NB-UVB). The UVB-based therapeutic modalities in development are targeted delivery of BB- and NB-UVB, monochromatic excimer light (MEL), microphototherapy, and combination therapy. In particular, the sophisticated devices that utilize MEL can emit coherent 308-nm radiation using the xenon chloride (XeCl) excimer laser or microphotography, while incoherent radiation can be supplied by various lamp and light systems. All of the UVB phototherapy modalities can be used in combination with topical or systemic agents, thus further expanding treatment options for vitiligo patients.

2. History

The use of ultraviolet (UV) irradiation was introduced into the field of dermatology in the 1800s after its Nobel Prize-winning application in lupus vulgaris (Roelandts, 2002). By 1928, UV radiation was used in the Goeckerman regimen as part of the classic crude coal tar and phototherapy treatment for psoriasis. Decades later in 1978, BB-UVB phototherapy was developed and used for psoriasis and pruritus. NB-UVB originated in Europe in 1988 indicated for psoriasis, and soon became widely used in the United States in the 1990s. Its innovative use in vitiligo came nearly a decade later in 1997 (Wiskemann 1978; Westerhof and Nieuweboer-Krobotova, 1997). The pivotal study introducing NB-UVB use in vitiligo demonstrated that more patients undergoing NB-UVB had repigmentation of vitiligo patches than those who underwent PUVA photochemotherapy (67% vs. 46%) (Westerhof and Nieuweboer-Krobotova, 1997). Since then, the use of UVB for vitiligo has become

commonplace, and new technologic developments in UVB therapy are continuously underway. The use of MEL with the excimer laser was first described in 1997 (Bonis, Kemeny et al., 1997).

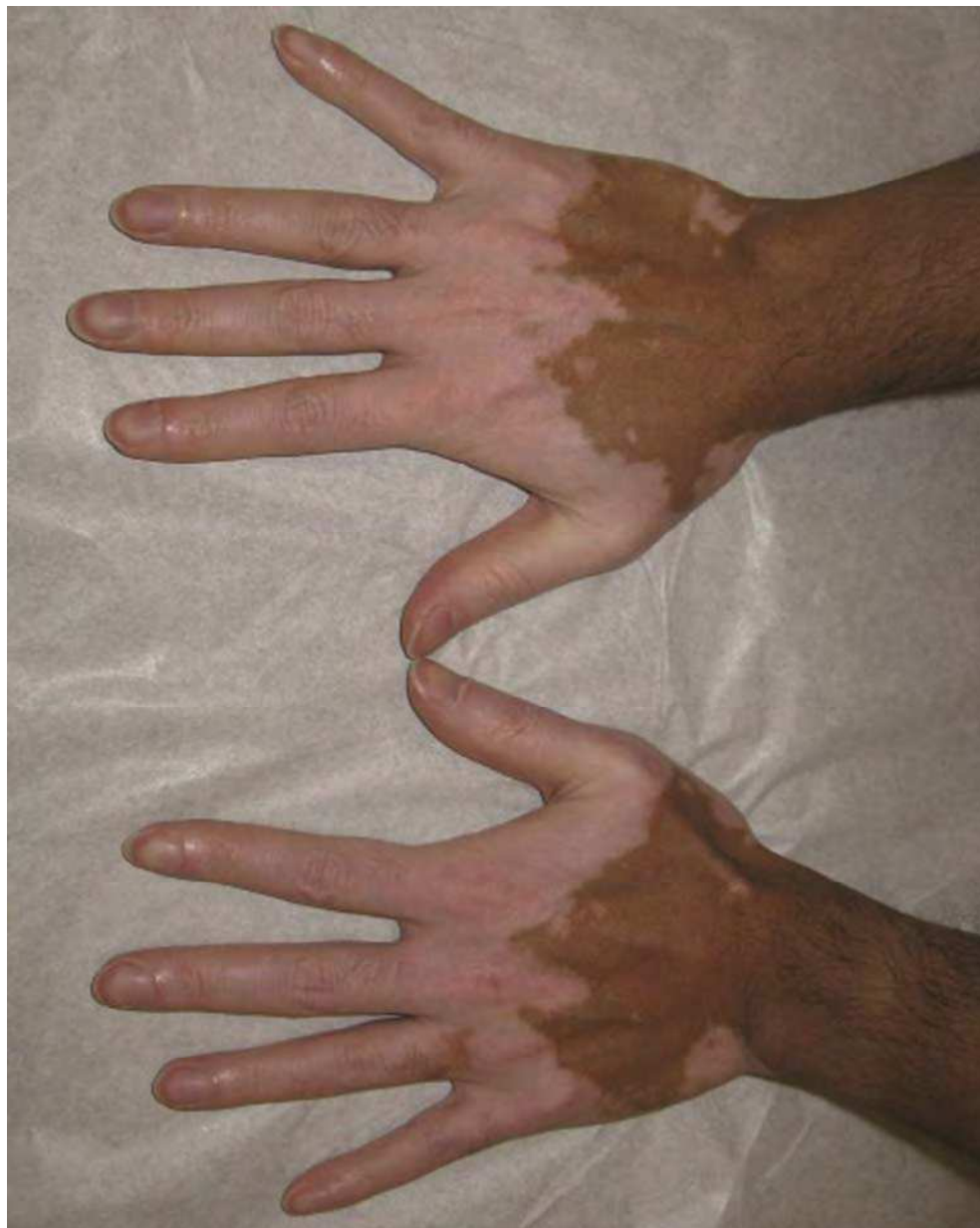


Fig. 1. Vitiligo of the hands.

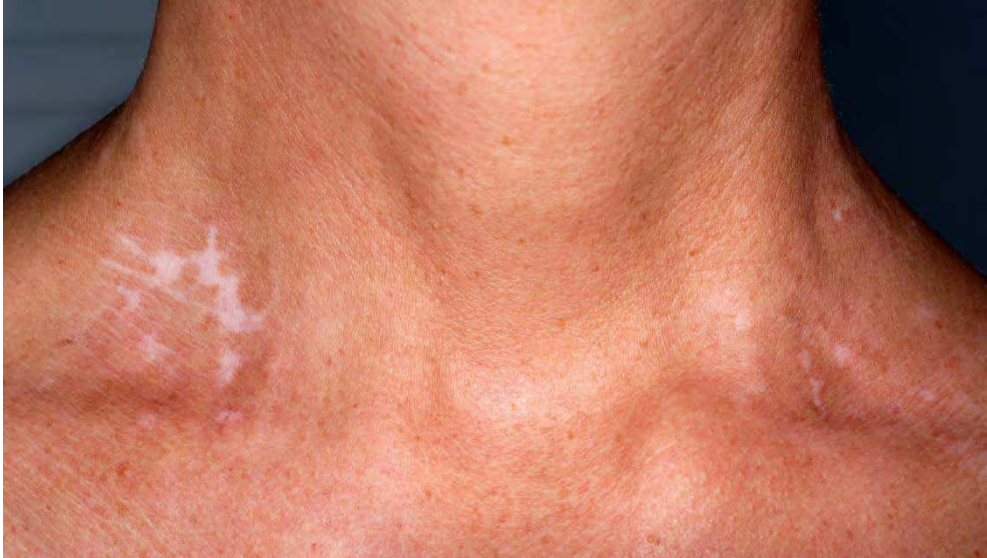

Fig. 2. Near complete repigmentation of vitiligo patches with NB-UVB treatment.

3. Theory and mechanism of action

UVB phototherapy consists of the use of artificial light without the use of adjunct photosensitizing agents. It is used for a variety of dermatological conditions, including psoriasis, atopic dermatitis and other eczematous disorders, pruritus, graft-versus-host-disease, lichen planus, and seborrheic dermatitis, among others. In vitiligo, UVB phototherapy ideally results in repigmentation, disease control, and prevention of progression of vitiligo through its immunosuppressive and immunomodulatory properties. UVB is available for use in vitiligo as BB-UVB (290-320 nanometers, nm), NB-UVB (310-312 nm), and monochromatic excimer light (MEL, 308 nm). Although the action spectrum or wavelength(s) specifically targeting vitiligo has yet to be determined, both BB- and NB-UVB as well as MEL have been demonstrated to be clinically effective.

The mechanism of how UVB works in vitiligo is unknown. It is established that distinct UVB radiation wavelengths target particular chromophores in the skin, in particular keratinocytes and melanocytes in the epidermis and fibroblasts in the dermis, and facilitate the therapeutic mechanisms of the light depending on chromophore type and function. In the case of UVB, these include apoptosis induction, T-cell depletion, decreased antigen presentation, and the ability to regulate inflammatory mediators and cytokines (Novak, Bonis et al., 2002; Novak, Berces et al., 2004; Weichenthal and Schwarz, 2005).

UV, in particular, NB-UVB, is presumed to stimulate dopa-lacking amelanotic melanocytes in the outer root sheaths of hair follicles to produce melanin (Cui, Shen et al., 1991; Norris, Horikawa et al., 1994). It also activates melanocyte migration to adjacent depigmented areas, causing perifollicular repigmentation (Cui et al., 1991; Norris et al., 1994). Furthermore, NB-UVB and MEL (coherent and incoherent) were both found to upregulate endothelin-1 (ET-1) release from keratinocytes, which is thought to play a role in UVB-related melanocyte synthesis and migration (Noborio, Kobayashi et al., 2006). This action is directly dependent on UVB radiation dose, and may account for the particular effectiveness of the 308 nm and

310-312 nm wavelengths (Noborio, Kobayashi et al., 2006). Also, the 308 nm wavelength of MEL is most specific for lymphocyte DNA alteration (de With and Greulich, 1995). The quantitative induction of T-cell apoptosis is greater with excimer laser (MEL) than with conventional BB- or NB-UVB phototherapies. It is thought that the capability to induce T-cell apoptosis is an indicator of clinical efficacy (Ozawa, Ferenczi et al., 1999). Furthermore, keratinocytes may be influenced to release other unidentified cytokines and factors, which suggests that UVB functions as an immunomodulator. This may support the theory of an autoimmune component in the pathogenesis of vitiligo.

4. BB-UVB phototherapy

Conventional BB-UVB phototherapy utilizes an artificial light source that emits in the radiation spectrum that extends from 280-320 nm (Cui, Shen et al., 1991; Norris, Horikawa et al., 1994). The pilot study of BB-UVB in vitiligo was reported in 1990, and observed that 57% of treated patients had excellent (>75%) repigmentation of vitiligo patches in a 52 week treatment period (Koster W, 1990). The investigators also noted its particular efficacy in facial lesions as well in skin types V and VI (Koster W, 1990). Little definitive evidence purports the use of BB-UVB in vitiligo, primarily due to the dominant and successful use of NB-UVB.

BB-UVB with vitamin supplementation was found to be effective in actively spreading vitiligo for inducing repigmentation when given 2-3 times weekly for 6-8 weeks (Don, Iuga et al., 2006). Although the role of vitamin supplementation was not substantiated in the outcome, this particular trial suggests that BB-UVB can be an effective treatment for vitiligo (Don, Iuga et al., 2006). Targeted BB-UVB and MEL were found to have nearly equal rates and degrees of repigmentation when evaluated after 8 treatments (Asawanonda, Kijluakiat et al., 2008).

Nearly 60% of patients had 80-100% repigmentation after 70 BB-UVB treatment sessions, a rate comparable to topical PUVA (55.6%) and NB-UVB (54.2%) treated patients in the same trial (El-Mofty, Mostafa et al., 2010). Other studies suggest that BB-UVB is less effective or had no effect compared to PUVA and NB-UVB phototherapy for the treatment of vitiligo (Hartmann, Lurz et al., 2005; Gawkrödger, Ormerod et al., 2008). Furthermore, targeted BB-UVB therapy was found to have limited effectiveness in vitiligo, and treatment-responsive areas were limited to the face (Akar, Tunca et al., 2009).

5. NB-UVB phototherapy

NB-UVB phototherapy utilizes the 311-313 nm radiation spectrum, which excludes the shorter and more erythrogenic wavelengths of BB- and natural (sunlight) UVB. It has been shown to be more effective than PUVA photochemotherapy, without the adverse side effect profile of psoralen (Table 1) (Bhatnagar, Kanwar et al., 2007; Yones, Palmer et al., 2007). Evidence-based guidelines suggest that NB-UVB should be used instead of PUVA in both adult and pediatric patients who have treatment-resistant disease, widespread involvement (BSA > 10-20%), or disease that severely affects quality of life (Ostovari, Passeron et al., 2004; Gawkrödger, Ormerod et al., 2008; Silverberg, 2010). Furthermore, NB-UVB is suggested as the best choice for generalized disease, with topical immunomodulators (*i.e.*, pimecrolimus cream or tacrolimus ointment) reserved for localized patches (Stinco, Piccirillo et al., 2009). Prognosis is significantly better in those with generalized vitiligo without acral involvement, and reportedly in females (El-Mofty, Mostafa et al., 2010). Less relevant predictors of clinical outcome include skin type, age, and previous response to phototherapy and other vitiligo treatments.

Author(s)	Country of Origin	Study Design	Number of Patients (Completing)	Frequency (per week)	Duration (weeks)	>75% Repigmentation	>50% Repigmentation	Notes
Yones, Palmer et al. 2007	England	Double-blind randomized	25				64%	Median number of treatments 97
Sitek, Loeb et al. 2007	Norway	Followup trial	31(11)		<52	35%		>75% repigmentation 2 years after treatment: 16%
Percivalle, Piccino et al. 2008	Italy	Longterm	53	2	<52	3.8%	32.05% (50-74%)	
Westerhof and Nieuweboer-Krobotova 1997	Netherlands	Open trial	51	2	12, 24, 36, 52	8 (12 weeks), 42 (24%), 49 (36%), 63 (52 weeks)		
Njoo, Bos et al. 2000	Netherlands	Open uncontrolled	51	2	<52	53		
Natta, Somsak et al. 2003	Thailand	Retrospective open analysis	60	2	20-104	33	42%	
Samsom Yashar, Gielczyk et al. 2003	United States	Retrospective	77(71)	2-3		39		In 19-123 treatments, average 62
Hamzavi, Jain et al. 2004	Canada	Prospective randomized controlled	22	3	24			43% mean repigmentation, significant repigmentation by 8 weeks
Dogra and Kanwar 2004	India	Open uncontrolled	26(20)	3	<52	75		Mild-moderate: 20%
Kanwar, Dogra et al. 2005	India	Open uncontrolled	17(14)	3	<52	71.4		Mild-moderate: 14.3%
Chen, Hsu et al. 2005	Taiwan	Retrospective	72	2-3	<52	12.5	50-75%: 33.3%	7% with phototoxicity (burns)
Brazzelli, Prestinari et al. 2005	Italy	Open uncontrolled	10	2-3	<24	50		Average 48 treatments
Anbar, Westerhof et al. 2006	Netherlands	Open trial	97	2	32	48		76.3% face
Nicolai-dou, Antoniou et al. 2007	Greece	Open uncontrolled	70	2	<78	34.4% face, 7.4% body	50-75%: 13.1% face, 3% body	
Casacci, Thomas et al. 2007	France	Investigator blinded randomized halfside comparison	21	2	24	6%	31%	Less effective than MEL in head-to-head comparison

Table 1. NB-UVB Phototherapy Studies in Vitiligo

NB-UVB for vitiligo is most effective on the face and neck, followed by the trunk, and then upper extremities (Figure 3). Acral regions including the lower extremities, palms, and soles are more resistant to treatment. The reason has yet to be elucidated, but the regional density of hair follicles, which are reservoirs for melanocytes, are thought to play a role (Stinco, Piccirillo et al., 2009). In general, the repigmentation patterns in patients treated with NB-UVB are, in descending order, perifollicular (51.3%), then marginal, diffuse, and combined (Yang, Cho et al., 2010). However, the marginal pattern was observed to be the most common when >75% repigmentation occurred by 12 weeks of treatment (Yang, Cho et al., 2010).

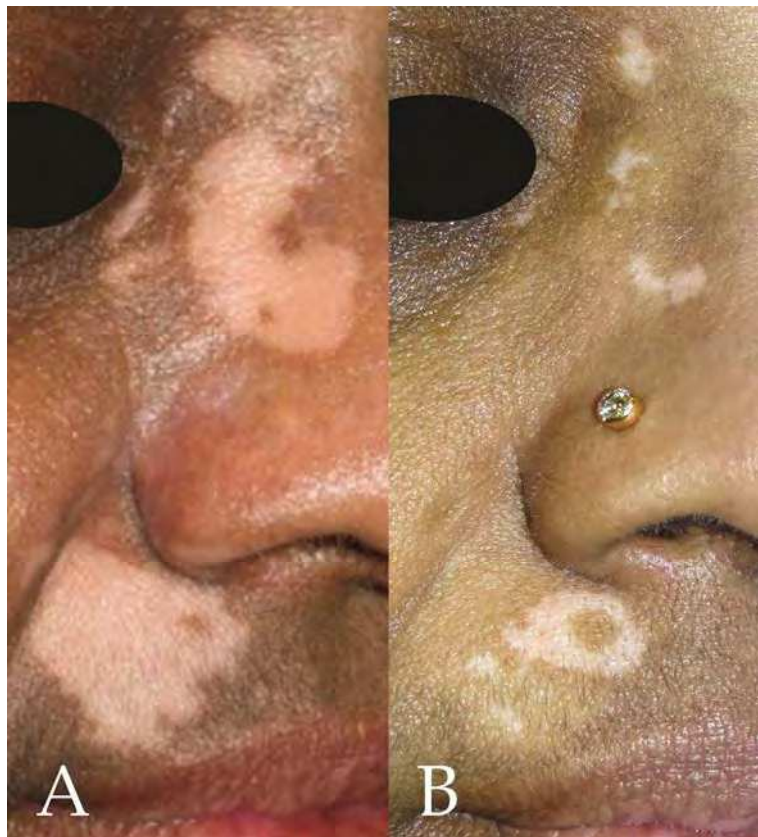

Fig. 3. A patient with facial vitiligo was treated with NB-UVB phototherapy three times weekly. A. The patient prior to initiating treatment. The patient was then started at 200 mJ based on standard protocol for Fitzpatrick skin type III. B. The patient with notable repigmentation after treatment 56 at a dose of 1001 mJ.

Patients should be counseled that, although these conventional phototherapies are quite effective for the head and neck region, they are less effective in the acral regions, which are commonly resistant areas, and in particular, the hands and feet. In addition, possible side effects, such as a predisposition to the development of skin malignancy, should be

discussed. Phototherapy is ideal in patients who cannot tolerate or have failed other vitiligo treatments, elderly and pediatric patients, pregnant or lactating patients, and those with renal or hepatic dysfunction. It does not require systemic photosensitizers as in PUVA or other photochemotherapies. Administration is less cumbersome than PUVA, without the use of uncomfortable special protective eyewear that PUVA requires.

Home UVB therapy may be a valuable and convenient option for select patients. Patient-reported outcomes for home NB-UVB therapy and outpatient NB-UVB therapy revealed that they show similar clinical efficacy and safety profiles (Wind, Kroon et al., 2010). Home NB-UVB is convenient and can be cost-effective in certain situations. However, more reliable long-term follow-up data is needed to further justify home UVB therapy.

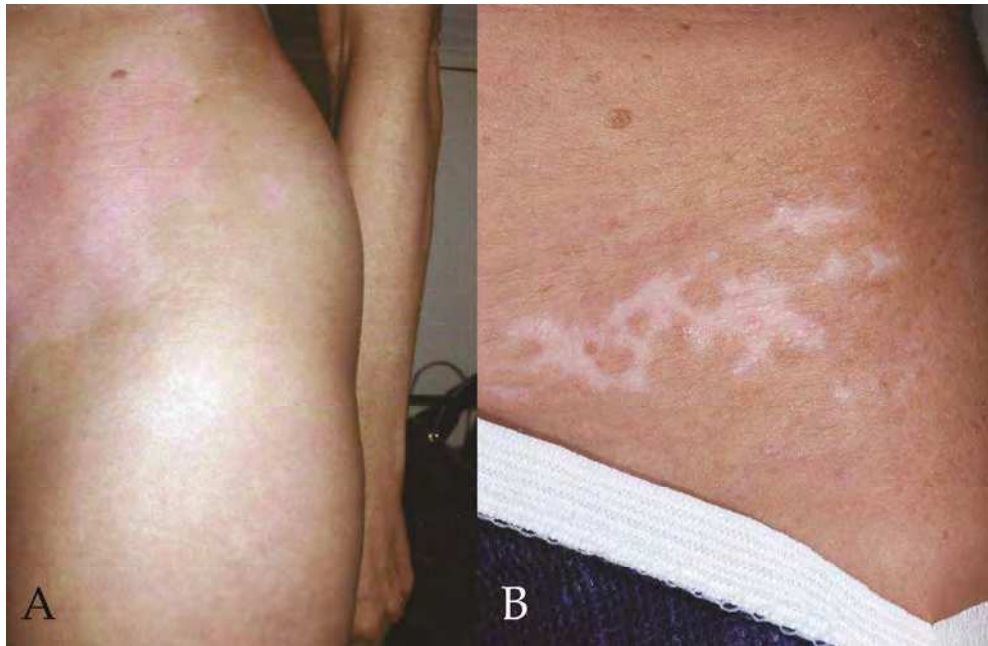

Fig. 4. A. Extensive vitiligo of the lower abdomen and hips. B. Repigmentation of vitiligo patches after 24 months of NB-UVB treatment.

6. Conventional UVB phototherapy administration and dosing

UVB phototherapy dosing is tailored to patient phototype (skin type). Other considerations include which and how much body surface area (BSA) is involved, the need for photoprotection of sensitive body areas such as the eyes or genitals, history of photosensitivity, use of photosensitizing drugs, previous UV irradiation history, and body surface area involvement, among other parameters. Both BB- and NB-UVB treatments are given in large whole-body chambers or cabins furnished with the designated high-intensity (BB- or NB-UVB) light tubes. NB-UVB should ideally occur three times a week with at least

24 hours (nonconsecutive days) in between treatments. The duration of treatment is often many months, and may be tapered down with time.

For both BB-UVB and NB-UVB, the starting, or induction, dose must be determined, which is generally the minimal erythema dose (MED). Then, between 50-70% of this MED, or erythrogenic dose, is used. After initial treatment, doses are increased by 5-20% of the previous dose if patient tolerates treatment without phototoxicity or pruritus. The MED may be difficult to determine in vitiligo due to small lesion sizes and the tedious testing process to determine MED. For NB-UVB treatment of vitiligo, patients can also be assumed to have Fitzgerald skin type I lesional skin, which has an MED of 400 millijoules per centimeters squared (mJ/cm²) and further dosing is determined from this number.

The treatment cap for number of treatments that Fitzpatrick skin types I-III may receive is arbitrarily set at 200 treatments. While there is no set limit for skin types IV-VI, the recommendation for number of treatments should be based on clinician discretion and patient consent (Gawkrodger, Ormerod et al., 2008). However, treatment caps have yet to be defined but based on our experience, long-term NB-UVB is safe. In children, disease control and repigmentation is achieved with biweekly treatments for 12 weeks and continues for 12 months. At this point, 80% of pediatric patients have stabilization of disease (Silverberg, 2010). Serial photography is recommended every 2-3 months to monitor disease progress, failure to respond, and safety, according to well-developed protocols for adults (Gawkrodger, Ormerod et al., 2008).

For NB-UVB, the dosing protocol the authors recommend from decades of use in a dedicated academic phototherapy center, skin type is always assumed to be Type I, with initial dosing at 170 mJ, then increasing by 30 mJ at a time as tolerated. Missed treatments require dosage adjustment depending on number of days or weeks missed (Table 2).

Number of Missed Days	Dosage Adjustment
1-7	Increase per skin type I
8-11	Hold dose constant
12-20	Decrease by 25%
21-27	Decrease by 50%
28 or more	Start over

Table 2. NB-UVB Dosage Adjustments for Missed Treatment Days

Monitoring for side effects is crucial. The patient may report symptoms including burning, tightness, pruritus, and pain, among other phototoxicity-related complaints. The clinician may notice erythema or exacerbation of disease on physical examination. Focal erythema and tenderness can be managed by shielding affected areas until symptoms remit. The development of marked pain or blistering is an indication to reduce the previous dose of radiation by 25% and subsequently cautiously increasing dosage when there is no further adverse reaction.

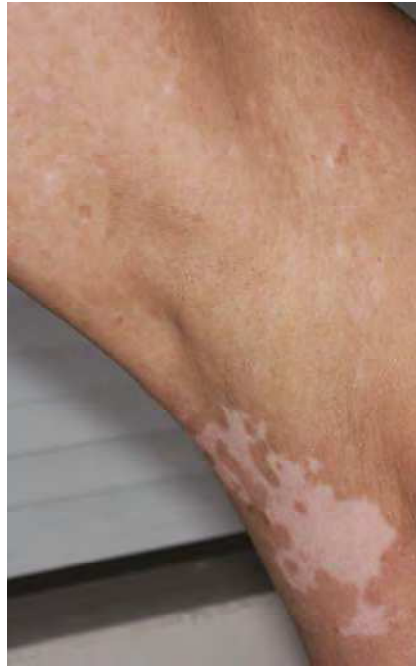

Fig. 5. Amelanotic patches of vitiligo in flexural areas undergoing involution NB-UVB therapy.

7. Monochromatic excimer light (MEL)

Xenon-chloride excimer (excited dimer) light is composed of the specific 308 nm wavelength, creating monochromatic radiation that is known as monochromatic excimer light, or MEL. The dimers are a halide (xenon) and noble gas (chloride) combination, which creates a high-energy unstable state, which is then translated into light radiation. It is clinically useful in the treatment of vitiligo, as well as other inflammatory skin diseases such as psoriasis, as well as mycosis fungoides. Sources of MEL include lamps, handheld devices, and in-office systems. These all emit MEL as *incoherent* light, similar to conventional UVB phototherapy in that it is nonselective for body treatment area and is non-targeted (as opposed to the excimer laser).

When a 308-nm MEL delivery system was used in vitiligo, half of lesions showed repigmentation at 2 weeks, and after an 8 week treatment period followed by a non-treatment 5 week observation period, all patients maintained their respective degrees of improvement (Table 3) (Chimento, Newland et al., 2008). In general, patients who respond to MEL do so at the beginning, otherwise they do not respond at all (Leone, Iacovelli et al., 2003). MEL has also successfully treated previously NB-UVB refractory disease, and has been shown to be more effective and quicker than conventional NB-UVB (Leone, Iacovelli et al., 2003; Le Duff, Fontas et al., 2010). In a head-to-head study in which patients served as their own controls, the 308-nm excimer laser and MEL lamp had similar efficacy, although the lamp induces more erythema (Le Duff, Fontas et al., 2010). In addition, the use of lower power density reduces the risk of adverse events.

Author(s)	Country of Origin	Study Design	Number of Patients (Completing)	Number of Patches	Frequency (per week)	Duration (weeks)	>75% Repigmentation	>50% Repigmentation	Notes
Saraceno, Nistico et al. 2009	Italy	Open prospective	48(45)		1	12	62.5% (+ PO vitamin E) 56.25% (+ khellin 4% ointment)	12.5 (50-75%) 31.25%	Control group 18.75% (50-75) (+ PO vitamin E) Repigmentation in in 50% of patients at 2 weeks, maintained in follow-up period of 5 weeks 2.6% relapse rate in 2 year follow-up
Chimento, Newland et al. 2008	United States		10			10			
Xiang 2008	China		36 (active) 41 (stable)	91, 110			29.7 (active), 30.9% (stable)		
Lu-Yan, Wen-wen et al. 2006	China	Double blinded within patient controlled	38(35)	70	1	12	Excellent: 5.7% (+placebo), (+TAC 25.7%)		
Casacci, Thomas et al. 2007	France	Investigator blinded randomized half-side comparison	21		2	24	37.5%	25%	Superior to NB-UVB in head-to-head comparison
Le Duff, Fontas et al. 2010	France	Randomized monocentric	20(17)	104	2	12	38%	15%	Equal to excimer laser in head-to-head comparison

Table 3. MEL Phototherapy Studies in Vitiligo

The advantage of MEL includes the ability to irradiate larger body surface areas rather than the confined target areas of lasers and that it can be used to treat the entire body at once. It can also be customized to treat certain patches, has the perks of shorter treatment times, frequency, and total treatment duration, which in turn can lead to increased patient compliance (Leone, Iacovelli et al., 2003).

8. Excimer laser

The use of laser (*light amplification by stimulated emission of radiation*) technology in dermatology was introduced in the mid-1980s and has since been applied to vitiligo therapy. The specific 308 nm wavelength utilized by MEL also comes in a *coherent*, or targeted format, which is administered by laser.

The excimer laser is a well-tolerated, effective treatment that induces quicker repigmentation than other forms of vitiligo therapy (Spencer, Nossa et al., 2002). It is thought to share a similar mechanism of action as other UVB therapies, as evidenced by treated vitiligo patches that undergo the same repigmentation patterns observed in conventional NB-UVB phototherapy (Yang, Cho et al., 2010).

Vitiligo patch location and duration of disease are thought to be factors in the efficacy and response to excimer laser (Hofer, Hassan et al., 2005; Zhang, He et al., 2010). The face, neck, and to a lesser extent, the trunk, are more sensitive, or responsive, to laser treatment than more resistant areas which have been identified as the acral areas of the extremities and bony prominences (Ostovari, Passeron et al., 2004). Clinical outcome is dependent on the total number of laser treatments, not treatment frequency. However, repigmentation is induced quickest with increased frequency: optimal treatment occurs three times weekly, followed by twice weekly treatments (Hofer, Hassan et al., 2005; Shen, Gao et al., 2007). Once weekly treatment is also acceptable and effective, and may increase patient compliance due to decreased clinic visit frequency (Xiang, 2008). The 308-nm excimer laser is also effective and safe treatment for pediatric patients, in particular those with localized disease (Cho, Zheng et al., 2011).

Compared with conventional NB-UVB phototherapy, the excimer laser is not only more efficacious, allowing for lower cumulative dosing and faster clearance, but also spares normal unaffected skin from carcinogenic UV radiation exposure. The laser light intensity is much greater than conventional NB-UVB phototherapy and its energy is emitted in nanoseconds (rather than minutes). It is suggested that the increased efficacy in inducing T-cell apoptosis allows for greater clinical efficacy of the laser than other conventional light therapies.

Side effects are generally well-tolerated, and are usually due to phototoxicity, *i.e.*, erythema, hyperpigmentation, erosions, and blisters (Housman, Pearce et al., 2004). Patients with Fitzpatrick skin type 1 may be prone to frequent blistering, especially with the usage of supra-erythmogenic laser therapy. Subsequent conservative dosing, may not achieve any more benefit than general UVB phototherapy regimens (Gattu, Pang et al., 2010). In addition, it can be used for patients with phobia of the light box or phototherapy unit, and may be more tolerable for children (Lapidoth, Adatto et al., 2007). However, the excimer laser is currently limited to outpatient use, which requires frequent clinic visits over a short time duration, which can lead to low patient compliance (Kemeny, Csoma et al., 2010).

Authors	Country of Origin	Number of Patients (Completing Study)	Number of Patches	Frequency (per week)	Duration (weeks)	Repigmentation Results	Notes
Zhang, He et al. 2010	China	36	44	2	15	>75%: 61.4%	30 treatments
Sassi, Cazzaniga et al. 2008	Italy	84(76)		2	12	100%: 4.7% (+steroid 21.4%) >75%: 16.6% (+steroid 21.4%)	Monotherapy compared with combination topical steroid
Baltas, Csoma et al. 2002	Hungary	6(4)	4	2	24	>75%: 75%	No depigmentation at 3 month follow-up
Hadi, Spencer et al. 2004	United States	32	55	2	15	>75%: 51%	Results seen at 30 treatments; no depigmentation at 1 month follow-up
Leone, Iacovelli et al. 2003	Italy	37(36)		2	<24	>75%: 12% at 12 weeks, 18% at 24 weeks 50+ %: 21% at 12 weeks, 16% at 24 weeks	
Al-Otaibi, Zadeh et al. 2009	Kuwait	34(29)		2		>75%: 20.7% 43.75% face 33.4% trunk 50+ %: 41.4%	25 treatments
Cho, Zheng et al. 2011	South Korea	30(30)	40	2	13	>75%: 12.5%	
Spencer, Nossa et al. 2002	United States	12	6	3	4	82%: 11 patches in 12 treatments 57%: 23 patches in +6 treatments	Time to repigmentation 2-4 weeks
Taneja, Trehan et al. 2003	United States	18	15	2	30	>75%: 33%	100% face
Choi, Park et al. 2004	South Korea		50	2	15	>75%: 15.7%	33% face and neck
Ostovari, Passeron et al. 2004	France	35	31	2	12	>75%: 27%	57% face, neck, trunk
Esposito, Soda et al. 2004	Italy	24	24	2	36	>75%: 29%	

Authors	Country of Origin	Number of Patients (Completing Study)	Number of Patches	Frequency (per week)	Duration (weeks)	Repigmentation Results	Notes
Hong, Park et al. 2005	South Korea	8	8	2	10	>75%: 0%	
Hofer, Hassan et al. 2006	Austria	25	24	3	6-10	>75%: 25% (face, trunk, arm, leg)	
Hadi, Timio et al. 2006	United States	97	221			100%: 25.5% >75%: 50.6% >50%: 64.3%	
Passeron, Ostovari et al. 2004	France	14	20 monotherapy, 23 + Tacrolimus	2	12	>75%: 20%	>75%: 70% (+ Tacrolimus)
Kawalek, Spencer et al. 2004	United States	8	6	3	8-10	>75%: 20%	>75%: 50% (+ Tacrolimus)
Le Duff, Fontas et al. 2010	France	20(17)	104	2	12	>75%: 42%, >50%: 15%	Equal to MEL in head-to-head comparison

Table 4. Excimer Laser Phototherapy Studies in Vitiligo

9. Microphototherapy

Focused microphototherapy was developed in 1999, and utilizes UVB light in the 280-315 nm spectrum. This form of UVB therapy uses a dark-colored pad with perforations to focus light only on vitiligo patches using an optical fiber and hood. Its efficacy in vitiligo has shown promising results (Lotti, Menchini et al., 1999; Lotti, Tripo et al., 2009). Treatment protocol begins with daily treatment for a week, then tapered down to a few times a week, and finally, twice monthly. Half of patients show a moderate response to treatment, and a quarter of patients have excellent (>75%) repigmentation. However, focused microphototherapy is laborious, requiring expensive tools and training to perform the procedures.

10. Combination therapy

The UVB phototherapy modalities can be combined with other vitiligo treatments. These include combinations with topical preparations including immunomodulators such as pimecrolimus and tacrolimus, immunosuppressants such as corticosteroids, and vitamin D analogues. Systemic medications can also be part of combination therapy, and these include supplements such as antioxidants as well as systemic corticosteroids.

10.1 Pimecrolimus

Pimecrolimus is a calcineurin inhibitor and immunomodulator available as a cream. It is generally well-tolerated and safe for long-term use. This topical formulation is used once to twice daily on vitiligo patches. Pimecrolimus inhibits T cell activation; however, data on melanocyte function are lacking (Dawid, Veensalu et al., 2006). Although already useful as monotherapy, it is also able to enhance phototherapy efficacy. NB-UVB works better if combined with pimecrolimus 1% cream (64.3%) rather than photomotherapy (25.1%) on facial lesions (Elgoweini and Nour El Din, 2009). Pediatric patients also tolerate this combination well, with excellent repigmentation on the face, and with varying degrees of effectiveness on all body parts (Elgoweini and Nour El Din, 2009). Side effects are tolerated well and generally limited to phototoxic effects such as mild discomfort, neurosis, and erythema. Furthermore, pimecrolimus may sometimes exacerbate symptoms after phototherapy, which include blistering and pruritus (Hui-Lan, Xiao-Yan et al., 2009).

10.2 Tacrolimus

Tacrolimus, like pimecrolimus, is a calcineurin inhibitor and immunomodulator in an ointment formulation that is used once to twice daily for vitiligo and is an option for long-term management. It is empirically used in vitiligo due to its ability to increase melanocyte proliferation as well as stem cell factors, and down-regulate a number of interleukins, interferon-gamma, tumor necrosis factor-alpha, and granulocyte monocyte-colony stimulating factor (Grimes, Soriano et al., 2002; Lan, Chen et al., 2005). Tacrolimus ointment (0.1%) and NB-UVB combination treatment is more effective than NB-UVB monotherapy and the effect of tacrolimus is dose-dependent (Nordal, Guleng et al., 2011). The efficacy of tacrolimus and excimer laser is also additive; repigmentation is achieved quicker with total lower cumulative laser dosage (Passeron, Ostovari et al., 2004). Side effects due to tacrolimus-phototherapy dual therapy include itching, formation, erythema, and soreness.

Either pimecrolimus or tacrolimus with UVB as combination therapy are best used in sun-exposed areas due to better treatment outcomes with combination therapy than non-exposed skin (Stinco, Piccirillo et al., 2009). There is a non-significant difference in efficacy between pimecrolimus and tacrolimus, although pimecrolimus may be slightly more effective due to its lipophilic properties that enable it to penetrate depigmented epidermis better than tacrolimus (Stinco, Piccirillo et al., 2009).

10.3 Vitamin D analogues

Calcipotriol, or calcipotriene, and tacalcitol are synthetic vitamin D3 (calcitriol) analogues which bind to vitamin D receptors in the epidermis and affect melanocyte and keratinocyte maturation. These receptors are also on T cells. Studies found that combination calcipotriol and NB-UVB therapy was not superior to NB-UVB alone (Ada, Sahin et al., 2005; Hartmann, Lurz et al., 2005). Similar findings were found when calcipotriene ointment and NB-UVB three times weekly were combined (Kullavanijaya and Lim, 2004). The combination of the 308 nm excimer laser and calcipotriol also did not seem to be superior to excimer laser alone in a small trial in patients who served as their own controls (Goldinger, Dummer et al., 2007). However, tacalcitol and 308 nm excimer laser treatment is superior to the laser alone; and allows for quicker improvement into vitiligo patches with lower cumulative dosing (Luyan, Wen-wen et al., 2006).

10.4 Corticosteroids

Topical corticosteroids have some value in vitiligo treatment but with the high risk of side effects, most commonly skin atrophy, as well as striae, erythema, and absorption near the eyes which poses a risk for glaucoma candidates (Gawkrodger, Ormerod et al., 2008). They should be reserved for short-term (< 2 months) use only. Recalcitrant vitiligo of the face and neck may benefit from the combination of excimer laser phototherapy with topical hydrocortisone 17-butyrate cream. This was observed to have induce >75% repigmentation of vitiligo involvement in 3 months (Sassi, Cazzaniga et al., 2008). Systemic immunosuppression to prevent progression of vitiligo using oral corticosteroids is not recommended for treatment due to the high risk of side effects, although used by some clinicians for active or rapidly progressing vitiligo. Furthermore, the additive effect of oral steroids to either NB- or BB-UVB phototherapy is minimal (Rath, Kar et al., 2008).

10.5 Vitamins & antioxidants

Supplemental vitamins and minerals are popular remedies and adjuncts for vitiligo therapy. It is thought that there is a relationship between vitiligo pathogenesis and oxidative stress (Gawkrodger, Ormerod et al., 2008). In conjunction with vitamin C (500mg twice daily), vitamin B12 (1,000 micrograms twice daily), and folic acid (5 mg twice daily), BB-UVB had a significant clinically efficacious outcome in actively spreading vitiligo. Vitamin supplementation was used hypothetically and the investigators could only imply that BB-UVB could be effective for vitiligo and the role of vitamins was unclear (Don, Iuga et al., 2006).

In combination with NB-UVB, oral vitamin E supplementation (400 IU) was shown to augment therapy by hypothetically preventing lipid peroxidation of melanocytes and reducing phototherapy-related erythema (Elgoweini and Nour El Din, 2009). The use of

vitamin A supplements has also been studied, but its use with NB-UVB is not supported (Elgoweini and Nour El Din, 2009).

10.6 L-phenylalanine

Phenylalanine (L-phenylalanine) supplementation is thought to supply precursors for melanin production. It is an essential amino acid that is the precursor to tyrosine in melanin synthesis by hydroxylation and thereby turns into melanin. Although naturally occurring in the diet, supplementation and UV radiation administration is said to have some clinical value in vitiligo without any reports of serious adverse effects (Schulpis, Antoniou et al., 1989).

10.7 Pseudocatalase

Pseudocatalase is a low molecular-weight manganese complex that serves as a substitute for naturally occurring catalase, which is thought to be inactivated in vitiligo by hydrogen peroxide accumulation in the epidermis. It is used in combination with UVB and climatotherapy, the latter which is the physical relocation of the patient to an area with a climate ideal or more suitable to a disease, in this case, vitiligo. Topically applied pseudocatalase and calcium used twice daily with twice weekly UVB phototherapy had a 90% repigmentation rate in an uncontrolled clinical trial. Initial results were seen in 8-16 weeks. In comparison to NB-UVB monotherapy, pseudocatalase and NB-UVB combination treatment showed clinically significant results, and was superior, with >75% of treatment sites with repigmentation vs. 70% in NB-UVB monotherapy (Schallreuter and Rokos, 2007). Side effects include pruritus, hyperhidrosis, and hyperpigmentation.

10.8 Tetrahydrocurcuminoid

Tetrahydrocurcuminoid (THC) is a derivative of curcumin (diferuloylmethane) which is a compound collected from the roots of tumeric (*Curcuma longa*). Based on the theory of combatting oxidative stress as a treatment for vitiligo, curcumin was the anti-inflammatory agent investigated. Curcuminoid cream (with the main active ingredient being THC) applied twice daily along with targeted NB-UVB twice weekly had higher repigmentation scores than phototherapy alone, although this was not statistically significant (Asawanonda and Klahan, 2010).

10.9 Khellin

Khellin is a furanochromone (dimethoxy-4, 9 methyl-7 oxo-5 5-H-Furo [3,2-G]-4H chromone) that is chemically similar to psoralen, which is the basis of PUVA photochemotherapy. It is clinically safer and less damaging to cellular DNA than psoralen. Khellin stimulates melanocyte activation, proliferation, migration, and melanogenesis (Carlie, Ntusi et al., 2003). Compared with MEL monotherapy, combination MEL and topical khellin 4% ointment had more > 75% repigmentation rates than MEL alone (25% vs. 56.25%) (Saraceno, Nistico et al., 2009). Response is best in acute patches of the face, neck, and knees (Saraceno, Nistico et al., 2009).

10.10 Microphototherapy

The use of 311-nm narrow-band microphototherapy has been augmented with tacrolimus 0.1% ointment twice a day, pimecrolimus 1% cream twice a day, betamethasone dipropionate 0.05% cream twice a day, calcipotriol ointment 50 micrograms/gram twice a

day, and 10% l-phenylalanine cream twice a day. Of these combinations, the 311-nm narrow-band UVB microfocused phototherapy with 0.05% betamethasone dipropionate cream gives the best repigmentation rate. In the latter treatment, the only short-term side effect is skin atrophy due to the corticosteroid cream (Lotti, Buggiani et al., 2008).

10.11 Surgery

Surgery may be an option for vitiligo treatment for disease refractory to conventional medical treatment. The use of split-skin grafting consists of harvesting the epidermis and part of the dermis from a normally concealed donor site (such as the inner thigh) for use on a mechanically manipulated (*e.g.*, via dermabrasion) recipient area. Use of the 308 nm excimer laser for 32 treatments that were initiated 2 weeks post-surgery had a 100% response rate in patients by the end of therapy. Follow-up after one year showed even greater improvement in recipient sites (Al-Mutairi, Manchanda et al., 2010).

Punch grafting followed by use of NB-UVB also results in better cosmetic outcome of surgical sites, with repigmentation in the majority of cases (Lahiri, Malakar et al., 2006). It is thought that adjunctive NB-UVB is an efficient, safe, and cost-effective addition to surgical procedures for vitiligo.

11. Adverse effects and long-term usage

Short-term adverse effects related to UVB phototherapy are mostly related to phototoxicity which includes burning, pruritus, xerosis, pain, blistering, as well as increased susceptibility to cutaneous herpes simplex virus infections. These can be managed with early identification and topical corticosteroids as well as the judicious use of systemic steroids and anti-inflammatory agents in serious cases. Overaggressive treatment resulting in phototoxic reactions (*i.e.*, erythema) can lead to koebnerization.

Long-term UVB exposure is associated with photodamage and photoaging, and is a carcinogen with the potential to increase long-term risk of malignancy (Gonzaga, 2009). At baseline, vitiligo patients with Fitzpatrick skin types I and II have a non-statistically significant increased risk of non-melanoma skin cancer than the general population; however, this is not reported in more pigmented skin types (type III and above) (Hexsel, Eide et al., 2009).

In Caucasian-based population studies, PUVA is an established risk factor for NMSC, particularly with long-term therapy in patients with skin types I-II patients (Stern and Laird, 1994). This risk has been appreciated as early as within a 2-year follow-up period (Stern and Laird, 1994). It is the strongest predictor of squamous cell carcinoma (SCC) risk, the latter of which is also influenced by male gender, having skin types I-II, residence in southern regions, as well as the use of high-dose methotrexate and/or cyclosporin (Lim and Stern, 2005). PUVA only modestly increases BCC risk, which is also increased by male gender and exposure to high dose tar and/or methotrexate. NMSC due to PUVA use is modestly increased with high UVB exposure (>300 treatments) limited to less than 100 PUVA treatments, however these appear on usually non-sun exposed anatomic sites (Lim and Stern, 2005). However, the carcinogenic risk of PUVA in non-Caucasians, in particular, Asian and Arabian-African populations, is not substantiated (Murase, Lee et al., 2005). The analysis of the effect of ethnicity on PUVA risk of 4,294 long-term non-Caucasian PUVA patients with at least a 5-year follow-up implied that pigmented skin and ethnic skin types may confer photoprotection (Murase, Lee et al., 2005). Therefore, although the carcinogenic risks of PUVA therapy must be seriously considered in Caucasian vitiligo patients, vitiligo patients with skin of color may consider PUVA therapy with more assurance.

Author	Country	Phototherapy Type	Number of Patients	Person Years	Duration of Follow-up	Number of Treatments (average)	Skin Type	Results
Jo, Kwon et al. 2010	Korea	NB-UVB	445	1274	34.4 months	33.6	III-V	No increased skin cancer risk
Black and Gavin 2006	England	NB-UVB	484			18	I-II (92%)	As expected per general population
Hearn, Kerr et al. 2008	Scotland	NB-UVB	4665	24,753	6 months – 22 years	29 (median)	I (23%), II (47%) III (27%)	NB-UVB monotherapy no increase in NM/SC or melanoma; NB-UVB + PUVA no increase in SCC or melanoma; BCC increase (27 vs. 14.1 in general population)
Man, Crombie et al. 2005	Scotland	NB-UVB	1908		4 years (median), <13 years	23 (median)	I-III (BCC patients)	No increase risk SCC or melanoma; excess BCC noted, but 60+ % were diagnosed at referral
Weischer, Blum et al. 2004	Germany	BB-UVB	69/195	BB-UVB 533	BB-UVB 68.3	BB-UVB 17.8	Only 2 patients with V noted	BB-UVB no increase NM/SC or MM
		NB-UVB	126/195	NB-UVB 726	NB-UVB 93.6	NB-UVB 44		NB-UVB no increase NM/SC; 1 case MM in first year of treatment
Lim and Stern 2005	United States	UVB	1154/ 1380	27,928	>14 years	403	I-II, III-V as refer-rence group	>300 vs <300: increase SCC IRR 1.37, increase BCC 1.45
		PUVA	1380	27,928	>14 years		I-II, III-V as refer-rence group	PUVA <100 + UVB (>300): increase SCC IRR 2.75, increase BCC 3
Pittelkow, Perry et al. 1981	United States	UVB	280		25 years			No increased risk NM/SC
Larko and Swanbeck 1982	Sweden	UVB	85					Prevalence premalignant and malignancy cutaneous malignancies: 5.9% in treated vs. 10.1% in controls

Table 5. Phototherapy Follow-up in Dermatology Patients and Carcinogenic Risk

When comparing UVB and PUVA carcinogenic risk, a single PUVA increases risk 7 times more than a single UVB treatment (Lim and Stern, 2005). Even with a history of PUVA therapy, patients who had less than 300 treatments of UVB had no appreciable increase in NMSC risk (Lim and Stern, 2005). Available data on NB-UVB therapy has not consistently identified a significant increase in NMSC when compared to the general population (Table 4). The majority of follow-up data was primarily taken from Caucasian populations, but the same conclusion has been drawn in non-Caucasians with skin types III-V (Jo, Kwon et al., 2010). An increased risk of BCC was noted in two Scottish studies, one with NB-UVB monotherapy, and the other with a history of both NB-UVB and PUVA usage (Stern and Laird, 1994; Man, Crombie et al., 2005). However, the temporal relationship between tumor diagnosis and phototherapy makes a relationship between therapy and cancer unlikely in either study (Stern and Laird, 1994; Man, Crombie et al., 2005). In addition, it is common to use topical pimecrolimus and/or tacrolimus as adjuncts to NB-UVB. Topical pimecrolimus and tacrolimus have not been found to increase risk of NMSC in adults. Therefore, even in combination with NB-UVB, there should be no cumulative carcinogenic effect. Therefore, UVB, in particular NB-UVB, may be the phototherapy option with the least carcinogenic risk in all skin types.

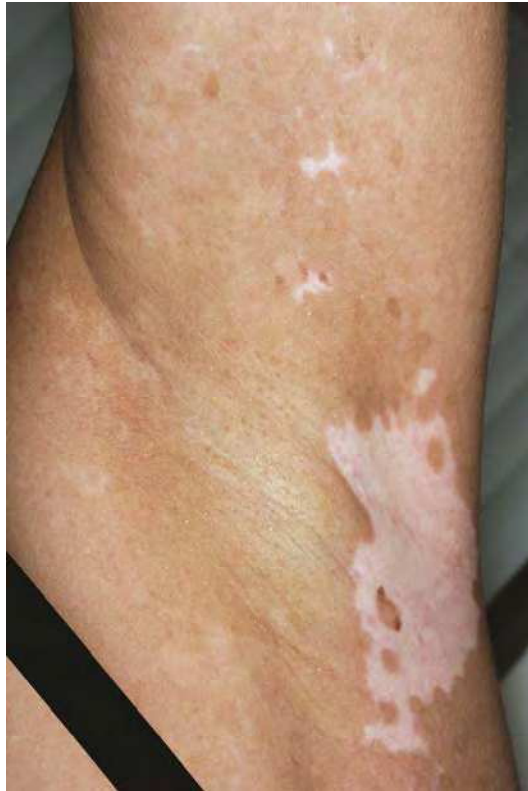

Fig. 6. NB-UVB is an effective treatment modality for vitiligo. Short term adverse effects are primarily related to phototoxicity. Long-term carcinogenic risk may not differ greatly from the general population.

Due to lack of long-term phototherapy research data specifically in vitiligo, it is difficult to wholly substantiate any claims regarding potential risk. Available phototherapy follow-up data was drawn from patients treated with a variety of photoresponsive dermatoses, which includes vitiligo, despite lack of quantification of vitiligo cases. Further research specifically on carcinogenic risk in vitiligo is needed.

12. Conclusion

Although multiple management options exist for vitiligo, UVB phototherapy is generally the treatment of choice as it is not only effective but has a favorable risk-to-benefit ratio. Conventional BB- and NB-UVB is widely available and useful particularly in widespread disease, although NB-UVB has been more extensively studied with proven efficacy. The development of MEL has provided options for both generalized and limited disease and is available in a variety of treatment systems. MEL has also been applied to laser therapy, which is growing in popularity due to the benefits of quicker treatment duration, increased efficacy, and a better risk-to-benefit ratio compared to conventional phototherapy techniques. Combination therapies are also useful and may provide quicker repigmentation and treat vitiligo with an additive mechanism of action than UVB phototherapy. Advances in technology may lead to the continuing use of UVB phototherapy as a treatment for vitiligo through the development of sophisticated devices and delivery systems as well as innovative application methods. These will provide increased therapeutic options for all vitiligo patients, particularly those with refractory disease.

13. References

- Ada, S., S. Sahin, et al. (2005). No additional effect of topical calcipotriol on narrow-band UVB phototherapy in patients with generalized vitiligo. *Photodermatol Photoimmunol Photomed* 21(2): 79-83.
- Akar, A., M. Tunca, et al. (2009). Broadband targeted UVB phototherapy for localized vitiligo: a retrospective study. *Photodermatol Photoimmunol Photomed* 25(3): 161-163.
- Al-Mutairi, N., Y. Manchanda, et al. (2010). Long-term results of split-skin grafting in combination with excimer laser for stable vitiligo. *Dermatol Surg* 36(4): 499-505.
- Al-Otaibi, S. R., V. B. Zadeh, et al. (2009). Using a 308-nm excimer laser to treat vitiligo in Asians. *Acta Dermatovenerol Alp Panonica Adriat* 18(1): 13-19.
- Anbar, T. S., W. Westerhof, et al. (2006). Evaluation of the effects of NB-UVB in both segmental and non-segmental vitiligo affecting different body sites. *Photodermatol Photoimmunol Photomed* 22(3): 157-163.
- Asawanonda, P., J. Kijluakiat, et al. (2008). Targeted broadband ultraviolet b phototherapy produces similar responses to targeted narrowband ultraviolet B phototherapy for vitiligo: a randomized, double-blind study. *Acta Derm Venereol* 88(4): 376-381.
- Asawanonda, P. and S. O. Klahan (2010). Tetrahydrocurcuminoid cream plus targeted narrowband UVB phototherapy for vitiligo: a preliminary randomized controlled study. *Photomed Laser Surg* 28(5): 679-684.
- Baltas, E., Z. Csoma, et al. (2002). Treatment of vitiligo with the 308-nm xenon chloride excimer laser. *Arch Dermatol* 138(12): 1619-1620.

- Bhatnagar, A., A. J. Kanwar, et al. (2007). Comparison of systemic PUVA and NB-UVB in the treatment of vitiligo: an open prospective study. *J Eur Acad Dermatol Venereol* 21(5): 638-642.
- Black, R. J. and A. T. Gavin (2006). Photocarcinogenic risk of narrowband ultraviolet B (TL-01) phototherapy: early follow-up data. *Br J Dermatol* 154(3): 566-567.
- Bonis, B., L. Kemeny, et al. (1997). 308 nm UVB excimer laser for psoriasis. *Lancet* 350(9090): 1522.
- Brazzelli, V., F. Prestinari, et al. (2005). Useful treatment of vitiligo in 10 children with UV-B narrowband (311 nm). *Pediatr Dermatol* 22(3): 257-261.
- Carlie, G., N. B. Ntusi, et al. (2003). KUVA (khellin plus ultraviolet A) stimulates proliferation and melanogenesis in normal human melanocytes and melanoma cells in vitro. *Br J Dermatol* 149(4): 707-717.
- Casacci, M., P. Thomas, et al. (2007). Comparison between 308-nm monochromatic excimer light and narrowband UVB phototherapy (311-313 nm) in the treatment of vitiligo--a multicentre controlled study. *J Eur Acad Dermatol Venereol* 21(7): 956-963.
- Chen, G. Y., M. M. Hsu, et al. (2005). Narrow-band UVB treatment of vitiligo in Chinese. *J Dermatol* 32(10): 793-800.
- Chimento, S. M., M. Newland, et al. (2008). A pilot study to determine the safety and efficacy of monochromatic excimer light in the treatment of vitiligo. *J Drugs Dermatol* 7(3): 258-263.
- Cho, S., Z. Zheng, et al. (2011). The 308-nm excimer laser: a promising device for the treatment of childhood vitiligo. *Photodermatol Photoimmunol Photomed* 27(1): 24-29.
- Choi, K. H., J. H. Park, et al. (2004). Treatment of Vitiligo with 308-nm xenon-chloride excimer laser: therapeutic efficacy of different initial doses according to treatment areas. *J Dermatol* 31(4): 284-292.
- Cui, J., L. Y. Shen, et al. (1991). Role of hair follicles in the repigmentation of vitiligo. *J Invest Dermatol* 97(3): 410-416.
- Dawid, M., M. Veensalu, et al. (2006). Efficacy and safety of pimecrolimus cream 1% in adult patients with vitiligo: results of a randomized, double-blind, vehicle-controlled study. *J Dtsch Dermatol Ges* 4(11): 942-946.
- de With, A. and K. O. Greulich (1995). Wavelength dependence of laser-induced DNA damage in lymphocytes observed by single-cell gel electrophoresis. *J Photochem Photobiol B* 30(1): 71-76.
- Dogra, S. and A. J. Kanwar (2004). Narrow band UVB phototherapy in dermatology. *Indian J Dermatol Venereol Leprol* 70(4): 205-209.
- Don, P., A. Iuga, et al. (2006). Treatment of vitiligo with broadband ultraviolet B and vitamins. *Int J Dermatol* 45(1): 63-65.
- El-Mofty, M., W. Z. Mostafa, et al. (2010). A large scale analytical study on efficacy of different photo(chemo)therapeutic modalities in the treatment of psoriasis, vitiligo and mycosis fungoides. *Dermatol Ther* 23(4): 428-434.
- Elgoweini, M. and N. Nour El Din (2009). Response of vitiligo to narrowband ultraviolet B and oral antioxidants. *J Clin Pharmacol* 49(7): 852-855.
- Esposito, M., R. Soda, et al. (2004). Treatment of vitiligo with the 308 nm excimer laser. *Clin Exp Dermatol* 29(2): 133-137.


- Gattu, S., M. L. Pang, et al. (2010). Pilot evaluation of supra-erythemogenic phototherapy with excimer laser in the treatment of patients with moderate to severe plaque psoriasis. *J Dermatolog Treat* 21(1): 54-60.
- Gawkrodger, D. J., A. D. Ormerod, et al. (2008). Guideline for the diagnosis and management of vitiligo. *Br J Dermatol* 159(5): 1051-1076.
- Goldinger, S. M., R. Dummer, et al. (2007). Combination of 308-nm xenon chloride excimer laser and topical calcipotriol in vitiligo. *J Eur Acad Dermatol Venereol* 21(4): 504-508.
- Gonzaga, E. R. (2009). Role of UV light in photodamage, skin aging, and skin cancer: importance of photoprotection. *Am J Clin Dermatol* 10 Suppl 1: 19-24.
- Grimes, P. E., T. Soriano, et al. (2002). Topical tacrolimus for repigmentation of vitiligo. *J Am Acad Dermatol* 47(5): 789-791.
- Hadi, S., P. Tinio, et al. (2006). Treatment of vitiligo using the 308-nm excimer laser. *Photomed Laser Surg* 24(3): 354-357.
- Hadi, S. M., J. M. Spencer, et al. (2004). The use of the 308-nm excimer laser for the treatment of vitiligo. *Dermatol Surg* 30(7): 983-986.
- Hamzavi, I., H. Jain, et al. (2004). Parametric modeling of narrowband UV-B phototherapy for vitiligo using a novel quantitative tool: the Vitiligo Area Scoring Index. *Arch Dermatol* 140(6): 677-683.
- Hartmann, A., C. Lurz, et al. (2005). Narrow-band UVB311 nm vs. broad-band UVB therapy in combination with topical calcipotriol vs. placebo in vitiligo. *Int J Dermatol* 44(9): 736-742.
- Hearn, R. M., A. C. Kerr, et al. (2008). Incidence of skin cancers in 3867 patients treated with narrow-band ultraviolet B phototherapy. *Br J Dermatol* 159(4): 931-935.
- Hexsel, C. L., M. J. Eide, et al. (2009). Incidence of nonmelanoma skin cancer in a cohort of patients with vitiligo. *J Am Acad Dermatol* 60(6): 929-933.
- Hofer, A., A. S. Hassan, et al. (2005). Optimal weekly frequency of 308-nm excimer laser treatment in vitiligo patients. *Br J Dermatol* 152(5): 981-985.
- Hofer, A., A. S. Hassan, et al. (2006). The efficacy of excimer laser (308 nm) for vitiligo at different body sites. *J Eur Acad Dermatol Venereol* 20(5): 558-564.
- Hong, S. B., H. H. Park, et al. (2005). Short-term effects of 308-nm xenon-chloride excimer laser and narrow-band ultraviolet B in the treatment of vitiligo: a comparative study. *J Korean Med Sci* 20(2): 273-278.
- Housman, T. S., D. J. Pearce, et al. (2004). A maintenance protocol for psoriasis plaques cleared by the 308 nm excimer laser. *J Dermatolog Treat* 15(2): 94-97.
- Hui-Lan, Y., H. Xiao-Yan, et al. (2009). Combination of 308-nm excimer laser with topical pimecrolimus for the treatment of childhood vitiligo. *Pediatr Dermatol* 26(3): 354-356.
- Jo, S. J., H. H. Kwon, et al. (2010). No Evidence for Increased Skin Cancer Risk in Koreans with Skin Phototypes III-V Treated with Narrowband UVB Phototherapy. *Acta Derm Venereol*.
- Kanwar, A. J., S. Dogra, et al. (2005). Narrow-band UVB for the treatment of vitiligo: an emerging effective and well-tolerated therapy. *Int J Dermatol* 44(1): 57-60.

- Kawalek, A. Z., J. M. Spencer, et al. (2004). Combined excimer laser and topical tacrolimus for the treatment of vitiligo: a pilot study. *Dermatol Surg* 30(2 Pt 1): 130-135.
- Kemeny, L., Z. Csoma, et al. (2010). Targeted phototherapy of plaque-type psoriasis using ultraviolet B-light-emitting diodes. *Br J Dermatol* 163(1): 167-173.
- Koster W, W. A. (1990). Phototherapy with UVB in vitiligo. *J Hautkr* 65: 1022-1024.
- Kullavanijaya, P. and H. W. Lim (2004). Topical calcipotriene and narrowband ultraviolet B in the treatment of vitiligo. *Photodermatol Photoimmunol Photomed* 20(5): 248-251.
- Lahiri, K., S. Malakar, et al. (2006). Repigmentation of vitiligo with punch grafting and narrow-band UV-B (311 nm)--a prospective study. *Int J Dermatol* 45(6): 649-655.
- Lan, C. C., G. S. Chen, et al. (2005). FK506 promotes melanocyte and melanoblast growth and creates a favourable milieu for cell migration via keratinocytes: possible mechanisms of how tacrolimus ointment induces repigmentation in patients with vitiligo. *Br J Dermatol* 153(3): 498-505.
- Lapidoth, M., M. Adatto, et al. (2007). Targeted UVB phototherapy for psoriasis: a preliminary study. *Clin Exp Dermatol* 32(6): 642-645.
- Larko, O. and G. Swanbeck (1982). Is UVB treatment of psoriasis safe? A study of extensively UVB-treated psoriasis patients compared with a matched control group. *Acta Derm Venereol* 62(6): 507-512.
- Le Duff, F., E. Fontas, et al. (2010). 308-nm excimer lamp vs. 308-nm excimer laser for treating vitiligo: a randomized study. *Br J Dermatol* 163(1): 188-192.
- Leone, G., P. Iacovelli, et al. (2003). Monochromatic excimer light 308 nm in the treatment of vitiligo: a pilot study. *J Eur Acad Dermatol Venereol* 17(5): 531-537.
- Lim, J. L. and R. S. Stern (2005). High levels of ultraviolet B exposure increase the risk of non-melanoma skin cancer in psoralen and ultraviolet A-treated patients. *J Invest Dermatol* 124(3): 505-513.
- Lotti, T., G. Buggiani, et al. (2008). Targeted and combination treatments for vitiligo. Comparative evaluation of different current modalities in 458 subjects. *Dermatol Ther* 21 Suppl 1: S20-26.
- Lotti, T., L. Tripo, et al. (2009). Focused UV-B narrowband microphototherapy (Biopsorin). A new treatment for plaque psoriasis. *Dermatol Ther* 22(4): 383-385.
- Lotti, T. M., G. Menchini, et al. (1999). UV-B radiation microphototherapy. An elective treatment for segmental vitiligo. *J Eur Acad Dermatol Venereol* 13(2): 102-108.
- Lu-yan, T., F. Wen-wen, et al. (2006). Topical tacalcitol and 308-nm monochromatic excimer light: a synergistic combination for the treatment of vitiligo. *Photodermatol Photoimmunol Photomed* 22(6): 310-314.
- Man, I., I. K. Crombie, et al. (2005). The photocarcinogenic risk of narrowband UVB (TL-01) phototherapy: early follow-up data. *Br J Dermatol* 152(4): 755-757.
- Murase, J. E., E. E. Lee, et al. (2005). Effect of ethnicity on the risk of developing nonmelanoma skin cancer following long-term PUVA therapy. *Int J Dermatol* 44(12): 1016-1021.
- Natta, R., T. Somsak, et al. (2003). Narrowband ultraviolet B radiation therapy for recalcitrant vitiligo in Asians. *J Am Acad Dermatol* 49(3): 473-476.

- Nicolaidou, E., C. Antoniou, et al. (2007). Efficacy, predictors of response, and long-term follow-up in patients with vitiligo treated with narrowband UVB phototherapy. *J Am Acad Dermatol* 56(2): 274-278.
- Nistico, S. P., R. Saraceno, et al. (2006). A 308-nm monochromatic excimer light in the treatment of palmoplantar psoriasis. *J Eur Acad Dermatol Venereol* 20(5): 523-526.
- Njoo, M. D., J. D. Bos, et al. (2000). Treatment of generalized vitiligo in children with narrow-band (TL-01) UVB radiation therapy. *J Am Acad Dermatol* 42(2 Pt 1): 245-253.
- Njoo, M. D. and W. Westerhof (2000). Guidelines for treatment of vitiligo: is an update pending If recommendations for children are not followed? *Arch Dermatol* 136(9): 1173-1174.
- Noborio, R., K. Kobayashi, et al. (2006). Comparison of the efficacy of calcipotriol and maxacalcitol in combination with narrow-band ultraviolet B therapy for the treatment of psoriasis vulgaris. *Photodermatol Photoimmunol Photomed* 22(5): 262-264.
- Nordal, E., G. Guleng, et al. (2011). Treatment of vitiligo with narrowband-UVB (TL01) combined with tacrolimus ointment (0.1%) vs. placebo ointment, a randomized right/left double-blind comparative study. *J Eur Acad Dermatol Venereol*.
- Norris, D. A., T. Horikawa, et al. (1994). Melanocyte destruction and repopulation in vitiligo. *Pigment Cell Res* 7(4): 193-203.
- Novak, Z., A. Berces, et al. (2004). Efficacy of different UV-emitting light sources in the induction of T-cell apoptosis. *Photochem Photobiol* 79(5): 434-439.
- Novak, Z., B. Bonis, et al. (2002). Xenon chloride ultraviolet B laser is more effective in treating psoriasis and in inducing T cell apoptosis than narrow-band ultraviolet B. *J Photochem Photobiol B* 67(1): 32-38.
- Ostovari, N., T. Passeron, et al. (2004). Treatment of vitiligo by 308-nm excimer laser: an evaluation of variables affecting treatment response. *Lasers Surg Med* 35(2): 152-156.
- Ozawa, M., K. Ferenczi, et al. (1999). 312-nanometer ultraviolet B light (narrow-band UVB) induces apoptosis of T cells within psoriatic lesions. *J Exp Med* 189(4): 711-718.
- Passeron, T., N. Ostovari, et al. (2004). Topical tacrolimus and the 308-nm excimer laser: a synergistic combination for the treatment of vitiligo. *Arch Dermatol* 140(9): 1065-1069.
- Percivalle, S., R. Piccino, et al. (2008). Narrowband UVB phototherapy in vitiligo: evaluation of results in 53 patients. *G Ital Dermatol Venereol* 143(1): 9-14.
- Pittelkow, M. R., H. O. Perry, et al. (1981). Skin cancer in patients with psoriasis treated with coal tar. A 25-year follow-up study. *Arch Dermatol* 117(8): 465-468.
- Rath, N., H. K. Kar, et al. (2008). An open labeled, comparative clinical study on efficacy and tolerability of oral minipulse of steroid (OMP) alone, OMP with PUVA and broad / narrow band UVB phototherapy in progressive vitiligo. *Indian J Dermatol Venereol Leprol* 74(4): 357-360.
- Roelandts, R. (2002). The history of phototherapy: something new under the sun? *J Am Acad Dermatol* 46(6): 926-930.

- Samson Yashar, S., R. Gielczyk, et al. (2003). Narrow-band ultraviolet B treatment for vitiligo, pruritus, and inflammatory dermatoses. *Photodermatol Photoimmunol Photomed* 19(4): 164-168.
- Saraceno, R., S. P. Nistico, et al. (2009). Monochromatic excimer light 308 nm in monotherapy and combined with topical khellin 4% in the treatment of vitiligo: a controlled study. *Dermatol Ther* 22(4): 391-394.
- Sassi, F., S. Cazzaniga, et al. (2008). Randomized controlled trial comparing the effectiveness of 308-nm excimer laser alone or in combination with topical hydrocortisone 17-butyrate cream in the treatment of vitiligo of the face and neck. *Br J Dermatol* 159(5): 1186-1191.
- Schallreuter, K. U. and H. Rokos (2007). From the bench to the bedside: proton pump inhibitors can worsen vitiligo. *Br J Dermatol* 156(6): 1371-1373.
- Schulpis, C. H., C. Antoniou, et al. (1989). Phenylalanine plus ultraviolet light: preliminary report of a promising treatment for childhood vitiligo. *Pediatr Dermatol* 6(4): 332-335.
- Shen, Z., T. W. Gao, et al. (2007). Optimal frequency of treatment with the 308-nm excimer laser for vitiligo on the face and neck. *Photomed Laser Surg* 25(5): 418-427.
- Silverberg, N. B. (2010). Update on childhood vitiligo. *Curr Opin Pediatr* 22(4): 445-452.
- Sitek, J. C., M. Loeb, et al. (2007). Narrowband UVB therapy for vitiligo: does the repigmentation last? *J Eur Acad Dermatol Venereol* 21(7): 891-896.
- Spencer, J. M., R. Nossa, et al. (2002). Treatment of vitiligo with the 308-nm excimer laser: a pilot study. *J Am Acad Dermatol* 46(5): 727-731.
- Stern, R. S. and N. Laird (1994). The carcinogenic risk of treatments for severe psoriasis. Photochemotherapy Follow-up Study. *Cancer* 73(11): 2759-2764.
- Stinco, G., F. Piccirillo, et al. (2009). An open randomized study to compare narrow band UVB, topical pimecrolimus and topical tacrolimus in the treatment of vitiligo. *Eur J Dermatol* 19(6): 588-593.
- Taneja, A., M. Trehan, et al. (2003). 308-nm excimer laser for the treatment of localized vitiligo. *Int J Dermatol* 42(8): 658-662.
- Weichenthal, M. and T. Schwarz (2005). Phototherapy: how does UV work? *Photodermatol Photoimmunol Photomed* 21(5): 260-266.
- Weischer, M., A. Blum, et al. (2004). No evidence for increased skin cancer risk in psoriasis patients treated with broadband or narrowband UVB phototherapy: a first retrospective study. *Acta Derm Venereol* 84(5): 370-374.
- Westerhof, W. and L. Nieuweboer-Krobotova (1997). Treatment of vitiligo with UV-B radiation vs topical psoralen plus UV-A. *Arch Dermatol* 133(12): 1525-1528.
- Wind, B. S., M. W. Kroon, et al. (2010). Home vs. outpatient narrowband ultraviolet B therapy for the treatment of nonsegmental vitiligo: a retrospective questionnaire study. *Br J Dermatol* 162(5): 1142-1144.
- Wiskemann, A. (1978). [UVB-phototherapy of psoriasis using a standing box developed for PUVA-therapy]. *Z Hautkr* 53(18): 633-636.
- Xiang, L. (2008). Once-weekly treatment of vitiligo with monochromatic excimer light 308 nm in Chinese patients. *J Eur Acad Dermatol Venereol* 22(7): 899-900.

- Yang, Y. S., H. R. Cho, et al. (2010). Clinical study of repigmentation patterns with either narrow-band ultraviolet B (NBUVB) or 308 nm excimer laser treatment in Korean vitiligo patients. *Int J Dermatol* 49(3): 317-323.
- Yones, S. S., R. A. Palmer, et al. (2007). Randomized double-blind trial of treatment of vitiligo: efficacy of psoralen-UV-A therapy vs Narrowband-UV-B therapy. *Arch Dermatol* 143(5): 578-584.
- Zhang, X. Y., Y. L. He, et al. (2010). Clinical efficacy of a 308 nm excimer laser in the treatment of vitiligo. *Photodermatol Photoimmunol Photomed* 26(3): 138-142.



Vitiligo - Management and Therapy

Edited by Dr. Kelly KyungHwa Park

ISBN 978-953-307-731-4

Hard cover, 174 pages

Publisher InTech

Published online 14, December, 2011

Published in print edition December, 2011

Vitiligo: Management and Therapy is a practical guide to vitiligo that reflects current research related to the fundamentals of vitiligo and its management. Vitiligo experts and researchers from all over the world have contributed to this text, accounting for its comprehensive nature and diverse array of topics. The recent advances in medicine and technology have led to a better understanding of the disease and have broadened available treatment options. The essentials are captured in this book and are complemented by useful clinical photographs and reference tables. This concise tool will serve as an invaluable resource for clinicians in daily practice.

How to reference

In order to correctly reference this scholarly work, feel free to copy and paste the following:

Kelly KyungHwa Park and Jenny Eileen Murase (2011). Ultraviolet B (UVB) Phototherapy in the Treatment of Vitiligo, Vitiligo - Management and Therapy, Dr. Kelly KyungHwa Park (Ed.), ISBN: 978-953-307-731-4, InTech, Available from: <http://www.intechopen.com/books/vitiligo-management-and-therapy/ultraviolet-b-uvb-phototherapy-in-the-treatment-of-vitiligo>

INTECH

open science | open minds

InTech Europe

University Campus STeP Ri
Slavka Krautzeka 83/A
51000 Rijeka, Croatia
Phone: +385 (51) 770 447
Fax: +385 (51) 686 166
www.intechopen.com

InTech China

Unit 405, Office Block, Hotel Equatorial Shanghai
No.65, Yan An Road (West), Shanghai, 200040, China
中国上海市延安西路65号上海国际贵都大饭店办公楼405单元
Phone: +86-21-62489820
Fax: +86-21-62489821

© 2011 The Author(s). Licensee IntechOpen. This is an open access article distributed under the terms of the [Creative Commons Attribution 3.0 License](#), which permits unrestricted use, distribution, and reproduction in any medium, provided the original work is properly cited.