

# We are IntechOpen, the world's leading publisher of Open Access books Built by scientists, for scientists

4,500

Open access books available

118,000

International authors and editors

130M

Downloads

Our authors are among the

154

Countries delivered to

TOP 1%

most cited scientists

12.2%

Contributors from top 500 universities



WEB OF SCIENCE™

Selection of our books indexed in the Book Citation Index  
in Web of Science™ Core Collection (BKCI)

Interested in publishing with us?  
Contact [book.department@intechopen.com](mailto:book.department@intechopen.com)

Numbers displayed above are based on latest data collected.  
For more information visit [www.intechopen.com](http://www.intechopen.com)



# Congenital Anomalies of Thoracic Systemic and Pulmonary Veins Visualized with Computed Tomography

Elżbieta Czekajska-Chehab, Sebastian Uhlig,  
Grzegorz Staśkiewicz and Andrzej Drop  
*1st Department of Radiology, Medical University of Lublin  
Poland*

## 1. Introduction

Introduction of multidetector computed tomography (MDCT) into daily clinical use has been a breakthrough in the thoracic imaging. It allowed one breathhold scanning of the entire chest, and thin sections made multiplanar and volumetric reconstructions easily available. Initially, the main interest focused on the abdominal aorta and its branches, however, it turned out, that MDCT allows for an excellent visualization and assessment of thoracic veins, including their anatomical variants and thrombosis. Thin collimation combined with secondary reconstructions allows preliminary diagnosis of vascular anomalies even in precontrast scanning. Secondary reconstructions in oblique or curved planes, three-dimensional reconstructions and ECG-gating allow clear identification of venous pathologies.

## 2. Embryology of thoracic veins

Formation of blood vessels occurs around the day 17 of the fetal development, and occurs within the splanchnopleuric mesoderm of the yolk sac. At about day 21, blood islands within the yolk sac may be observed. Central parts of the islands host hemoblasts, while the outer layers form the blood vessels. Developing veins form three main systems, which carry blood into the sinus venosus (Dudek & Fix, 2004):

- vitelline veins, which form part of part of inferior vena cava (IVC), hepatic veins and sinusoids, ductus venosus, portal vein and its tributaries (superior and inferior mesenteric veins – SMV and IMV, splenic vein); this venous system collects the blood from the fetal GI tract;
- umbilical veins, which carry blood from placenta - both contribute to the hepatic sinusoids, left one forms ligamentum teres
- cardinal veins, which collect the blood from the body:
  - anterior, which form superior vena cava (SVC), internal jugular veins (IJV);
  - posterior, which form part of IVC, common iliac veins;
  - subcardinal, which form part of IVC, renal and gonadal veins;
  - supracardinal, which form part of IVC, intercostal veins, azygos and hemiazygos veins.

The systemic veins are derived from cardinal veins (CVs), which apart from umbilical and vitelline vessels are one of three main elements of foetal venous system. CVs in the form of paired structures located symmetrically on both sides of embryo's body appear in 4th week of gestation. System of CVs is comprised of anterior cardinal veins (ACVs) draining cranial parts of the body and posterior cardinal veins (PCVs) providing drainage from caudal parts. ACV and PCV join together into common cardinal vein - CCV (Cuvier ducts), entering the sinus venosus of early heart eventually.

At 8th week of fetal life left brachiocephalic vein is being formed connecting the left and right ACVs. As a consequence the portion of left ACV below this connection partially obliterates forming the „ligament of Marshall” and the remaining, distal section of left ACV forms coronary sinus and oblique vein of the heart. Right ACV remains patent and together with right CCV becomes the precursor of superior vena cava system (Fasouliotis et al., 2002; Ratliff et al., 2006).

Most of PCVs undergo atrophy and their patent remnants form renal segment of inferior vena cava (IVC) and common iliac veins. Simultaneously, subcardinal and supracardinal veins are being formed. Both subcardinal and supracardinal veins (SVs) are involved in development of IVC, also SVs give the origin to the azygos system of veins. Usually SVs develop anastomosis at the level of thoracic spine. Right SV becomes azygos vein (AV), however according to data in literature its arch may be delivered from the upper segment of the right PCV (Demos et al., 2004). The left one below anastomosis transforms into hemiazygos vein (HV) and above the anastomosis obliterates. In some cases only the cranial section of left SV remains patent as accessory HV (Fasouliotis et al., 2002; Arslan et al., 2000).

### **3. Multidetector computed tomography of thoracic vascular system- optimization of scanning protocol, imaging pitfalls, collateral circulation**

#### **3.1 Optimization of the scanning protocol and imaging pitfalls**

Optimal MDCT imaging of thoracic veins may be difficult, as there is no possibility of concomitant optimal enhancement of systemic, pulmonary and cardiac veins, because of different contrast inflow rate into particular vessels, asymmetrical enhancement of right and left sides of the thorax, dependent on the side of intravenous contrast administration, as well as artifacts and collateral circulation.

MDCT assessment of thoracic venous anomalies usually occurs in two situations: a more typical one involves incidental diagnosis of venous pathology in patients diagnosed for unrelated conditions, e.g. suspected neoplasm or coronary disease. In such cases, the examination is reviewed by radiologist after the scanning is over, and modification of the protocol is not possible. In cases of the precontrast scanning, preliminary assessment is possible, and appropriate modifications can be applied, including early postcontrast scanning (23-30s) for pulmonary veins evaluations, and late phase (60-120s) for systemic veins. Furthermore, ECG-gating utilization can be considered.

Less frequent setting is an examination performed for assessment of particular venous anomaly, e.g. before ablation or resynchronization therapy, as well as confirmation of

anomalies suggested by echocardiography or chest x-ray. Such setting allows for optimal modification of the scanning protocol, like reduction of field of view (FOV), ECG-gating or bolus tracking for optimized visualization of pulmonary veins, cardiac veins or coronary sinus.

Technical features of MDCT allow for correct diagnosis of any thoracic venous pathology. Potential pitfalls are caused by limited knowledge of venous physiology and vascular anomalies and variants, focusing on arteries and pulmonary parenchyma, as well as lack of preliminary assessment of the precontrast scans. In our opinion, the most significant cause is insufficient awareness and interest in this type of pathology.

### 3.2 Thoracic collateral venous circulation pathways

Collateral circulation is particularly important in patients with obstruction of SVC, which may be caused by benign, malignant or iatrogenic conditions.

Four main groups of collateral thoracic veins include: azygos system of veins - communication between SVC and ascending lumbar vein; subfascial system of epigastric veins - collateral circulation between brachiocephalic vein and external femoral vein; subcutaneous system of superficial epigastric vein and vertebral veins. Less frequently, systemic-pulmonary or intramuscular pathways are involved.

**Azygos system of veins** provides communication between SVC and ascending lumbar veins, which receive lumbar veins, forming anastomosis with IVC. Azygos system consists of veins of posterior wall of the trunk, which receive multiple tributaries, particularly within their course through the mediastinum (Figure 1, Figure 2). Azygos system forms the best developed anastomosis between vena cava systems, with its tributaries arising from both parietal, as well as visceral (in particular mediastinal and bronchial) veins.

**Subcutaneous veins** of the trunk connect axillary and femoral veins (Figure 3). Superficial system anastomoses with the subfascial system by means of perforating veins, which carry blood from medial aspect of breasts and sternal branches of internal thoracic veins.

**Subfascial** veins connect external iliac vein and subclavian vein via internal thoracic and inferior epigastric veins. Internal thoracic veins (ITV) are tributaries of brachiocephalic veins. They are formed by junction of musculophrenic veins and superior epigastric veins. Internal thoracic veins anastomose at the posterior surface of sternum. Parietal tributaries of ITV are anterior intercostal veins, which provide anastomosis with the azygos system, by means of posterior intercostals. Additional tributaries of brachiocephalic veins, frequently widened in patients with SVC syndrome, are pericardiophrenic veins.

**Vertebral plexuses** form two vascular rings located outside the vertebrae: anterior and posterior external vertebral plexus, as well as inner, internal vertebral plexuses located within the vertebral canal. In the cervical region, anterior external plexus anastomoses with vertebral veins, in thoracic region with posterior intercostal veins, in lumbar - lumbar veins. At the anterior aspect of sacral bone it anastomoses with median and lateral sacral veins. Posterior external plexus is best developed in the cervical region, anastomosing with occipital, vertebral and deep cervical veins.

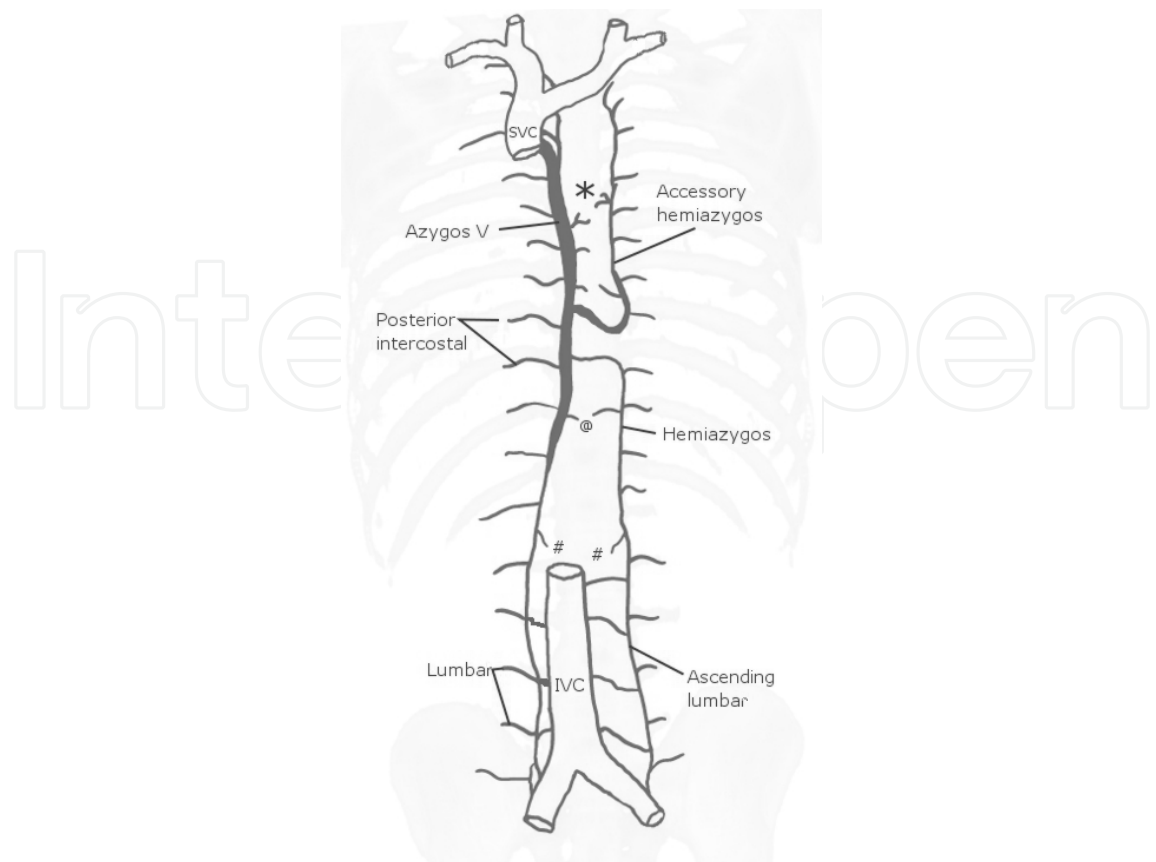


Fig. 1. Azygos system of veins. Multiple anastomoses of this system include parietal veins (lumbar, ascending lumbar, intercostal, @-superior phrenic) as well as visceral (#-renal, \*-mediastinal, including: bronchial, esophageal, pericardiac) veins.

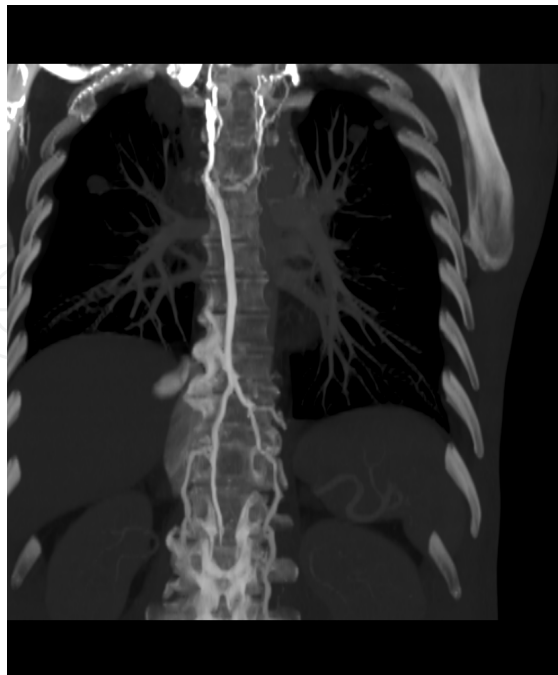


Fig. 2. Curved multiplanar reformation. Widening of azygos system of veins in a patient with left-sided SVC syndrome.

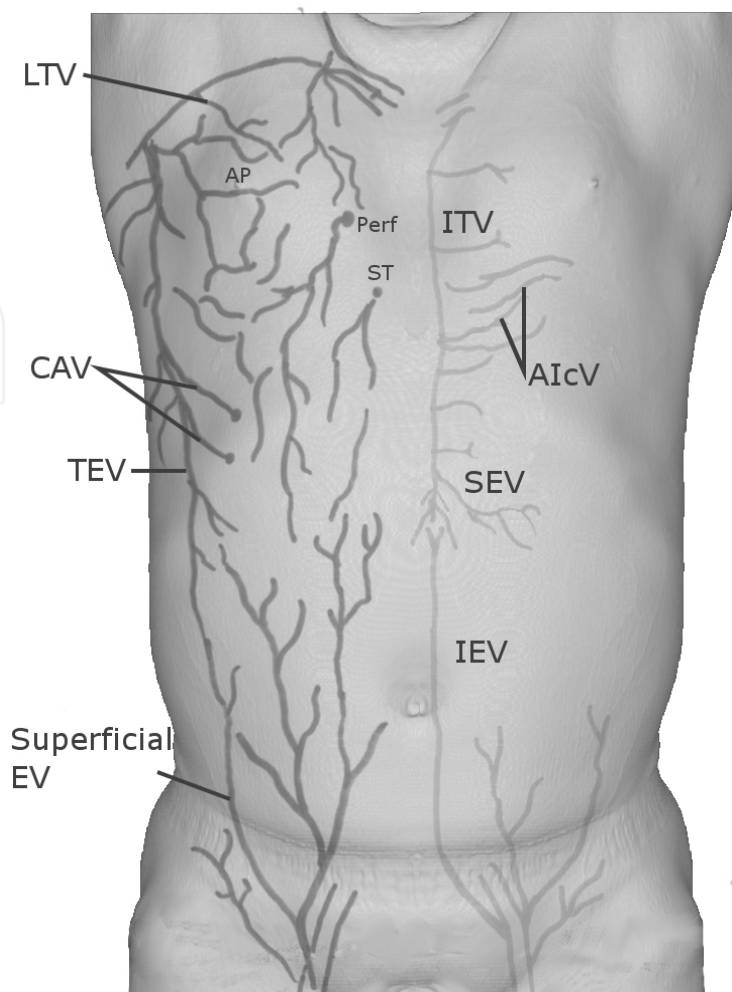


Fig. 3. Superficial and subfascial systems of veins. Superficial veins: Superficial EV – superficial epigastric vein, TEV – thoracoepigastric veins, CAV – costoaxillary veins, LTV – lateral thoracic vein, AP – areolar plexus. ST – sternal branches of internal thoracic vein, Perf – perforating branches.

## 4. Thoracic veins anomalies

### 4.1 Anomalies of the superior vena cava (SVC)

#### 4.1.1 Persistent left superior vena cava

Persistent left superior vena cava (PLSVC) results from disturbances in process of obliteration of left ACV what leads to its patency. The defect occurs in 0,3 – 0,5% of the general population, usually in bilateral configuration with the right sided superior vena cava (Biffi et al., 2001; Tak et al., 2002) – Figure 4, Figure 5. Its prevalence is significantly higher when it is combined with other congenital heart defects, heterotaxy syndromes or some genetical disorders (Anagnostopoulos et al., 2009; Ho et al., 2004).

Solitary PLSVC is less common finding with an incidence reaching 33% among the individuals with this anomaly (Fang et al., 2007), Figure 6. PLSVC both in unilateral or bilateral configuration reaches the right atrium through the coronary sinus typically, Figure 7. Very seldom it is connected with the left atrium (Ardilouze et al., 2009).



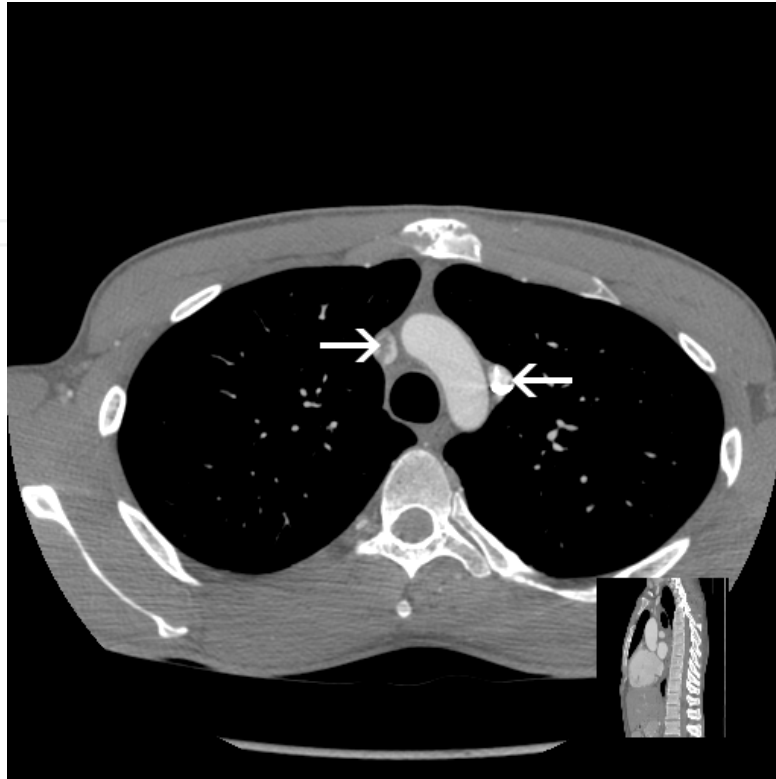

Fig. 4. Axial CT image presents bilateral superior venae cavae (arrows).

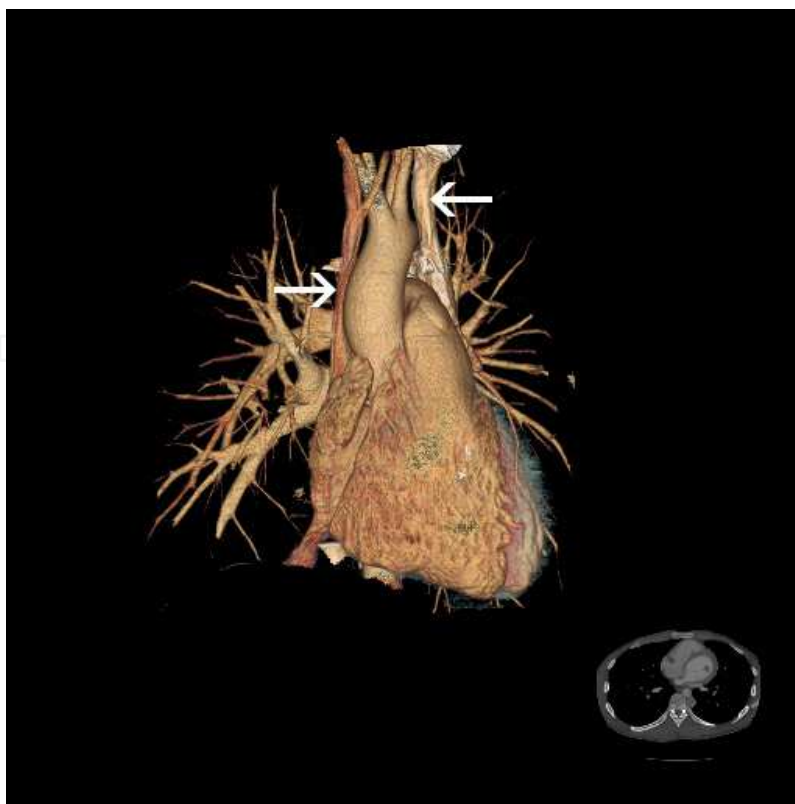

Fig. 5. Volumetric reconstruction presents bilateral superior venae cavae (arrows).

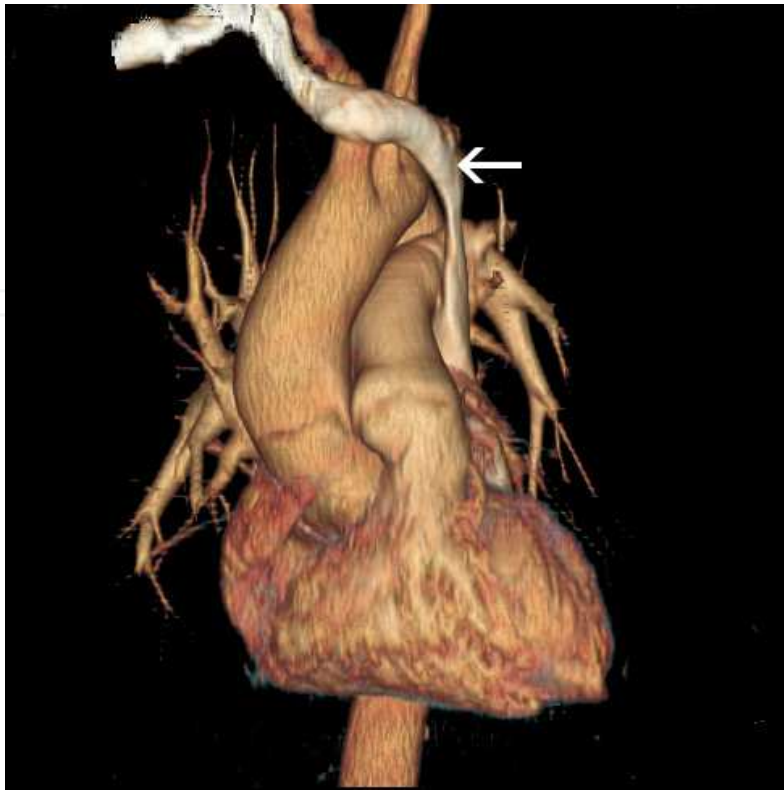


Fig. 6. Volumetric reconstruction presents single left-sided SCV (arrow).

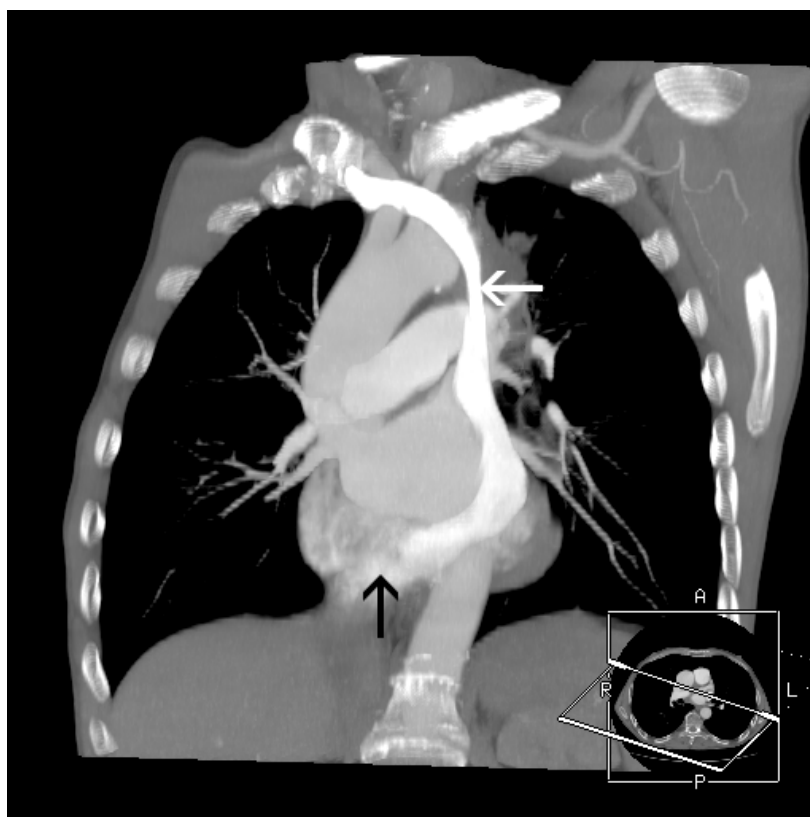

Fig. 7. Maximum intensity projection shows single left-sided SVC (white arrow), with a typical opening into widened coronary sinus (black arrow).



In the majority of cases, when PLSVC is not associated with other congenital heart defects, it remains hemodynamically asymptomatic. However, the anomaly may predispose to cardiac arrhythmias and simultaneously, the most important clinical implications of PLSVC are difficulties in placing pacemaker or in ablation procedure (Biffi et al., 2001; Horlitz et al., 2006; Morgan et al., 2002). Usually during this procedure the PLSVC is revealed most frequently as an incidental finding (Figure 8, Figure 9).

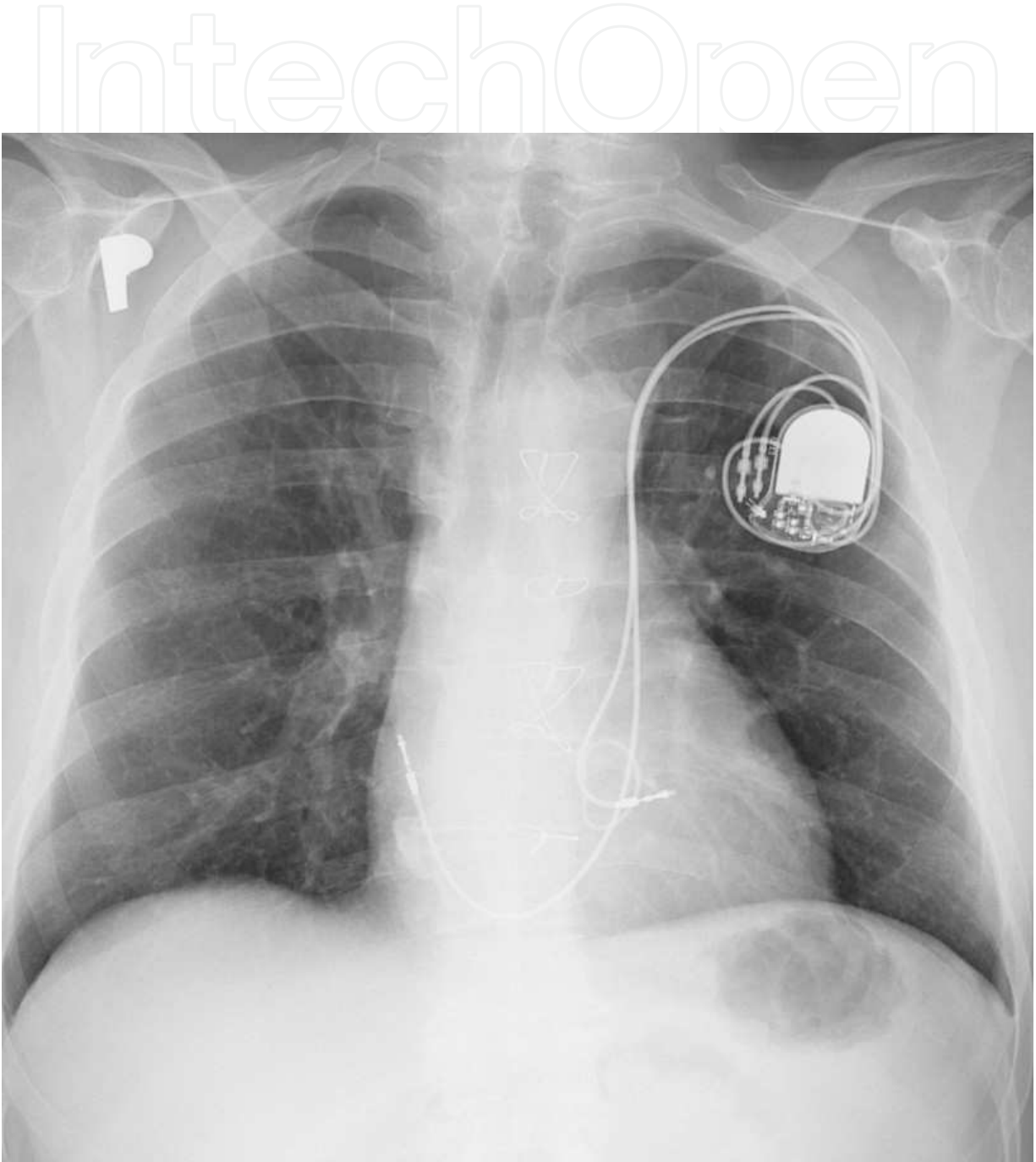


Fig. 8. Anteroposterior chest radiograph. Pacemaker electrodes passing through left-sided SVC, entering distal coronary sinus.

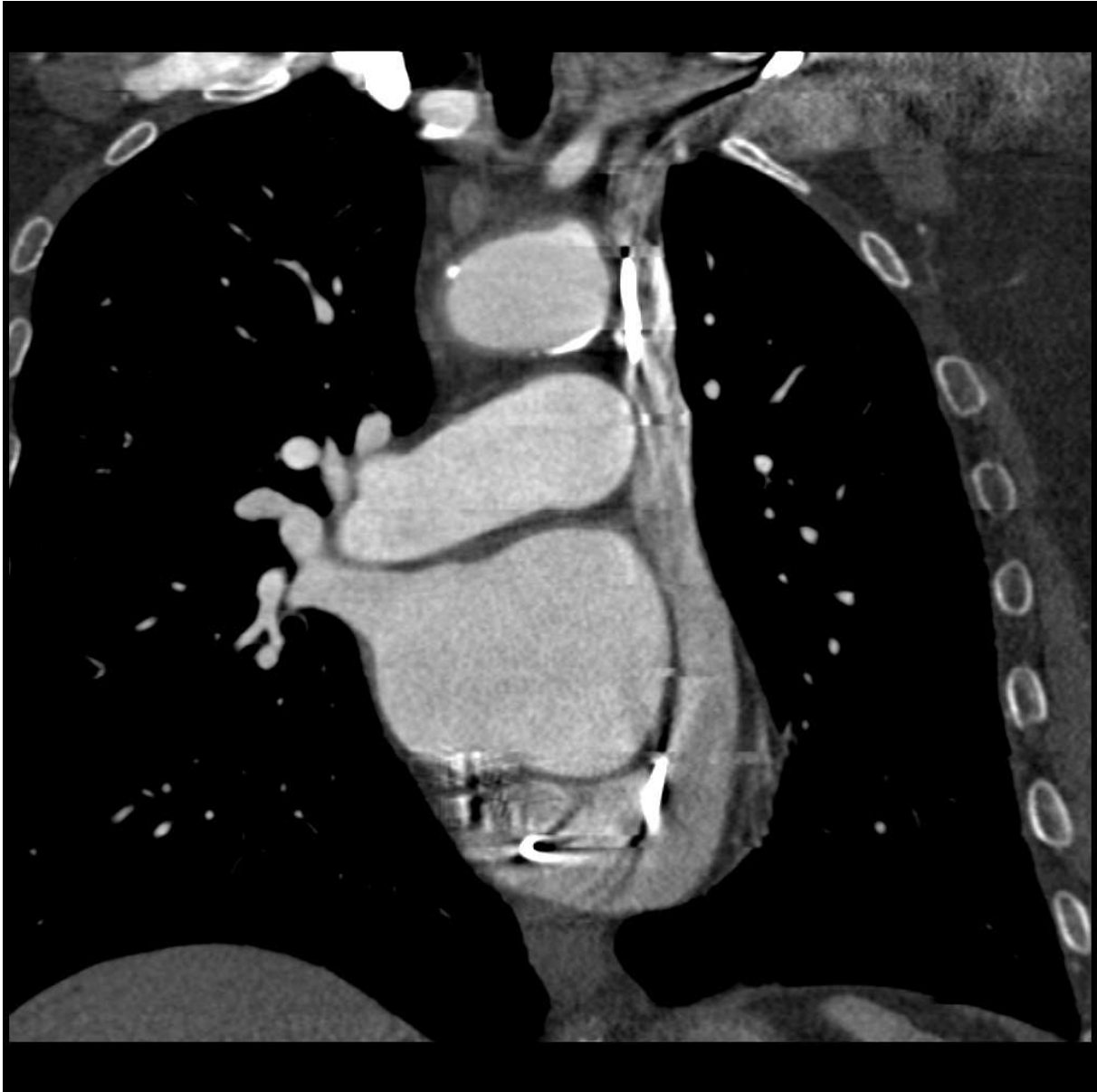


Fig. 9. Curved multiplanar reformation, CT. Pacemaker electrodes passing through single PLSVC into coronary sinus.

#### 4.1.2 Aneurysm of SVC

In contrary to PLSVC, aneurysms of thoracic veins including SVC are extremely rare with merely about 30 cases reported in the literature (Varma et al., 2003). Both congenital and acquired causes of the pathology are possible. It may be fusiform or saccular and in the latter form can reach enormous size being unusual cause of mediastinal „mass” (Figure 10). Basing on few case reports it can induce complications, such as pulmonary embolism or be the source of intrathoracic bleeding after rupture. Saccular aneurysms are usually treated surgically (Enright & Kanne, 2010).

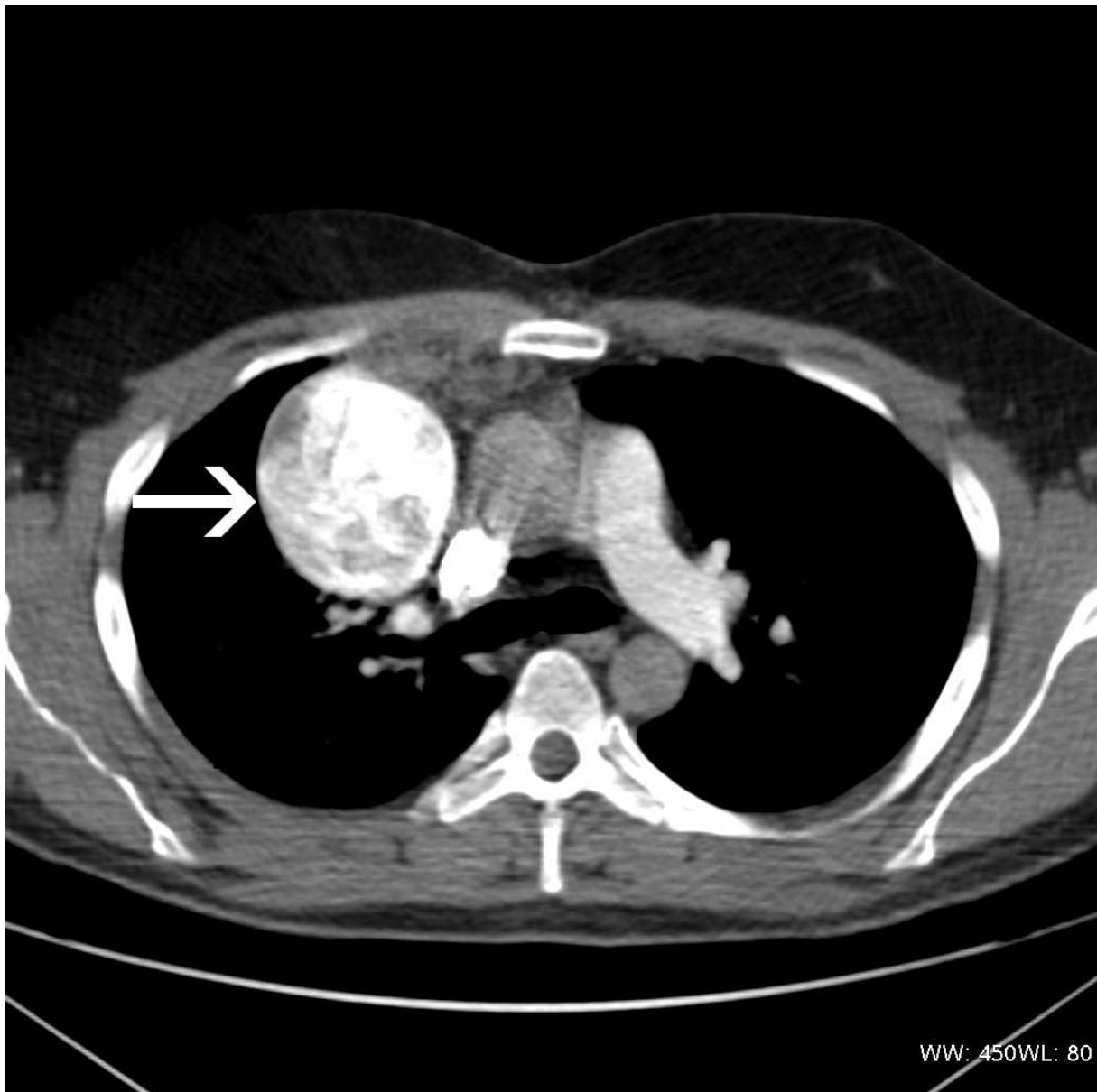


Fig. 10. Axial scan, CT. Saccular aneurysm of SVC (arrow)

#### 4.2 Anomalies of the Azygos Veins (AV)

**Azygos lobe:** The most common variant of azygos system of veins is azygos lobe. It appears in about 1% of population and its appearance is attributed to incorrect migration of proximal section of right PCV, which is considered to be precursor of azygos arch. Instead of locating over the right lung's apex it penetrates its parenchyma pulling either visceral or parietal layers of pleura. In consequence azygos fissure composed of four layers of pleura is formed. Less frequently hemiazygos lobe may develop. Since azygos and hemiazygos lobes are asymptomatic, they are usually detected incidentally on x-rays (Figure 11) or CT examinations (Caceres et al., 1998; Demos et al., 2004).

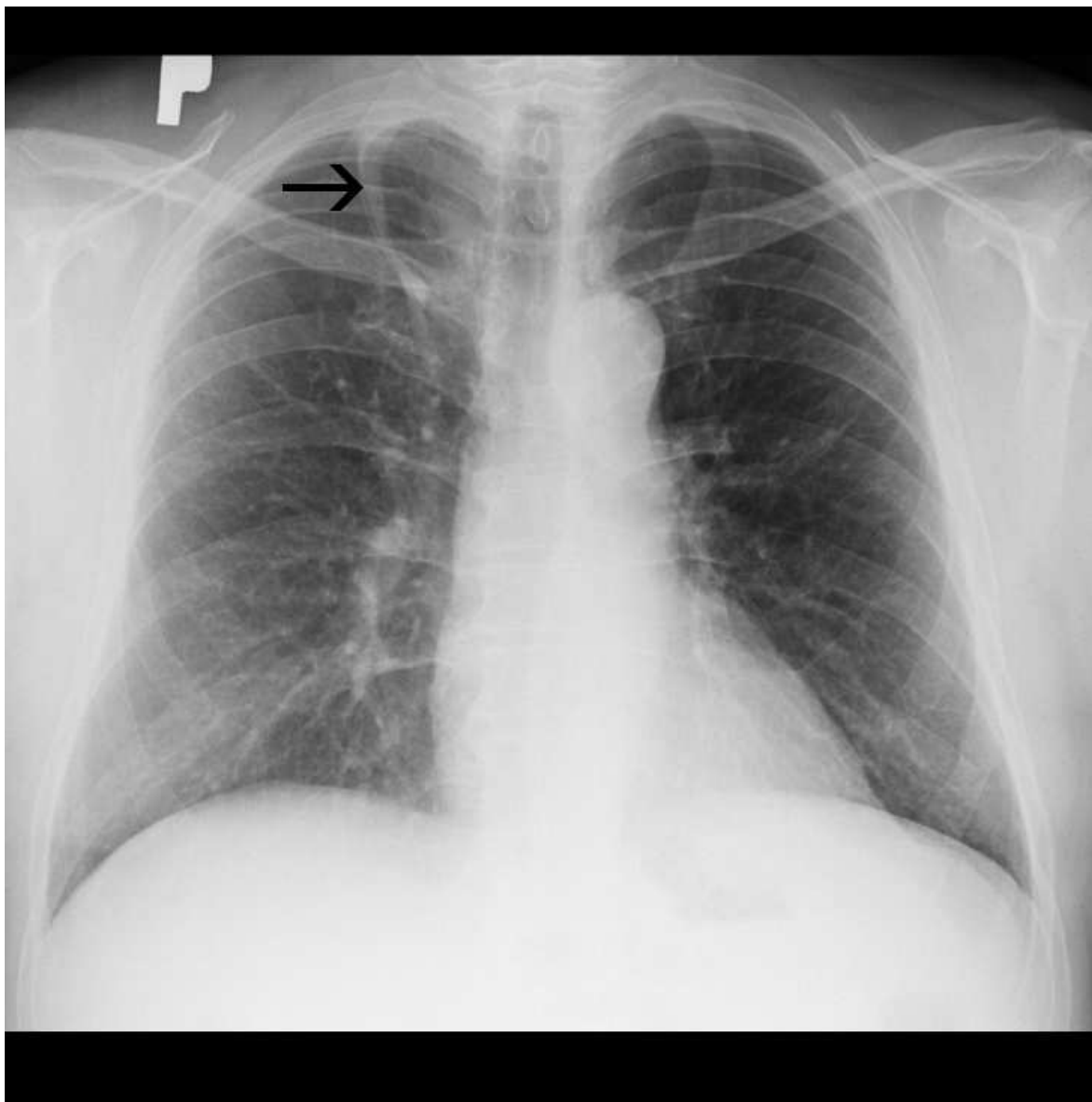


Fig. 11. Anteroposterior chest radiograph. Azygos lobe in the upper right lung field as an incidental finding, black arrow indicates accessory fissure.

**Azygos and hemiazygos continuation of IVC:** Azygos continuation of IVC results from disturbances in development of hepatic segment of IVC leading to interruption of the vessel. The drainage of caudal parts of the body is continued through the AV, with an exception of hepatic veins which empty to the right atrium directly, usually through one, common vessel. AV becomes widened and drains to SVC through prominent azygos arch.

Hemiazygos continuation is related to left sided IVC. Usually it drains directly to AV through anastomosis at the level of thoracic spine and the blood flow is continued through AV. However, other routes are possible including direct drainage to the coexistent PLSVC or through accessory HV (Demos et al., 2004)], furthermore, in absence of confluence of brachiocephalic veins, isolated drainage of left and right sides of the upper body may exist, with right brachiocephalic vein forming SVC, and left brachiocephalic vein opening into accessory hemiazygos vein (Figure 12).

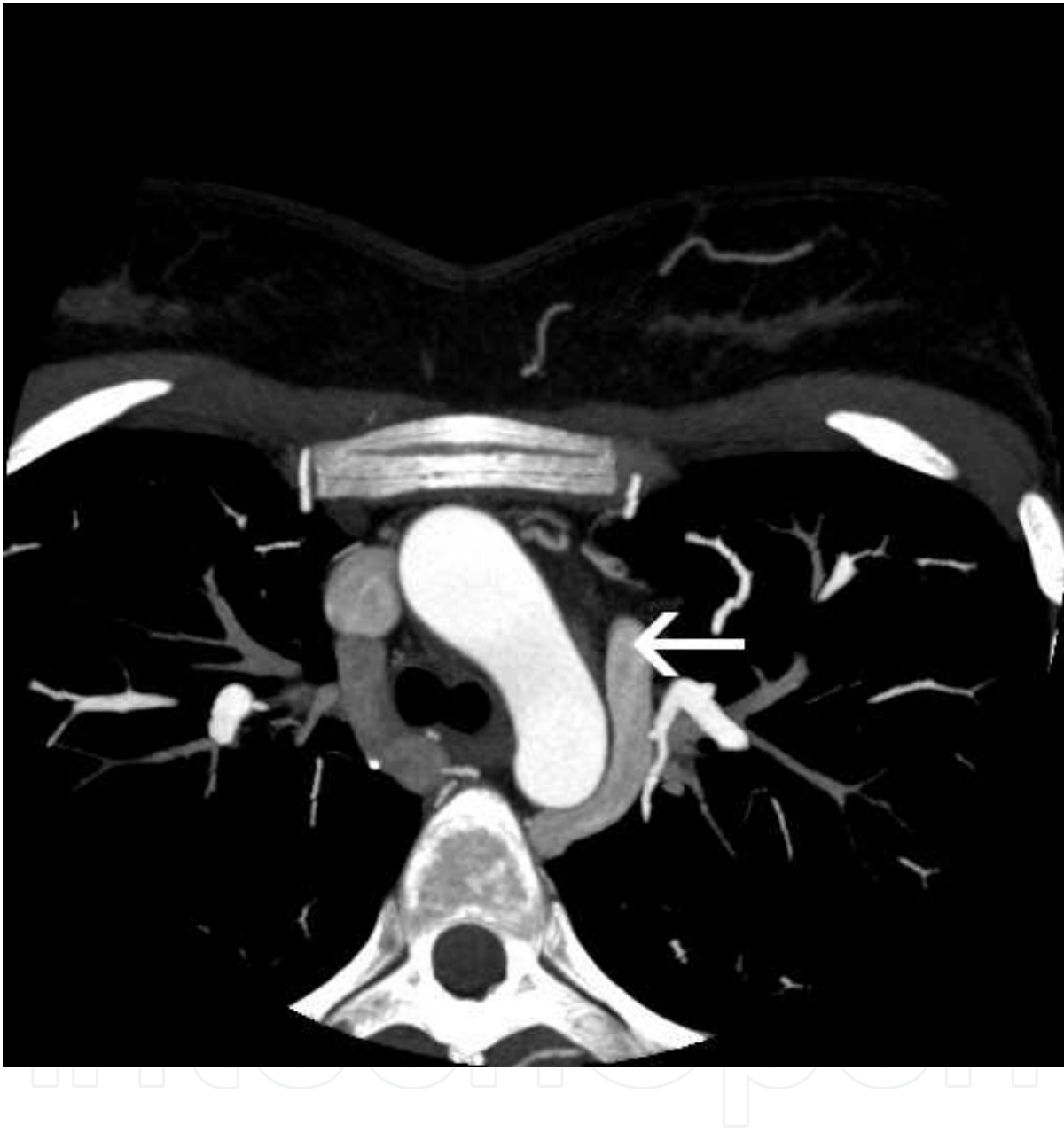


Fig. 12. Axial MIP reconstruction presents widening of accessory hemiazygos vein in a patients with absence of confluence of brachiocephalic trunks. Arrow indicates anomalous connection of left brahiocephalic trunk with accessory hemiazygos vein.

Both anomalies may be isolated and their frequency in general population is less then 0,3%. More often they are concomitant to other cardiovascular defects appearing up to 2% of these individuals. Typically, they are related with polysplenia-heterotaxy syndrome (Bronshtein et al., 2010), Figure 13.



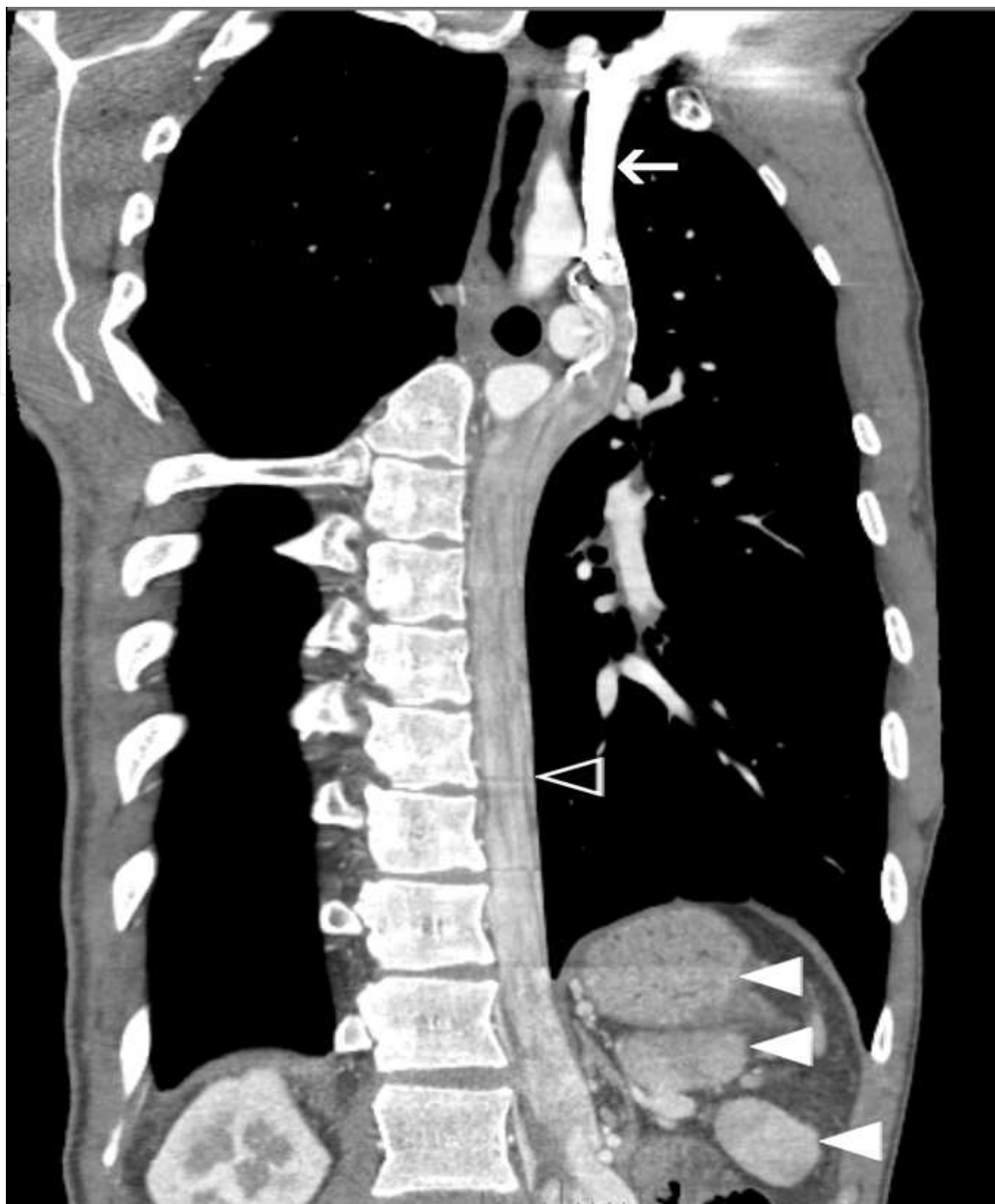


Fig. 13. Multiplanar curved line reformation of thoracic CT examination in a patient with heterotaxy-polysplenia syndrome. Arrow - PLSVC, blank arrowhead - hemiazygos vein, arrowheads - multiple spleens.

#### 4.3 Coronary sinus anomalies and coronary veins variants

Three systems of cardiac veins should be distinguished (von Lüdinghausen, 1987): tributaries of the coronary sinus, anterior cardiac veins and atrial cardiac veins. In morphological study of 350 dissected human hearts (von Lüdinghausen, 1987), it was observed, that in over a half of cases, coronary sinus collects blood from cardiac veins except for anterior cardiac veins, including small cardiac vein, which drain into the right atrium independent of the coronary sinus. In 21% of cases, all veins of the cardiac ventricles open into the right atrium via coronary sinus. Ostial valve of the coronary sinus (Thebesian valve) was observed by von Lüdinghausen in 80% of specimens, and almost in half of the cases it



was large. Such arrangement should be considered as a possible cause of problems with catheterization of the coronary sinus. In patients with narrowing or hypotrophy of coronary sinus ostium (Figure 14), accessory communications of cardiac veins can be visualized.

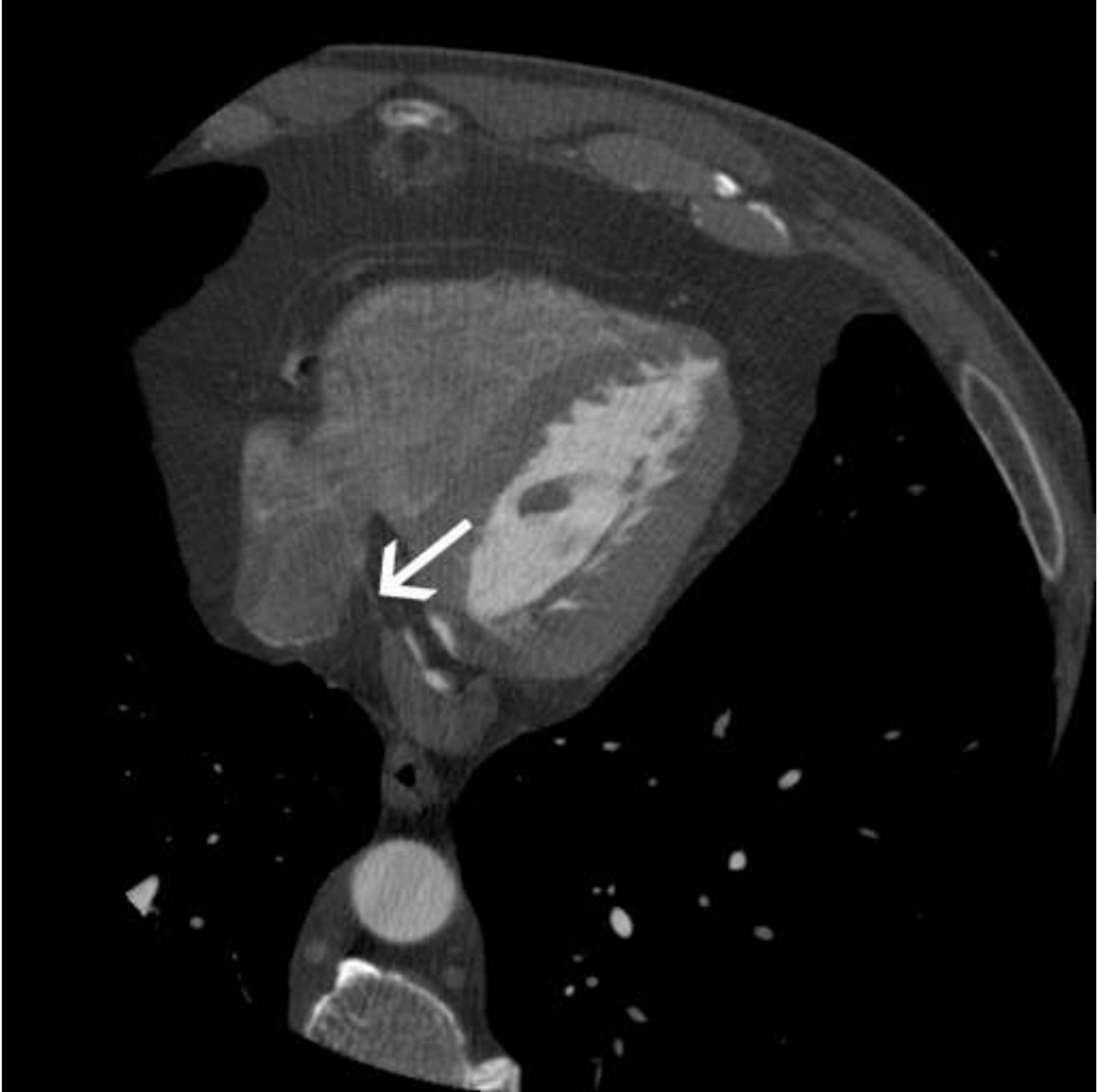


Fig. 14. Axial scan, CT. Narrowing of coronary sinus (arrow) ostium.

Figure 15 presents opening of great cardiac vein into SVC. Occasionally, anomalous communications of cardiac veins are seen, with L-R shunt between great cardiac vein and pulmonary veins (Figure 16).

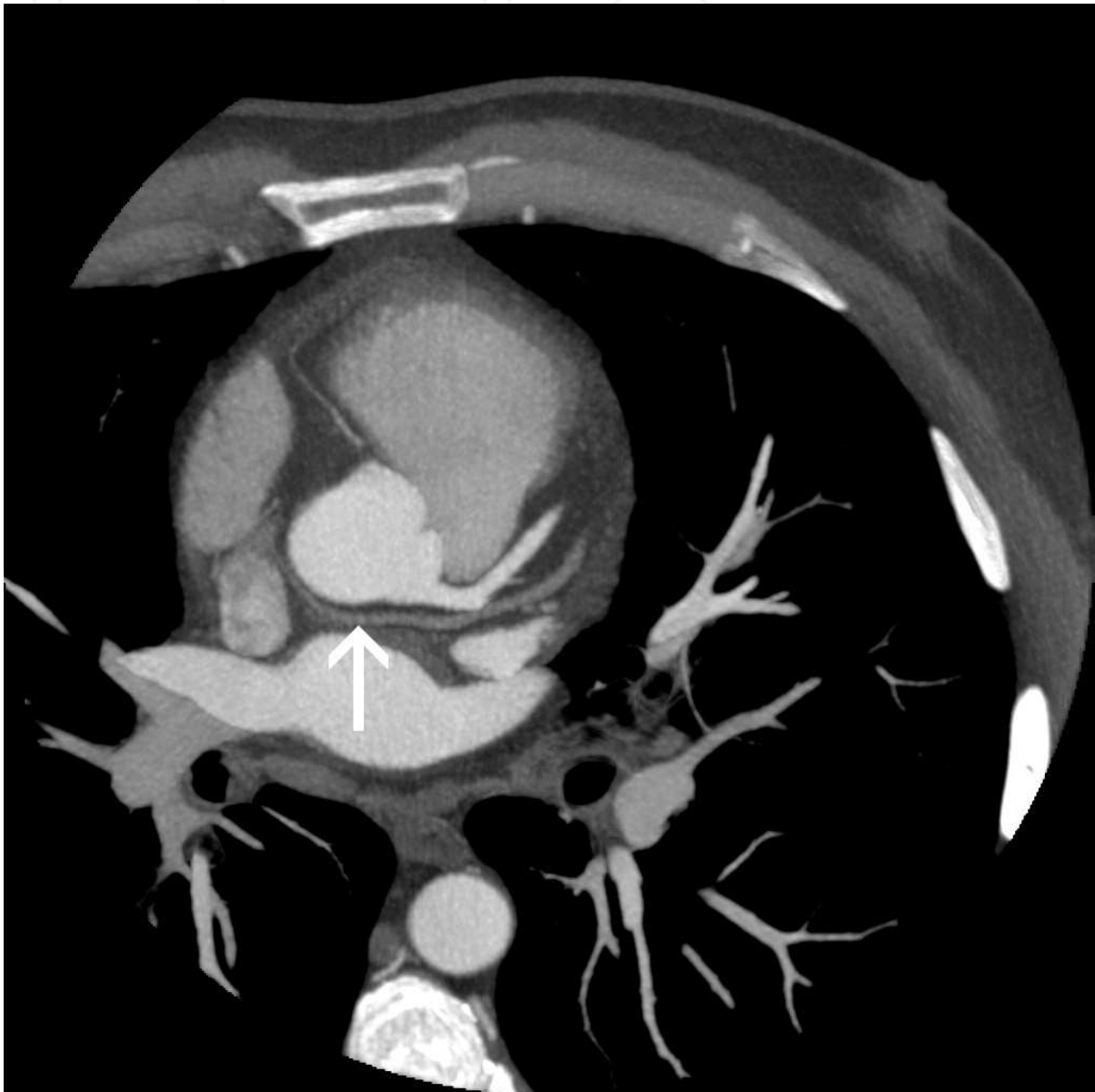

Fig. 15. Axial scan, maximum intensity projection. Anomalous course of great cardiac vein (arrow) with its opening into SVC.

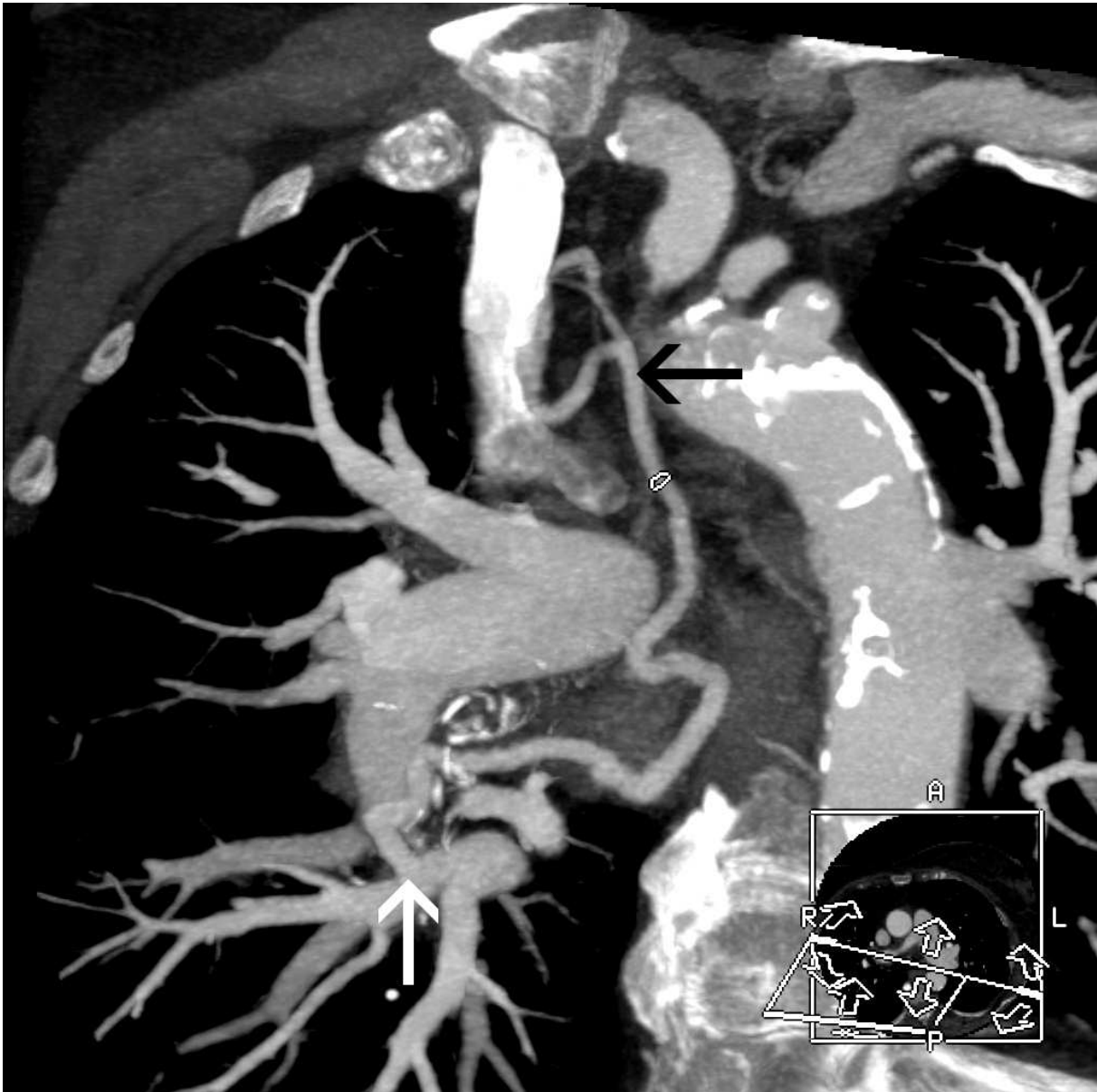


Fig. 16. Curved multiplanar reformation. L-R shunt between right inferior pulmonary vein (white arrow) and SVC via cardiac veins (black arrow)

#### 4.4 Pulmonary veins anomalies

As lungs are initially drained by a vascular plexus with multiple connections with cardinal veins, persistence of these connections may produce a persistent communication with systemic veins and formation of anomalous pulmonary venous return (APVR) (Moore, 1973). Typical formation of the left atrium involves formation of four separate pulmonary veins, however, disturbed regression of primitive pulmonary vein may produce accessory pulmonary veins, Figure 17, Figure 18.

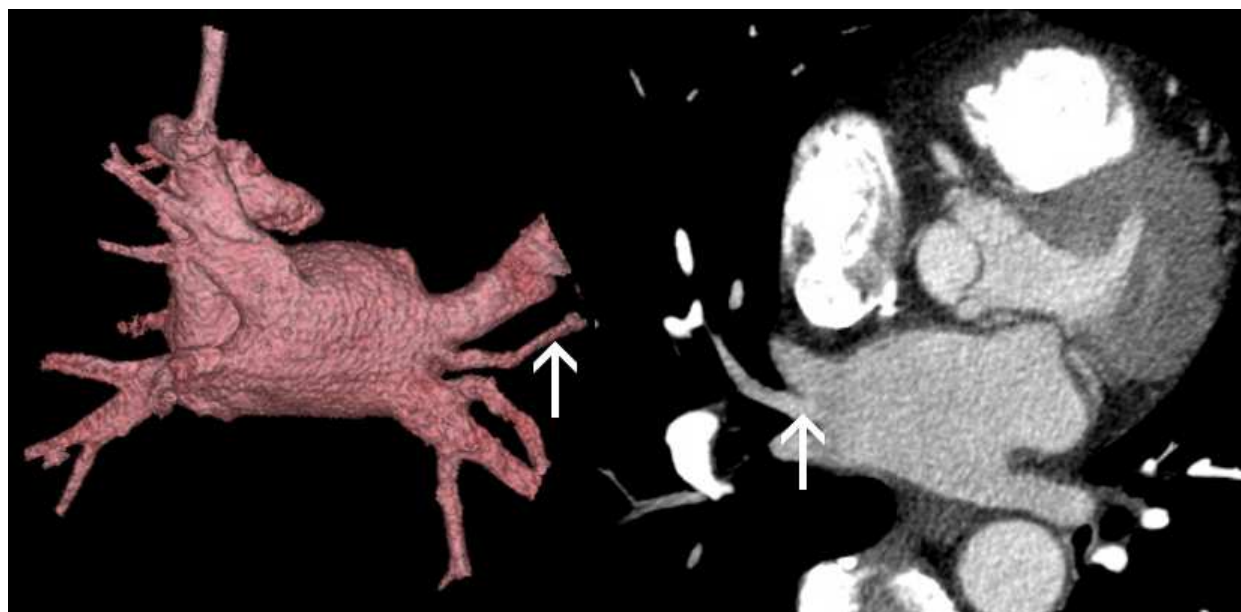


Fig. 17. Accessory middle right pulmonary vein (arrow) seen at volumetric reconstruction and axial scan.

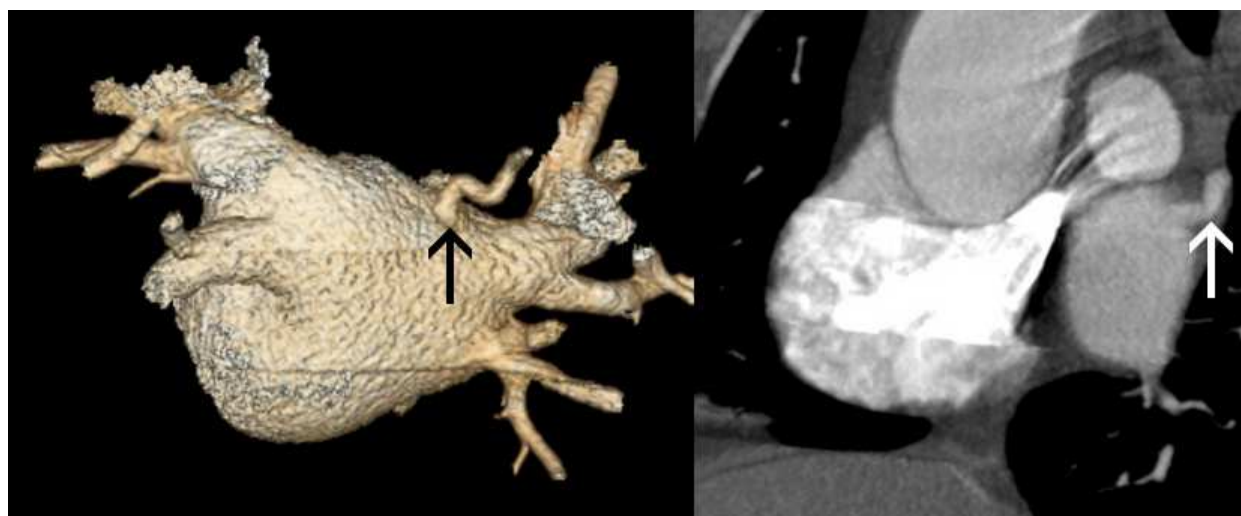


Fig. 18. Accessory posterior right pulmonary vein (arrow) seen at volumetric reconstruction and sagittal view.

Single pulmonary veins are a rare anomaly. Rey et al. (1986) reported group of patients with anomalous unilateral single pulmonary vein, which most frequently occurred on the right side, as in presented case (Figure 19). Bilateral single pulmonary veins are rarely reported, e.g. by Hidvegi and Lapin (1998).

Anomalous pulmonary venous return (APVR) may occur in the total or partial forms. Total anomalous pulmonary venous return is a more severe form of this anomaly, where all pulmonary veins drain outside of the left atrium, and are directed into right atrium via anomalous connections. TAPVR may produce severe symptoms, including cyanosis, difficulty breathing, low blood pressure and acidosis. Signs and symptoms are less severe in partial anomalous pulmonary venous return (PAPVR), which is an anomalous connection of



some of pulmonary veins into systemic circulation. PAPVR constitutes for about 1-2% of congenital heart malformations. It occurs in almost all cases of sinus venosus type of ASD and about 15% of ASD II.

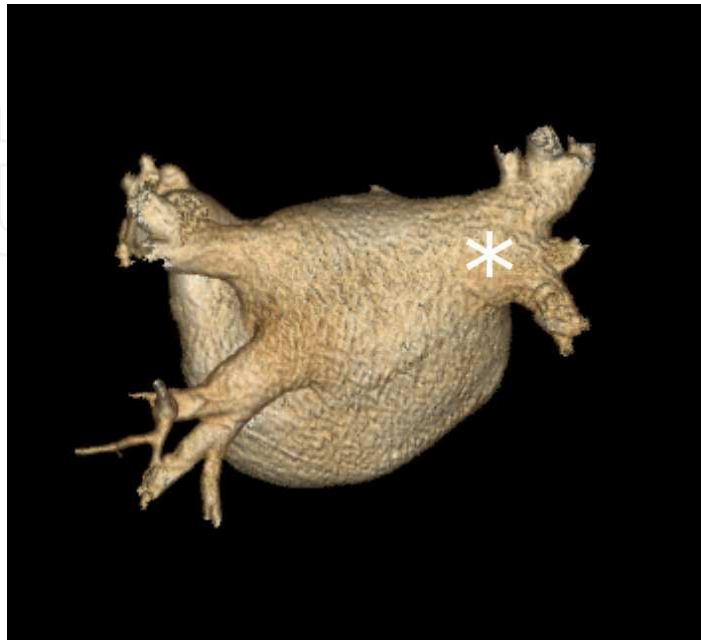


Fig. 19. Single pulmonary vein. Volumetric reconstruction, posterior view.

In right-sided PAPVR, anomalous drainage may carry blood from the right pulmonary vein into SVC, right atrium, inferior vena cava or infradiaphragmatic veins. When accompanied by hypoplastic right lung, it produces typical „scimitar syndrome“. Left sided PAPVR involves drainage via persistent vertical vein. In our retrospective review of 1840 cardiac CT examinations, we observed PAPVR in 23 cases. Right-sided PAPVR produced communication with SVC in 13 cases (Figure 20), right atrium - 3 cases (Figure 21) and into IVC (scimitar syndrome) in 1 case (Figure 22). Left-sided PAPVR involved 5 cases of pulmonary drainage into left brachiocephalic vein via vertical vein.

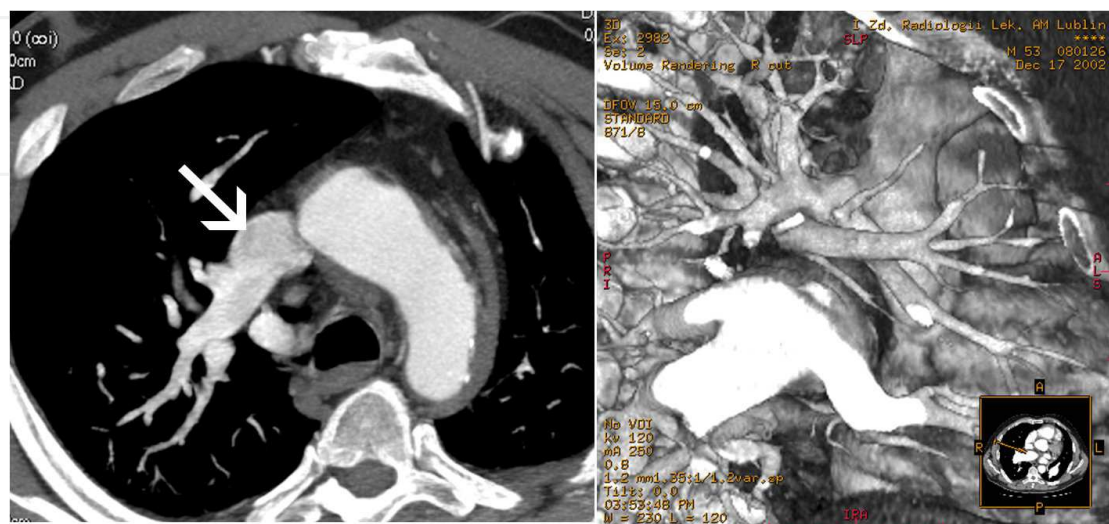


Fig. 20. PAPVR. Arrow indicates opening of pulmonary vein into SVC.

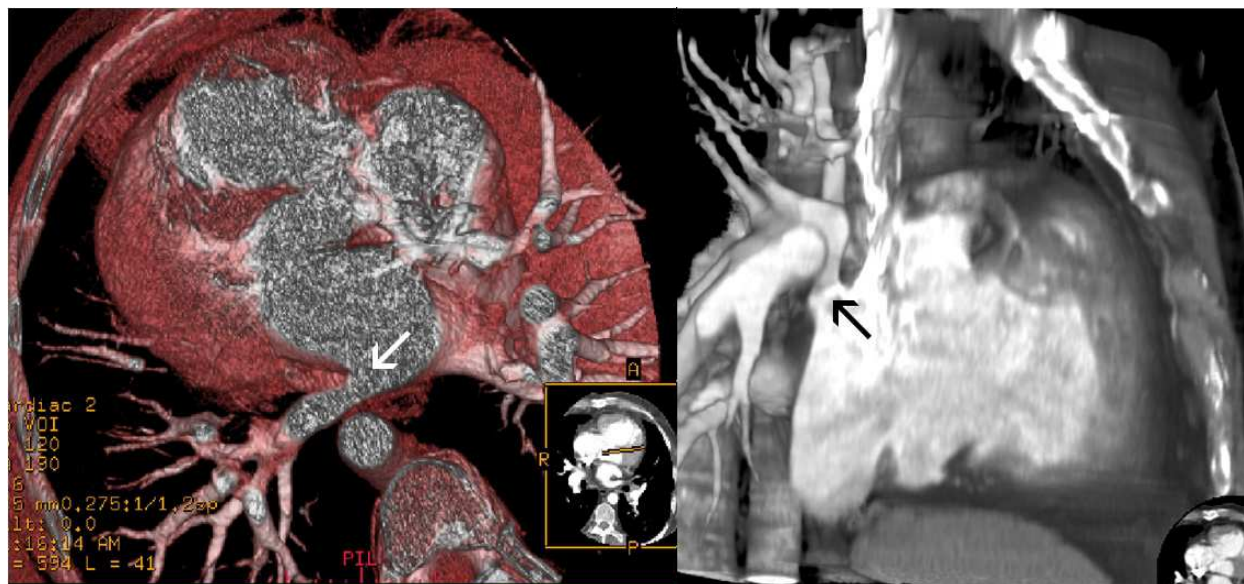


Fig. 21. PAPVR. Arrows indicate opening of pulmonary vein into right atrium

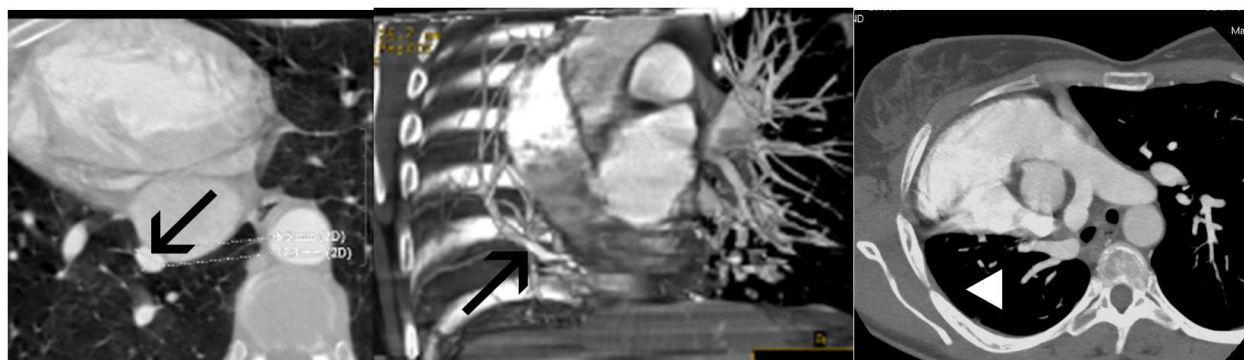


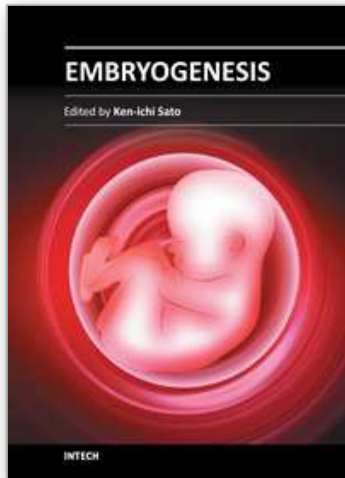
Fig. 22. Scimitar syndrome. Arrows indicate pulmonary vein draining hypoplastic right lung (arrowhead) into IVC.

## 5. References

- Anagnostopoulos P.V., Pearl J.M., Octave C., Cohen M., Gruessner A., Wintering E., Teodori M.F. (2009) Improved current era outcomes in patients with heterotaxy syndromes. *Eur J Cardiothorac Surg*; 35: 871-7; discussion 877-8.
- Ardilouze P., Bricot V., Maurel C., Christiaens L. (2009) A rare case of left superior vena cava draining into left atrium demonstrated by MDCT. *Int J Cardiol*; 131: e65-6.
- Arslan G., Cubuk M., Ozkaynak C., Sindel T., Luleci E. (2000) Absence of the azygos vein. *Clin Imaging*; 24: 157-158.
- Biffi M., Boriani G., Frabetti L., Bronzetti G., Branzi A. (2001) Left superior vena cava persistence in patients undergoing pacemaker or cardioverter-defibrillator implantation: a 10-year experience. *Chest*; 120: 139-144.
- Bronshtein M., Khatib N., Blumenfeld Z. (2010) Prenatal diagnosis and outcome of isolated interrupted inferior vena cava. *Am J Obstet Gynecol*; 202: 398.e1-398.e4.
- Caceres J., Mata J.M., Andreu J. (1998) The azygos lobe: normal variants that may simulate disease. *Eur J Radiol*; 27: 15-20.



- Demos T.C., Posniak H.V., Pierce K.L., Olson M.C., Muscato M. (2004) Venous anomalies of the thorax. *AJR Am J Roentgenol*; 182: 1139-1150.
- Dudek R.W., Fix J.D. (2004) Embryology, Lippincott Williams & Wilkins
- Enright T.R., Kanne J.P. (2010) Saccular superior vena cava aneurysm - incidental diagnosis by MDCT. *Clin Radiol*; 65: 421-422.
- Fang C.C., Jao Y.T., Han S.C., Wang S.P. (2007) Persistent left superior vena cava: multi-slice CT images and report of a case. *Int J Cardiol*; 121: 112-114.
- Fasouliotis S.J., Achiron R., Kivilevitch Z., Yagel S. (2002) The human fetal venous system: normal embryologic, anatomic, and physiologic characteristics and developmental abnormalities. *J Ultrasound Med*; 21: 1145-1158.
- Hidvegi R.S., Lapin J. (1998) Anomalous bilateral single pulmonary vein demonstrated by 3-dimensional reconstruction of helical computed tomographic angiography: case report. *Can Assoc Radiol J*; 49:262 -265.
- Ho V.B., Bakalov V.K., Cooley M., Van P.L., Hood M.N., Burklow T.R., Bondy C.A. (2004) Major vascular anomalies in Turner syndrome: prevalence and magnetic resonance angiographic features. *Circulation*; 110: 1694-1700.
- Horlitz M., Schley P., Thiel A., Shin D.I., Müller M., Klein R.M., Gülker H. (2006) Wolff-Parkinson-White syndrome associated with persistent left superior vena cava. *Clin Res Cardiol*; 95: 133-135.
- von Lüdinghausen M. (1987) Clinical anatomy of cardiac veins, Vv. cardiaca. *Surg Radiol Anat*; 9(2):159-68.
- Moore K.L. (1973) The developing human (clinically oriented embryology). Philadelphia, Pa: Saunders.
- Morgan D.R., Hanratty C.G., Dixon L.J., Trimble M., O'Keeffe D.B. (2002) Anomalies of cardiac venous drainage associated with abnormalities of cardiac conduction system. *Europace*; 4: 281-287.
- Ratliff H.L., Yousufuddin M., Lieving W.R., Watson B.E., Malas A., Rosencrance G, McCowan R.J. (2006) Persistent left superior vena cava: case reports and clinical implications. *Int J Cardiol*; 113: 242-246.
- Rey C., Vaksmann G., Francart C. (1986) Anomalous unilateral single pulmonary vein mimicking partial anomalous pulmonary venous return. *Cathet Cardiovasc Diagn*; 12:330 -333
- Tak T., Crouch E., Drake G.B. (2002) Persistent left superior vena cava: incidence, significance and clinical correlates. *Int J Cardiol*; 82: 91-93.
- Varma P.K., Dharan B.S., Ramachandran P., Neelakandhan K.S. (2003) Superior vena caval aneurysm. *Interact Cardiovasc Thorac Surg*; 2: 331-333.



## **Embryogenesis**

Edited by Dr. Ken-Ichi Sato

ISBN 978-953-51-0466-7

Hard cover, 652 pages

**Publisher** InTech

**Published online** 20, April, 2012

**Published in print edition** April, 2012

The book "Embryogenesis" is a compilation of cutting edge views of current trends in modern developmental biology, focusing on gametogenesis, fertilization, early and/or late embryogenesis in animals, plants, and some other small organisms. Each of 27 chapters contributed from the authorships of world-wide 20 countries provides an introduction as well as an in-depth review to classical as well as contemporary problems that challenge to understand how living organisms are born, grow, and reproduce at the levels from molecule and cell to individual.

### **How to reference**

In order to correctly reference this scholarly work, feel free to copy and paste the following:

Elżbieta Czekajska-Chehab, Sebastian Uhlig, Grzegorz Staśkiewicz and Andrzej Drop (2012). Congenital Anomalies of Thoracic Systemic and Pulmonary Veins Visualized with Computed Tomography, Embryogenesis, Dr. Ken-Ichi Sato (Ed.), ISBN: 978-953-51-0466-7, InTech, Available from: <http://www.intechopen.com/books/embryogenesis/congenital-anomalies-of-systemic-and-pulmonary-veins-visualized-with-computed-tomography->

# **INTECH**

open science | open minds

### **InTech Europe**

University Campus STeP Ri  
Slavka Krautzeka 83/A  
51000 Rijeka, Croatia  
Phone: +385 (51) 770 447  
Fax: +385 (51) 686 166  
[www.intechopen.com](http://www.intechopen.com)

### **InTech China**

Unit 405, Office Block, Hotel Equatorial Shanghai  
No.65, Yan An Road (West), Shanghai, 200040, China  
中国上海市延安西路65号上海国际贵都大饭店办公楼405单元  
Phone: +86-21-62489820  
Fax: +86-21-62489821

© 2012 The Author(s). Licensee IntechOpen. This is an open access article distributed under the terms of the [Creative Commons Attribution 3.0 License](#), which permits unrestricted use, distribution, and reproduction in any medium, provided the original work is properly cited.

IntechOpen

IntechOpen