

We are IntechOpen, the world's leading publisher of Open Access books Built by scientists, for scientists

4,500

Open access books available

118,000

International authors and editors

130M

Downloads

Our authors are among the

154

Countries delivered to

TOP 1%

most cited scientists

12.2%

Contributors from top 500 universities



WEB OF SCIENCE™

Selection of our books indexed in the Book Citation Index
in Web of Science™ Core Collection (BKCI)

Interested in publishing with us?
Contact book.department@intechopen.com

Numbers displayed above are based on latest data collected.
For more information visit www.intechopen.com



Defining Dental Age for Chronological Age Determination

Fatma Deniz Uzuner, Emine Kaygısız and
Nilüfer Darendeliler

Additional information is available at the end of the chapter

<http://dx.doi.org/10.5772/intechopen.71699>

Abstract

Dental age assessment is one of the most reliable methods of chronological age estimation used for criminal, forensic and anthropologic purposes. Visual, radiographic, chemical and histological techniques can be used for dental age estimation. Visual method is based on the sequence of eruption of the teeth and morphological changes that are caused due to function such as attrition, changes in color that are indicators of aging. Radiographs of the dentition can be used to determine the stage of dental development of the teeth from initial mineralization of a tooth, crown formation to root apex maturation. Histological methods require the preparation of the tissues for detailed microscopic examination. The chemical analysis of dental hard tissues determines alterations in ion levels with age, whereas the histological and chemical methods are invasive methods requiring extraction/sectioning of the tooth. In this chapter, the different techniques and considered studies were overviewed in conjunction with their advantages and disadvantages. It needs to be taken into consideration that rather than restricting on one age estimation technique, using the other available techniques additionally and performing repetitive measurements may be beneficial for accurate age estimation.

Keywords: chronologic age estimation, dental maturation, dental age

1. Introduction

Determination of the age is of great importance for the identification of unknown bodies or skeletal remains in forensics and anthropology [1]. In postmortem examination, the quality and quantity of the mortal remains such as the time passed between autopsy and death, environmental conditions and structure of the bodily remains or skeletal parts are critical factors. Additionally, it may also depend on other case-specific factors, such as costs, the time and equipment required.

For the age estimation, considering those critical factors, there are several methods available. Teeth can act as a biological marker of aging [2]. Teeth have highly mineralized structure, which makes them resistant to the postmortem decomposition and generally withstand flames, alkalis or acids [3]. Even bone may disintegrate, but teeth can be preserved for a long time and thus can be used reliably for identification in disaster situations [4].

Dental maturity is one of the most reliable indicators of chronological age estimation method used for criminal, forensic and anthropologic purposes [5–8]. Visual, radiographic, chemical and histological techniques can be used for dental age estimation [1, 9–11]. In this chapter, the stages of tooth formation/maturation, the chronology of tooth eruption and its relationship to age will be explained in detail. Methods of dental age estimation will be defined with their strength and limitations. The factors that may affect the dental maturation will be evaluated.

2. Chronology of tooth development

The development of the dentition is a continuous process that extends from embryonic to early adult life and it may be divided into a number of stages.

The sequence of prenatal mineralization in the deciduous teeth starts with the central incisor followed by the first molar, lateral incisor, canine and second molar. The maxillary central incisors and first molars are usually seen before those in the mandible. The lateral incisor appears first in the maxilla, but subsequent development is ahead in the mandible. Mineralization occurs in the mandibular canine before that in the maxilla, but it occurs simultaneously in the maxillary and mandibular second molars (**Table 1**) [12].

At the beginning of mineralization, tooth germs may be visible as radiolucent areas on the radiograph up to 6 months. A radiograph of the fetus taken at 26 weeks of intrauterine life shows advanced mineralization in mandibular anterior teeth. The mineralized outline for the

Tooth	Calcification begins		Crown completed		Eruption		Root completed	
	Maxillary	Mandibular	Maxillary	Mandibular	Maxillary	Mandibular	Maxillary	Mandibular
Central	14 wk in utero	14 wk in utero	11/2 mo	21/2 mo	10 mo	8 mo	11/2 yr	11/2 yr
Lateral	16 wk in utero	16 wk in utero	21/2 mo	3 mo	11 mo	13 mo	2 yr	11/2 yr
Canine	17 wk in utero	17 wk in utero	9 mo	9 mo	19 mo	20 mo	31/4 yr	31/4 yr
First molar	15 wk in utero	15 wk in utero	6 mo	51/2 mo	16 mo	16 mo	21/2 yr	21/4 yr
Second molar	19 wk in utero	18 wk in utero	11 mo	10 mo	29 mo	27 mo	3 yr	3 yr

Table 1. Chronology of deciduous tooth development mentioned by Proffit et al [12].

two cusps of the deciduous first molar, the one cusp outline for the deciduous second molar and the crypt of permanent first molar are seen [13, 14]. At 30 weeks of intrauterine life, mandibular anterior teeth shows 3/5 crown completion and the deciduous first molar cusps show fusion. The deciduous second molar with five cusps is seen, while no mineralization in the permanent first molar is observed. While the radiograph of the newly born fetus shows completely fused cusps for the deciduous first and second molar, for the deciduous second molar, there is no continuity across the occlusal surface [15]. At 32 weeks, the first permanent molars start to mineralize [12].

By birth, the deciduous incisors have about 60–80% of their crowns complete and canine crowns are a simple conical shape and approximately 30% fully formed [9]. The first deciduous molars have a complete occlusal cap of mineralized tissue, the maxillary tooth being more fully calcified than the other molars.

The eruption sequence of deciduous teeth in oral cavity is as follows: first, the mandibular central incisors erupt followed by other incisors. After 3–4 months, the mandibular and maxillary first molars erupt, followed, in another 3 or 4 months, by the maxillary and mandibular canines. The deciduous dentition is completed at 24–30 months as the second molars in both jaws erupt [12]. By the age of about 3 years, the deciduous dentition has emerged into the mouth and completed root formation (Table 1).

The transition from the deciduous to the permanent dentition is summarized in Table 2 [12].

Except the third molars, all of the permanent teeth eruption takes place in two stages, between the ages of about 6 and 8 years followed by a silent period and again between 10 and 12 years. The first active stage begins at about age 6 with the eruption of the first permanent molars behind the second deciduous molar followed by the permanent incisors. The general eruption sequence is the mandibular central incisor, followed by the maxillary central and the mandibular

Tooth	Calcification begins		Crown completed		Eruption		Root completed	
	Maxillary	Mandibular	Maxillary	Mandibular	Maxillary	Mandibular	Maxillary	Mandibular
Central	3 mo	3 mo	4 1/2 yr	3 1/2 yr	7 1/4 yr	6 1/4 yr	10 1/2 yr	9 1/2 yr
Lateral	11 mo	3 mo	5 1/2 yr	4 yr	8 1/4 yr	7 1/2 yr	11 yr	10 yr
Canine	4 mo	4 mo	6 yr	5 3/4 yr	11 1/2 yr	10 1/2 yr	13 1/2 yr	12 3/4 yr
First premolar	20 mo	22 mo	7 yr	6 3/4 yr	10 1/4 yr	10 1/2 yr	13 1/2 yr	13 1/2 yr
Second premolar	27 mo	28 mo	7 3/4 yr	7 1/2 yr	11 yr	11 1/4 yr	14 1/2 yr	15 yr
First molar	32 wk in utero	32 wk in utero	4 1/4 yr	3 3/4 yr	6 1/4 yr	6 yr	10 1/2 yr	10 1/2 yr
Second molar	27 mo	27 mo	7 3/4 yr	7 1/2 yr	12 1/2 yr	12 yr	15 3/4 yr	16 yr
Third molar	8 yr	9 yr	14 yr	14 yr	20 yr	20 yr	22 yr	22 yr

Table 2. Chronology of permanent tooth development mentioned by Proffit et al [12].

lateral incisors about a year later, and finally the maxillary laterals. There is a silent period of 1.5–2 years before the second active stage begins. This involves the exfoliation of deciduous canines and molars and replacement by permanent canines and premolars, together with the eruption of the second permanent molars. On the other hand, the third molars appear late in development stage. They usually start mineralization between 6 and 12 years, complete their crowns in 4 years and erupt and complete development during adolescence or early adulthood [12].

The total time taken for an individual tooth to develop is considerable, lasting from 2 to 3 years for the deciduous teeth and up to 8–12 years for the permanent teeth. In general, anterior permanent tooth crowns take 4–5 years and molar tooth crowns 3–4 years [16] and roots take approximately 6–7 years to grow. It has to be taken into consideration that the described general eruption sequence may change between individuals and genders. Tooth eruption is a complex process that can be influenced by several factors such as genetics, nutrition, preterm birth, gender differences, socioeconomic factors, craniofacial morphology, hormonal factors and various systemic diseases, which may cause earlier or delayed eruption [12]. Gender differences in the timing and duration of tooth formation are known, with dental maturity generally being more advanced in females than in males in permanent dentition in reverse of those for the deciduous dentition [17].

3. Dental age estimation methods

In literature, various methods are defined for dental age assessment that can be categorized as: visual, radiological, morphological, biochemical and histological methods [1, 18–21].

3.1. Visual method

Visual method is based on the evaluation of the sequence of teeth eruption in oral cavity and the morphological changes on tooth structure due to functions such as attrition, changes in color that are indicators of aging.

Fully formed teeth show aging changes. Thus, examination of dentition considering the tooth wear/attrition, tooth color and stains, periodontal status, etc. can provide valuable information on an individual's development and age [1, 18, 19, 21].

3.1.1. Evaluating tooth eruption

Tooth eruption in oral cavity follows a typical chronological pattern. As it was summarized in the above section, visual examination of the maxillary and mandibular dental arch may provide the dental age estimation up to 12–13 years of age in correspondence to the second molar eruption.

3.1.2. Tooth wear and attrition

Being a simple and convenient method, tooth wear is commonly used as a tool of individual's age estimation. Naturally, tooth wear increases with age. It is proportional to the time of

exposure of teeth to the oral cavity [21]. This method does not need any invasive process such as tooth extraction or tissue preparation.

Tooth wear can be evaluated in conjunction to two different types of criteria: one is the area of tooth wear, which may be termed as a horizontal factor, and the second is the degree of dentin exposure, termed as a vertical factor. The combination of both horizontal and vertical factors should be considered to obtain a more accurate estimation of age [21, 22]. Hongwei and Jingtao [23] classified tooth wear scores into a 0- to 9-point scale based on the pattern, number and amount of tooth wear. Kim et al. [21] defined another simple and reliable scoring system, which can be applied to age estimation of individuals at any age ranges, as well (Table 3).

Tooth eruption being one of the visual methods in age estimation is considered to be not so reliable, as eruption is an ongoing process that includes inactive periods in a child's life when no tooth eruption occurs. It is also scarcely influenced by a number of local factors, such as the premature extraction of primary teeth causing a lack of space or the crowding of permanent teeth and systemic factors such as hereditary, functional, environmental, sexual, nutritional and metabolic factors [7, 24].

The secondary method, tooth wear, was defended to be an accurate method [23]; on the contrary, some authors advocated that tooth wear may not be reliable in age estimation [25]. As tooth wear is influenced by various factors that include functional (eating and chewing habits) or parafunctional habits, patterns of mandibular movement, bite force, saliva, diet, medication, diseases, geographical location, occupational and habitual environment and gender [21, 26].

Score	Premolar	Molar
0	No visible wear	
1	1P/1L	1P/1L/2P/2L
2	2P/2L/1S/1B	3P/3L/4P/4L/1S/1B/2S/2B
3	2S/2B	3S/3B/4S/4B
4	Wear on more than 2/3 occlusal surface	
5	1Pc/1Lc	1Pc/1Lc/2Pc/2Lc
6	2Pc/2Lc/1Sc/1Bc	3Pc/3Lc/4Pc/4Lc/1Sc/1Bc/2Sc/2Bc
7	2Sc/2Bc	3Sc/3Bc/4Sc/4Bc
8	Concavity on more than 2/3 occlusal surface	

Table 3. The Kim's scoring system of tooth wear [21]. P: point-like wear facet < ~1 mm. in diameter; L: linear wear facet < ~1 mm. in width; S: surface-like wear facet > ~1 mm. in diameter; B: band-like wear facet > ~1 mm. in width or wear facet involving more than two surfaces; c: concavity (wear of dentine). In the situation where a tooth has several different degrees of tooth wear, the highest degree should be selected as tooth wear score.

3.2. Radiographic methods

Dental age may be estimated by two approaches: based on the time of emergence of the tooth in the oral cavity and the pattern of tooth development, in another word the dental maturity

stages. Dental maturity is considered to be more reliable than the emergence of teeth into the oral cavity with a high heritability and low coefficient variation, and to be independent of environmental effects, nutritional and endocrine status [6–8]. The development of each tooth can be assessed over long periods of time using radiographs in a continuous pattern, using different crown and root maturity stages of tooth formation as criteria [27, 28]. Radiological methods are based on the evaluation of tooth development on the various radiographic images as intraoral periapical, panoramic radiographs, digital and advanced imaging technologies to assess the extent of tooth mineralization from the moment when radiopaque spots become visible prior to tooth calcification until the tooth apex is closed (**Figure 1**) [10].

Beginning from the initial mineralization of a tooth, the crown formation, root growth, eruption of the tooth into the mouth and root apex maturation are assessed. Given that this method enables continuous evaluation of tooth development from birth until the completion of third molar teeth development [24, 29], it is mainly suitable for children-adolescents. It is also simple, a noninvasive and reproducible method that can be employed both on living and unknown dead.

The age determination on radiographs is based on the estimation of various features as follows:

1. Tooth germs appearance [14, 15, 30]
2. Beginning of mineralization both in the intrauterine life and after birth [14, 15, 30]
3. Amount of crown completion [14, 30, 31]
4. Eruption into the oral cavity [13–15, 30]
5. Degree of root completion of erupted or unerupted teeth [14, 15, 30]
6. Degree of resorption of deciduous teeth [14, 15]
7. Measurement of open apices [32, 33]
8. Volume of pulp chamber and root canals/formation of physiological secondary dentine [14, 34]
9. Tooth-to-pulp ratio [34, 35]
10. Third molar maturity [14, 15, 30, 34]

In children and adolescents, the chronological age estimation based on dental maturation is mainly done either by using the atlas approach or by using scoring systems. The dental development is divided into different stages that are assigned maturity scores for each tooth, evaluated through statistical analysis and then compared to known age standards in the “scoring method” [36].

3.2.1. Atlas method

The radiographic dental mineralization is compared with dental atlases that include a series of drawings with outlines of developing teeth and eruption relative to a corresponding age in the “Atlas method.”

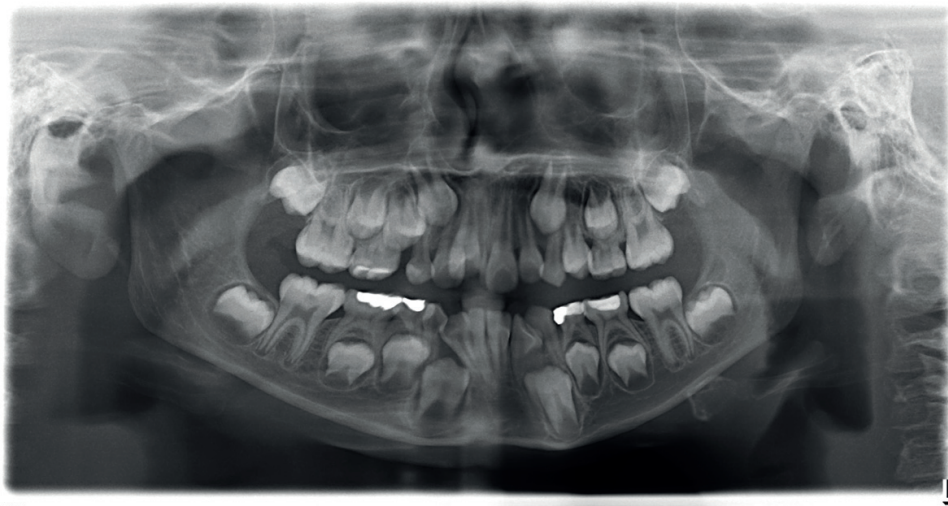


Figure 1. Panographic radiograph.

Kraus and Jordan [37] studied the early mineralization of teeth—deciduous teeth and the permanent first molar as well—in the intrauterine life. The development is described in 10 stages, expressed by Roman numerals from I to X; the IXth stage includes three stages and the Xth stage includes five stages [14]. Schour and Masseler [38, 39] studied the development of deciduous and permanent teeth, describing 21 chronological steps from 4 months to 21 years of age and published the numerical development charts for them without considering gender differences. Moorees et al. [40] evaluated the dental development in the 14 stages of mineralization ranging from ‘cusp formation’ to ‘root apex closure’ for developing single and multirooted permanent teeth by using panoramic or lateral oblique radiographs and the mean age for the corresponding stage was determined (**Figure 2**), taking into account the gender differences. Different tables are designed for each gender [41]. It provides an age estimate from 6 months up to the development of the third mandibular molar.

Later on, Anderson et al. [42] revised the method of Moorees et al. [40] by expanding the age range and comprehensive tables.

The London Atlas published by AlQahtani and colleagues [43] is a major improvement in estimating age compared to other dental charts and may be more practical than other dental atlases [44–46] with its high level of accuracy and repeatability. It provides an age estimate for individuals aged 28 weeks in utero to young individuals up to 23 years, so it enables the usage of the third molar. In addition, it can be used in cases where sex cannot be determined, as it provides sex-specific and sex-neutral dental charts [46]. Age is defined as the midpoint of an age category without an age range in the London Atlas. This could lead to a variation among investigators with the levels of education or experience.

3.2.2. Scoring method

Nolla [47] assessed the development of each tooth by evaluating the mineralization of permanent dentition in 10 stages. The radiograph of the patient is matched with a comparative figure and a total of the maxillary and mandibular teeth are assigned and the total is compared with

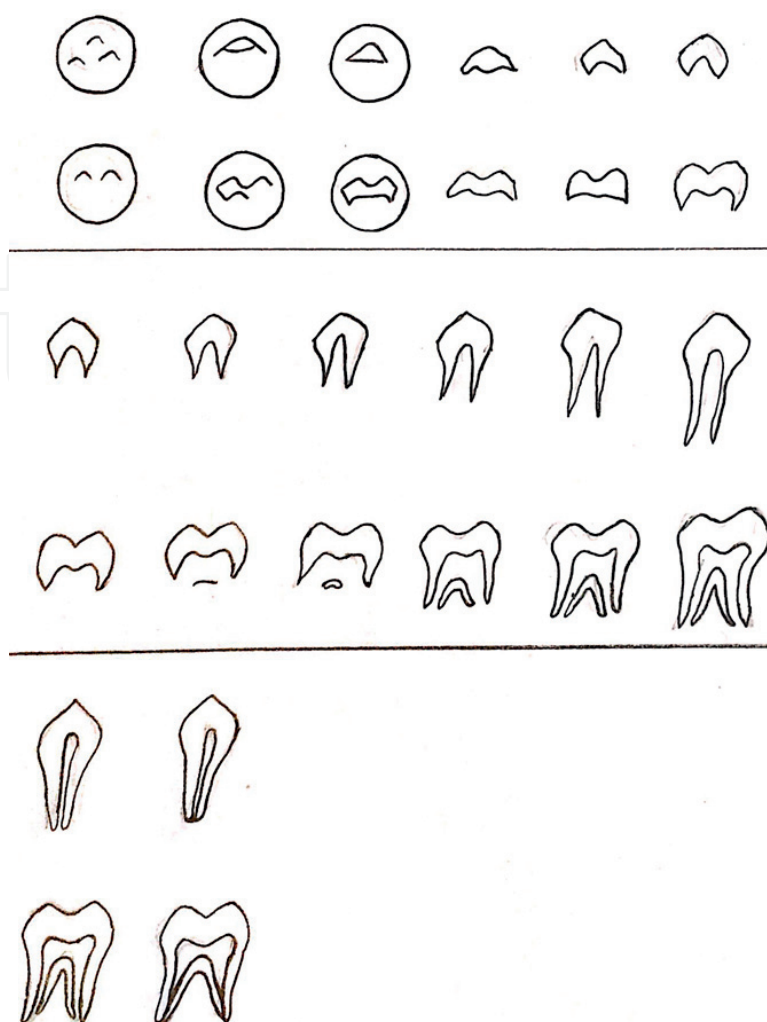


Figure 2. Schematic diagrams of the 14 dental development stages ranging from 'cusp formation' to 'root apex closure' defined by Moorees et al.

the table given by Nolla. The advantages of this method are that it can be applied to an individual with or without the third molar and that girls and boys are dealt with separately. Nolla's method allows the researcher to choose a stage from the 10 stages and also offers three inter-stage options for each stage. The increased number of stages may complicate the assessment and decrease accuracy of the method [48].

Different from Nolla's method instead of evaluating both maxillary and mandibular teeth, Demirjian et al. [49] determined only the dental maturity of the mandibular left seven permanent teeth (second molar to central incisors) based on eight tooth mineralization stages ("A" through "H") on a panoramic radiograph (**Figure 3**). The stages were allocated a biologically weighted score for each gender, and the sum of the scores provided an estimate of dental maturity, which was measured on a scale from 0 to 100 [49]. It was also reported to be reliable and reproducible [50].

Later, Demirjian and colleagues [51] developed three more methods, all of which are based on the analysis of the left mandibular dentition, but differ in relation to the type and/or number of



Figure 3. Schematic representation of the Demirjian, Goldstein and Tanner's stages: (A) in both uniradicular and multiradicular teeth, a beginning of calcification is seen at the superior level of the crypt in the form of an inverted cone or cones. There is no fusion of these calcification points; (B) fusion of calcified points forms one or more cusps, which unite to give a regularly outlined occlusal surface, or mineralized cusps are united so the mature coronal morphology is well defined; (C) crown half-formed, pulp chamber is evident, and dentinal deposition is occurring; (D) the crown formation is completed down to the cemento-enamel junction (CEJ), pulp chamber has a trapezoidal form and beginning of root formation is seen; (E) initial formation of the radicular bifurcation is seen, and the root length is still less than the crown height; (F) the apex ends in a funnel shape; the root length is equal to or greater than the crown height; (G) the walls of the root canal are now parallel and its apical end is still partially open and (H) the apical end of the root canal is completely closed; the periodontal membrane has a uniform width around the root and the apex.

teeth used. These methods are as follows: 1. revised seven-tooth system [same teeth but with extended age ranges and two extra stages]; 2. four-teeth method [second molar (M2) to first premolar (PM1) inclusive]; and 3. Alternate four-teeth approach [the second incisor [12], first premolar [PM1], second premolar [PM2] and second molar [M2] [51, 52].

Although this method is reported to be simple, reliable and reproducible [50], it has some limitations as follows [30, 53, 54]:

1. This method excludes the subjects below the age of 4–4.5 years.
2. The evaluation cannot be applied in children lacking teeth.
3. This method may not express the retardation of dental development [excluding third molars] due to systemic diseases.
4. This method was developed based on the radiographic analysis of French-Canadian sub-adults; however, there may be a variation in the timing of dental development, both within and among the different populations in specific geographic regions [17, 55]. This may be attributed to different gene pools, differences in living conditions, climate, socioeconomic status, nutrition and secular changes [56–58] When the Demirjian data set was used for different populations, it mostly overestimated the age rather than underestimated it [59], which means that the subjects studied exhibited dentally advanced development compared with French-Canadian children [60]. Although some authors [29, 61] reject the applicability of the Demirjian standards in different populations, the others [62–65] support the applicability of these standards in particular age groups. Demirjian et al. [49] conjectured that the

scores for the stages would not vary much between populations, but the maturity standards may change appreciably.

The application of age estimation methods to populations that are dissimilar to the sample from which a particular method is derived is a critical issue in this field [46]. To overcome this drawback, the calculation of several 'modified' versions of the original Demirjian tables for different populations is offered [66–68]. The population-specific standards based on dental maturity curves are reported to be more accurate than the original curves [7, 24, 51, 69], but the variation among the geographical areas or different regions within the same country will still exist [70]. From another perspective, Liversidge et al. [62] mentioned that a positive secular trend during the last 25 years may partially explain the dental age overestimation by Demirjian's method recently found in different populations. In support, certain researchers have reported that dental development and age also follow secular trends and that teeth mature at an earlier chronological age than several decades ago [62, 71]. If the secular trend exists, correction of the reference standard that was developed using an affluent segment of more developed nations is significant for forensics, if the subject for which a dental age estimate is necessary is from a lower socioeconomic status in a developing country [72]. However, the other authors claimed that the level of tooth formation is not affected by secular trend, as it is predominantly determined by genetics, and less affected by environmental factors than other growth systems [73].

Willems [74] modified Demirjian's method based on a study on Belgian Caucasian population and formed new tables for the dental maturity for both genders by calculating chronological age based on the cumulative score of 4 teeth—first premolar, second premolar, first molar and second molar. This method is simpler and retains the advantage of Demirjian's method and there was a reduction in the overestimation of dental age. The estimated dental age is reported to be more accurate than Demirjian's method [75, 76].

Haavikko's method [77] is another method assessing the maturity of the teeth. Twelve radiographic stages—six relating to crown formation and six relating to root formation—of 4 permanent teeth are used to assess the dental age. This method is useful when any of the permanent teeth is missed.

As distinct from the methods evaluating the dental maturity, Cameriere et al. [33] measured open apices of the seven left permanent mandibular teeth in nonadults. They developed a linear regression formula for dental age estimation [46]. The following regression formula for age estimation is used

$$\text{Age} = 8.971 + 0.375 g + 1.631 \times 5 + 0.674 N0 - 1.034 s - 0.176sN0 \quad (1)$$

where g is a variable equal to 1 for boys and 0 for girls, $N0$ is the number of teeth with apical ends of the root completely closed. The teeth with open apices are also considered. For teeth with one root, the distance between the inner sides of the open apex is measured, and for two roots, the sum of the distances between the inner sides of the two open apices is evaluated. To eliminate the magnification and angulation of the radiographs, the measurement of open apex is divided by the tooth length for each tooth. So, the measurements are normalized. Finally, s is the sum of the normalized open apices of the seven left permanent mandibular teeth.

In childhood and adolescent period, observing dentition maturity stages with radiographic method results in highly accurate age assessments. However, with increasing age, this

method's accuracy will be weakened. The third molar is the only tooth with a tendency to continue developmental changes in late adolescence and early adulthood [5]. Third molar calcification stage is one of the few tools that can be used to assess age when development is nearing completion [8, 48, 50]. Many authors evaluated the third molar's maturity stages. Harris and Nortje [78] have given five stages of third molar root development in correspondence to the mean ages and mean length. Van Heerden [79] assessed the development of the mesial root of the third molar in five stages.

Clinically, the development of permanent dentition completes with the eruption of the third molar at the age of 17–21 years, after which the radiographic age estimation becomes difficult. However, this accuracy decreases as a person's dental development is completed. After that period, mature teeth cannot be used to estimate age because the time they completed developmental stages is unknown [48]. So that, other methods have to be used to estimate age by radiological determination. The reduction in size of the pulp cavity resulting from a secondary dentine deposition, which is proportional to the age of the individual, is one age predictor measurable in dental radiographs and tomographs as an alternative to more invasive methods [80–84]. In literature, two methods have been used:

1. Pulp-to-tooth ratio method by Kvaal [85]
2. Coronal pulp cavity index [86].

The coronal pulp cavity index [86] calculates the correlation between the reduction of the coronal pulp cavity and the chronological age. Only mandibular premolars and molars were considered on panoramic radiographs. The tooth-coronal index (TCI) is calculated for each tooth and regressed on the real age of the sample using the formula

$$\text{TCI} = \text{CPCH} \times 100/\text{CL}. \quad (2)$$

where CPCH is the length of the coronal pulp cavity and CL is the length of the tooth crown.

Pulp-to-tooth ratio method: Kvall et al. calculated the pulp-tooth ratio for six mandibular and maxillary teeth, such as maxillary central and lateral incisors; maxillary second premolars; mandibular lateral incisor; mandibular canine and the first premolar (**Figure 4**). It is available to remove doubt as to whether a person is under 18 years of age and to calculate the age above this level. They measured pulp length and width as well as root length and width. Because of magnification and angulation on the radiographs, different ratios between root and pulp were measured.

The age is derived by using pulp-to-tooth ratios in the formula:

$$\text{Age} = 129.8 - [316.4 \times m] [6.8 \times [W - L]]. \quad (3)$$

It has been reported that the pulp/tooth volume ratios in the cervical area were more correlated with age and that this correlation decreases toward the apex [87]. Also, the most marked reduction in volume ratio was observed between the second and the fifth decades of life in lower first and second premolars and between the second and the third decades of life in lower first premolars [87].

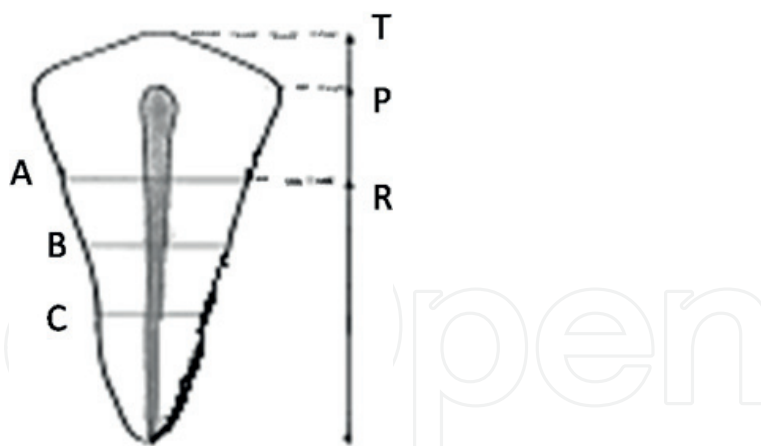


Figure 4. Dental measurements in Kvall's pulp-to-tooth ratio method: T, maximum tooth length; P, maximum pulp length; R, maximum root length; A, root and pulp width at cemento-enamel junction; C, root and pulp width at mid-root level; B, root and pulp width halfway between levels A and C. Level A, the level of the cemento-enamel junction (CEJ). Level B, midpoint between levels A and C. Level C, mid-root level between the CEJ and root apex.

This method is limited in finding the subjects retaining all the six teeth that were measured in this method. Also, there will be a certain amount of distortion when the curved arch of the jaws is projected on to a flat film. It would be better to use the parallel technique. Rotated teeth, teeth with enamel overlap, teeth with restorations, cavities, attrition and periapical pathological process cannot be used in this method, as well.

Using 3D images, the ratio of pulp/tooth volume can be calculated. Vandervoort et al. [34] reported a method using microfocused computed tomography on extracted teeth to compare pulp-to-tooth ratios in the determination of age. Yang et al. [80] used cone beam CT scanning and acquired the 3D images of teeth in living individuals.

In recent years, a software program named Dental Age Estimation[®] has been developed to automate the dental age calculations [88]. It includes the most accurate and often referenced morphological and radiological techniques that are reported in literature. The great advantage of the program is the immediate dental age estimation results. The borders of the pulp and tooth are automatically selected that minimizes the required time to obtain the area of tooth and pulp chamber, in addition, avoiding the calculating errors, the error associated with the observer, when performing the area selection reduces [89]. Also it enables the forensic odontologist to apply different techniques and provides a more reliable result.

Cameriere et al. [90] also developed the statistical regression model performed on digital radiographs by using upper canine pulp/tooth area ratio in adults. Given that, upper canines have certain advantages, such as their longer survival, less wear and the big size of the pulp chamber [91].

3.3. Morphological methods

Once dental development is complete, developmental stages could not be used for age estimation instead the indicators showing that dental structures undergo changes through life are being used. Morphological methods are based on assessment of ex-vivo teeth for age estimation of

adults. The samples of the extracted tooth can be sectioned or unsectioned and observed with the eye or with microscope [1]. However, these methods may not be acceptable due to ethical, religious, cultural or scientific reasons.

In literature, many morphological methods are encountered. Gustafson [92], Dalitz [93], Bang and Ramm [94], Johanson [2], Maples [95] and Solheim [96] developed various morphological methods.

The first technique was published by *Gustafson* in 1950 [92]. Gustafson [92] and Thoma [97] described the morphological changes occurring in the dental tissues by increasing age and noted the following changes:

- a. Attrition of the incisal or occlusal surfaces due to mastication [A]
- b. Periodontitis [P]—the loss of periodontal attachment
- c. Secondary dentin [S]—the amount of coronal secondary dentine formation
- d. Cementum apposition [C] at the root apex
- e. Root resorption [R] amount
- f. Transparency of the root [T]

Each criterion was ranked and allotted 0, 1, 2 and 3 points. The score values of each age change are added according to the following formula:

$$A_n + P_n + S_n + C_n + R_n + T_n = x(\text{overall score}). \quad (4)$$

The exact equation calculated was: $y(\text{age}) = 11.43 + 4.56x$.

This method cannot be used in a living person, only in dead when extraction of a tooth is allowed [96]. It is a subjective method [94] and time-consuming [95]. Periodontitis is often impossible to determine due to the decomposition of a soft tissue [95]. It neglects the possible interrelationships among the criteria [94] and population differences in diet habits with a resultant effect of attrition on tooth.

Dalitz [93] revised Gustafson's method and suggested a 5-point system from 0 to 4, rather than 4-point system to obtain a greater accuracy with the suggested formula. He mentioned that root resorption and secondary cementum formation could be disregarded.

$$E = 8.691 + 5.146A + 5.338P + 1.866S + 8.411 T. \quad (5)$$

In this method, 12 anterior teeth are evaluated; bicuspid and molar teeth are not taken into account.

Johanson [2] evaluated for the same six criteria of Gustafson's method in seven different stages with corresponding scores from 0 to 3. Johanson made a more detailed study of the root transparency and stated that it is more clear when the thickness of the ground section of the tooth was 0.25 mm.

The following formula was recommended:

$$\text{Age} = 11.02 + [5.14 \times A] + [2.3 \times S] + [4.14 \times P] + [3.71 \times C] + [5.57 \times R] + [8.98 \times T]. \quad (6)$$

Where A is attrition, S is secondary dentine formation, P is periodontal attachment loss, C is cement apposition, R is root resorption and T is apical translucent [Q].

Solheim [96] reported another method by using five of the criteria of Gustafson's method [attrition, secondary dentin, periodontitis, cementum apposition and root transparency] in addition to another three new criteria: the surface roughness, color and sex. He recommended not using this method on mandibular canines and second premolars because of the weakest relationship between the parameters and age on these teeth. Two set of formulas were presented: one including sex and color and the other without them, because these factors were not always determinable in deceased individuals. The color may be differentiated due to changes or reactions to the environment and compared with teeth from living individuals; teeth removed from deceased bodies were darker.

Bang and Ramm [94] presented a simple and accurate method for age estimation based on the measurement of only one criterion: the length of the apical translucent zone of only incisors and cuspids (**Figure 5**).

For translucent zones ≤ 9 mm., a formula $\text{Age} = B_0 + (B_1 \times X) + (B_2 \times X^2)$ is used, and if translucent zones > 9 mm., another formula is used: $\text{Age} = B_0 + (B_1 \times X)$ [Q].



Figure 5. Apical translucent zone.

The authors mentioned that transparency of the root dentin advances during the third decade starting at the tip of the root and extending coronally with age. The teeth were sectioned. The length of the root was measured buccally from the cemento-enamel junction to the apex. The transparent root dentin was measured midway between the pulp chamber and the root periphery where the translucent/opaque boundary across the root is fairly horizontal. With this method, good results are obtained by measuring intact roots only. The method is simple, objective and rather fast compared to other methods and can be applied without extensive training or expensive equipment. However, it was difficult to make accurate measurements in molars and bicuspid [94].

Similar to Bang and Ramm [94], Lamendin [98, 99] emphasized that root translucency was the most important one in Gustafson's seven aging criteria. Differently, not only the translucency but also the periodontal tissue level is determined as well. And the measurements are made only on the entire extracted single rooted tooth—the incisors or canines—without any preparation. In their method, the age in years at death is obtained by the following formula:

$$\text{Age} = \left[\left[\frac{\text{Periodontosis}}{\text{root length}} \times 0.18 \right] + \left[\frac{\text{translucency}}{\text{root length}} \times 0.42 \right] \right] \times 100 + 25.53. \quad (7)$$

where *root length* is the distance between the apex of the root and at the cemento-enamel junction; *periodontosis* is the distance between the crown and soft tissue attachment line; *translucency* is evaluated by looking at the tooth exposed to a light box and the length of the transparent zone at the apex of the root is measured. This method is simple and differences between observers are low. However, it is not suitable in young adults as the translucency due to the deposition of hydroxyapatite crystals in the dental tubuli begins after the age of 25. In addition, it gives unreliable age estimation on elder subjects with periodontal disease. The major adversity of this method is the absence of single root tooth that is frequently seen in the elderly or disturbed skeletal remains. Also, it has to be taken into consideration that if there is a long postmortem interval [at least decades] the translucency of the root might be affected by taphonomic factors.

Maples [95] also modified Gustafson's method by using only two criteria of the total six Gustafson recommended: secondary dentine formation and root transparency. With this method, researcher error is expected to be lessened. Teeth with broken crowns, lost cementum and periodontal attachment may still give accurate age estimates. As it does not evaluate the attrition, the bias due to the dietary differences is expected to be decreased [41].

3.4. Biochemical methods

In prenatal stage, up to 6 months, radiological methods cannot be accurate in dental age estimation given that the dentin and enamel images are radiolucent. Therefore, *Stack's method* [100] is suitable to overcome this restriction. It was demonstrated that the dry weight of the mineralized tooth cusps gives an approximate age of the child by using gravimetric methods. Fetal age is linearly related to the square root of the weight of mineralized tissue in the deciduous anterior teeth during the last trimester. At 6 months intrauterine life, the weight is 60 mg; in the newborn child, the teeth weigh 0.5 g, which increases to 1.8 g after 6 months.

Deutsch et al. [101] reported that both the weight and crown height of the anterior teeth were correlated with fetal age as well.

In adults, following completion of the growth period, age estimation by radiological methods becomes not sufficiently accurate [10, 102]. Alternative methods such as biochemical and histological methods are preferred in adults.

The biochemical methods determine alterations in ion levels with age. For instance, the calcium/phosphorus ratio in peritubular dentine increases significantly with age and the rate of racemization of D and L enantiomers of aspartic acid residues in the collagen of dentin is time-dependent [103].

In literature, aspartic acid racemization [104, 105] has been studied for the aim of developing age estimation standards in adults. Although aspartic acid racemization is affected by environmental factors, such that with increasing temperature, racemization increases also, it is demonstrated to be an accurate age estimation method [106]. However, the mentioned method is invasive and expensive and also requires specialized equipment and expertise [104, 105]. In addition, it is not suitable in living individuals [107].

The biochemical methods are based on the racemization of amino acids. The racemization of amino acids is a reversible first-order reaction and is relatively rapid in living tissues in which metabolism is slow. Aspartic acid has been reported to have the highest racemization rate of all amino acids and to be stored during aging. In particular, L-aspartic acids are converted into D-aspartic acids, and so, the levels of D-aspartic acid in human enamel, dentine and cementum increase with age. The D/L ratio has been shown to be highly correlated with age [108]. Helfman and Bada [109] reported studies that focused on the racemization of amino acids and obtained a significant correlation between age and ratio of D/L enantiomers in aspartic acid in enamel and coronal dentin.

The racemization rate of the cementum shows the fastest reaction than enamel and dentine.

On the other hand, dentine showed the highest correlation with actual age [108]. With this method, age determination is not suitable with extensive crown destruction in postmortem examination [110] rather than the extraction of the teeth. Ritz et al. [110] suggested another less invasive way of racemization estimation by dentinal biopsy specimens taken from molars in living subjects. The extension of aspartic acid racemization is higher in deep layers, so biopsy layer had a noteworthy influence. The cavities are then treated with filling materials.

3.5. Histological method

Histological methods require the preparation of the tissues for detailed microscopic examination. This technique is more appropriate for postmortem situations. In prenatal stage, up to 6 months, the dentin and the enamel images are not radiopaque enough to be visualized on radiographs. The histological methods can detect mineralization before being detected in the radiographs. Prenatal dental maturity can be assessed by using dissection and alizarin staining of fetal tooth germs [9]. Initiation of mineralization, as visualized by alizarin staining, takes place in the first permanent molars between 28 and 32 fetal weeks with the mandibular germs being slightly in advance than those of the maxilla [9].

The estimation period of survival of an infant in perinatal period using *neonatal line* as a line of reference can give the exact age of the baby in days [111]. The neonatal lines, present in both enamel and dentin of the permanent teeth, are an optical phenomenon produced due to alteration in the dimension, degree and mineralization of enamel prisms caused due to the sudden change from intrauterine to extrauterine environment [112]. Observing the neonatal lines can be used for assessing the amount of pre- and postnatal enamel formation. In primary enamel, the rate of enamel formation is 2.5–4.5 μ /day [113]. Cross striations are seen across enamel rods representing the daily incremental deposition of enamel [114], and this can be used to find the exact age of the baby in days by counting the cross striations from the neonatal line [111]. Neonatal lines can be used to differentiate between live birth and still birth and are an important tool in forensic cases and for preepidemiological studies. However, the absence of the neonatal line is not always an indicator of still birth [30]. The main limitation of using neonatal line for estimation is that a couple of days of survival is necessary for the neonatal line to develop. Besides, the detection of neonatal line depends on various factors like axis of tooth section, thickness of the section and light source used.

Cementum annulations indeed are a reflection of age, as well. The incremental lines in the tooth cementum can be used as a marker more reliable than any other morphological or histological traits in the human skeleton [4, 51]. A method for preparing human teeth for evaluation involving collection, identification, measuring, sectioning, cleaning, acid etching, staining and mounting is reported. Sections of 100- μ m thick are stained with cresyl fast violet as a stain of choice and are photographed using standard light microscopic techniques, as well as, Nomarski interference microscopy. Acellular cementum bands viewed in transmitted polarized light are characterized by alternating parallel opaque and translucent wider bands. Countability of annulations from photographic enlargements was evaluated. However, it is not always easy to count [115]. Miller et al. [116] reported that determining chronologic age in humans from cementum annulations is not possible.

While using all these methods, the following has to be taken into consideration:

- Gender differences may exist. Tooth wear scores in males are found to be higher than those in females. Males show better development of masticatory muscles than females. Thus, males could exert a stronger bite force than females [21]. Also sexual dimorphism is indicated in the timing and duration of tooth formation, with dental maturity generally being more advanced in females than in males in permanent dentition in reverse of those for the deciduous dentition [17]. If only pulp volume is measured and used as age indicator, there is a significant difference between the accuracy for males and females [117, 118]. To account for this, many dental age estimation methods publish sex-specific formulae or charts. While sex-specific formulae or charts increase accuracy, depending on the condition of the remains, it may be impossible to confidently determine the sex of nonadults without the use of DNA, which may or may not be present [46]. When sex is unknown, the most accurate method is Willems followed by Demirjian and then Haavikko first premolar [76]. Additionally, sex has no statistically significant effect on age estimation, when pulp-to-tooth ratio is calculated [117, 118].
- There are controversial results in the effect of orthodontic treatment on age estimation [119, 120]. Orthodontic treatment may cause external root resorption with subsequent root

shortening and reduction in pulp chamber dimensions, owing to secondary dentine formation. This may cause a potential risk of overestimation while using the methods based on secondary dentine formation and the variation of pulp/tooth dimensions with age. If that were to be the case, it would be necessary to develop specific standards for orthodontically treated participants. Contrarily, it was reported that the changes caused by orthodontic treatment do not have any significant effect on age estimation when Kvaal et al.'s method is applied [121].

- There may be a significant delay in dental age in the subjects with dental agenesis.

4. Conclusion

Chronologic age estimation from teeth for the postmortem evaluation is well established. In this chapter, the different techniques and considered studies were overviewed in conjunction with their advantages and disadvantages. It needs to be taken into consideration that rather than restricting on one age estimation technique, using the other available techniques additionally and performing repetitive measurements may be beneficial for accurate age estimation.

In lights of previous studies, the following can be concluded:

- In prenatal stage, up to 6 months, the dentin and the enamel images are not radiopaque enough to be visualized on radiographs. In that period, the usage of gravimetric method and alizarin staining of fetal tooth germs are recommended in the age assessment.
- In children and adolescents, the radiographic methods that are based on the evaluation of tooth development to assess the extent of tooth mineralization are preferred.
- Third molar calcification stage is one of the few tools that can be used to assess age when development is nearing completion. Clinically, the development of permanent dentition completes with the eruption of the third molar at the age of 17–21 years, after which the radiographic age estimation becomes difficult.
- After the apex closure of third molar, the coronal pulp cavity index or pulp-to-tooth ratio method is used.
- Once dental development is complete, the invasive morphological and histological methods are preferred. Gustafson morphological method is the most accurate around 40–50 years and with increasing inaccuracy in younger and especially in older age groups. Biochemical age determination procedures based on aspartic acid racemization in dentin is more reliable; however, an influence of iatrogenic and carious lesions on the composition of the surrounding dentin and thus on aspartic acid racemization cannot be excluded.
- Dental maturation of children at similar ages in different ethnic groups may differ due to different gene pools, living conditions, climate, socioeconomic status, nutrition and secular changes, which may affect the accuracy of the dental age estimation. To overcome this limitation, population-specific standards based on dental maturity curves can be used.

- An alternate imaging modality is the CT scanning to acquire 3-dimensional images of teeth. It is found to be a more reliable technology for use in dental age estimation.
- The software programs enable the forensic odontologist to apply different techniques, provide a more reliable and immediate result, and avoid calculation errors.

Author details

Fatma Deniz Uzuner*, Emine Kaygısız and Nilüfer Darendeliler

*Address all correspondence to: fduzuner@yahoo.com.tr

Faculty of Dentistry, Department of Orthodontics, Gazi University, Ankara, Turkey

References

- [1] Willems G, Moulin-Romsee C, Solheim T. Non-destructive dental-age calculation methods in adults: Intra- and inter-observer effects. *Forensic Science International*. 2002;**126**:221-226. DOI: 10.1016/S0379-0738(02)00081-6
- [2] Johanson G. Age determination from human teeth. *Odontologisk Revy Supplement*. 1971;**22**:1-126
- [3] Reesu GV, Augustine J, Urs AB. Forensic considerations when dealing with incinerated human dental remains. *Journal of Forensic and Legal Medicine*. 2015;**29**:13-17. DOI: 10.1016/j.jflm.2014.10.006
- [4] Nayar AK, Parhar S, Thind G, Sharma A, Sharma D. Determination of age, sex, and blood group from a single tooth. *Journal of Forensic Dental Sciences*. 2017;**9**:10-14
- [5] Lewis JM, Senn DR. Dental age estimation utilizing third molar development: A review of principles, methods, and population studies used in the United States. *Forensic Science International*. 2010;**20**:79-83. DOI: 10.1016/j.forsciint.2010.04.042
- [6] McKenna CJ, James H, Taylor JA, Townsend GC. Tooth development standards for South Australia. *Australian Dental Journal*. 2002;**47**:223-227. DOI: 10.1111/j.1834-7819.2002.tb00333.x
- [7] Celik S, Zeren C, Çelikel A, Yengil E, Altan A. Applicability of the Demirjian method for dental assessment of southern Turkish children. *Journal of Forensic and Legal Medicine*. 2014;**25**:1-5. DOI: 10.1016/j.jflm.2014.04.006
- [8] Sisman Y, Uysal T, Yagmur F, Ramoglu SI. Third-molar development in relation to chronological age in Turkish children and young adults. *The Angle Orthodontist*. 2007;**77**:1040-1045. DOI: 10.2319/101906-430.1

- [9] Cunningham C, Scheuer L, Black S. *Developmental Juvenile Osteology*. 2nd ed. San Diego: Wiley; 2016. DOI: 10.1046/j.1469-7580.2001.199303692.x
- [10] Kotecha SD. Dental age estimation in children: A review. *Forensic Research Criminology International Journal*. 2016;3:00085. DOI: 10.15406/frcij.2016.03.00085
- [11] Stavrianos C, Mastagas D, Stavrianou I, Karaiskou O. Dental age estimation of adults: A review of methods and principals. *Research Journal of Medical Sciences*. 2008;2:258-268. DOI: rjmsci.2008.258.268
- [12] Proffit W, Fields HW, Sarver DM. *Contemporary Orthodontics*. 5th ed. St. Louis: Mosby; 2012. pp. 66-88
- [13] Masthan KMK. Age estimation by teeth. In: *Textbook of Forensic Odontology*. New Delhi: Jaypee Brothers Medical Publishers [P] Ltd; 2009. pp. 92-97
- [14] Masthan KMK. Age and sex. In: *Textbook of Forensic Odontology*. New Delhi: Jaypee Brothers Medical Publishers [P] Ltd; 2009. pp. 59-65
- [15] Whittakar DK, McDonald DG. *Age Determination from Teeth. A Color Atlas of Forensic Dentistry*. England: Wolfe Medical Publications Ltd; 1989. pp. 58-66
- [16] Reid DJ, Dean MC. Variation in modern human enamel formation times. *Journal of Human Evolution*. 2006;50:329-346
- [17] Mincer HH, Harris EF, Berryman HE. The A.B.F.O. study of third molar development and its use as an estimator of chronological age. *Journal of Forensic Sciences*. 1993;38:379-390. DOI: 10.1520/JFS13418J
- [18] Kvaal S. Collection of post mortem data: DVI protocols and quality assurance. *Forensic Science International*. 2006;159:12-14. DOI: 10.1016/j.forsciint.2006.02.003
- [19] Reppien K, Sejrsen B, Lynnerup N. Evaluation of post-mortem estimated dental age versus real age: A retrospective 21-year survey. *Forensic Science International*. 2006;159(Suppl 1): S84-S88. DOI: 10.1016/j.forsciint.2006.02.021
- [20] Seligrnan DA, Pullinger AG, Solberg WK. The prevalence of dental attrition and its association with factors of age, gender, occlusion, and TMJ symptomatology. *Journal of Dental Research*. 1988;67:1323-1333. DOI: 10.1177/00220345880670101601
- [21] Kim YK, Kho HS, Lee KH. Age estimation by occlusal tooth wear. *Journal of Forensic Sciences*. 2000;45:303-309. DOI: 10.1520/JFS14683J
- [22] Kambe T, Yonernitsu K, Kibayashi K, Tsunenari S. Application of a computer assisted image analyzer to the assessment of area and number of sites of dental attrition and its use for age estimation. *Forensic Science International*. 1991;50:97-109. DOI: 10.1016/0379-0738(91)90138-9
- [23] Hongwei S, Jingtao J. The estimation of tooth age from attrition of the occlusal surface. *Medicine, Science, and the Law*. 1989;29:69-73

- [24] Erdem AP, Yamac E, Erdem MA, Sepet E, Aytepe Z. A new method to estimate dental age. *Acta Odontologica Scandinavica*. 2013;**71**:590-598. DOI: 10.3109/00016357.2012.700062
- [25] Gustafson G. *Forensic Odontology*. 1st ed. London: Elsevier; 1966. pp. 103-139
- [26] Dahl BL, Carlsson GE, Ekfeldt A. Occlusal wear of teeth and restorative materials. A review of classification, etiology, mechanisms of wear, and some aspects of restorative procedures. *Acta Odontologica Scandinavica*. 1993;**51**:299-311. DOI: 10.3109/00016359309040581
- [27] Liversidge HM, Smith BH, Maber M. Bias and accuracy of age estimation using developing teeth in 946 children. *American Journal of Physical Anthropology*. 2010;**143**:545-554. DOI: 10.1002/ajpa.21349
- [28] Mani SA, Naing L, John J, Samsudin AR. Comparison of two methods of dental age estimation in 7-15-year-old Malays. *International Journal of Paediatric Dentistry*. 2008;**18**:380-388. DOI: 10.1111/j.1365-263X.2007.00890.x
- [29] Hegde RJ, Sood PB. Dental maturity as an indicator of chronological age: Radiographic evaluation of dental age in 6-13 years children of Belgaum using Demirjian methods. *Journal of the Indian Society of Pedodontics and Preventive Dentistry*. 2002;**20**:132-138
- [30] Ciapparelli L. The chronology of dental development and age assessment. In: Clark DH, editor. *Practical Forensic Odontology*. 1st ed. Oxford: Butterworth-Heinmann Ltd; 1992. pp. 20-42
- [31] Cameriere R, Ferrante L, Belcastro M, Bonfiaglioli B, Rastelli E, et al. Age estimation by pulp/tooth ratio in canines by periapical X-rays. *Journal of Forensic Sciences*. 2007;**52**:166-170. DOI: 10.1111/j.1556-4029.2007.00530.x
- [32] Cameriere R, Ferrante L, Cingoloni M. Age estimation in children by measurement of open apices in teeth. *International Journal of Legal Medicine*. 2006;**120**:49-52. DOI: 10.1007/s00414-005-0047-9
- [33] Rai B, Anand SC. Age estimation in children from dental radiograph: A regression equation. *The Internet Journal of Biological Anthropology*. 2008;**1**:1-5
- [34] Vandervoort FM, Bergamans L, Cleyenbreugel JV, Bielen DJ, Lambrechts P, Wevers M. Age calculation using X-ray microfocus computed tomographical scanning of teeth: A pilot study. *Journal of Forensic Sciences*. 2004;**49**:787-790. DOI: 10.1520/JFS2004069
- [35] Singaraju S, Sharda P. Age estimation using pulp-tooth area ratio: A digital image analysis. *Journal of Forensic Dental Sciences*. 2009;**1**:37-41. DOI: 10.4103/0974-2948.50888
- [36] Sweet D. Why a dentist for identification. *Forensic odontology*. *Dental Clinics of North America*. 2001;**45**:217-249
- [37] Kraus BS, Jordan RE. *The Human Dentition before Birth*. Philadelphia: Lea and Febiger; 1965. 218 p

- [38] Schour I, Massler M. Development of human dentition. *Journal of the American Dental Association* (1939). 1941;**20**:379-427
- [39] Schour I, Massler M. Studies in tooth development: The growth pattern of human teeth. *Journal of the American Dental Association* (1939). 1940;**27**:1778-1793
- [40] Moorees CFA, Fanning EA, Hunt EE. Age variation of formation stages for ten permanent teeth. *Journal of Dental Research*. 1963;**42**:1490-1502. DOI: 10.1177/00220345630420062701
- [41] Anderson DL, Thompson GW, Popovitch F. Age of attainment of mineralization stages of the permanent dentition. *Journal of Forensic Sciences*. 1976;**21**:191-200. DOI: 10.1520/JFS10353J
- [42] Willems G. A review of the most commonly used dental age estimation techniques. *The Journal of Forensic Odonto-Stomatology*. 2001;**19**:9-17
- [43] AlQahtani SJ, Hector MP, Liversidge HM. Brief communication: The London atlas of human tooth development and eruption. *American Journal of Physical Anthropology*. 2010;**142**:481-490. DOI: 10.1002/ajpa.21258
- [44] Schour I, Massler M. The development of the human dentition. *Journal of the American Dental Association* (1939). 1941;**28**:1153-1160
- [45] Ubelaker DH. *Human Skeletal Remains: Excavation, Analysis, Interpretation*. 1st ed. Chicago, IL: Taraxacum; 1978
- [46] Santana SA, Bethard JD, Moore TL. Accuracy of dental age in nonadults: A comparison of TwoMethods for age estimation using radiographs of developing teeth. *Journal of Forensic Sciences*. 2017;**62**:1320-1325. DOI: 10.1111/1556-4029.13434
- [47] Nolla CM. The development of permanent teeth. *Journal of Dentistry for Children*. 1960;**27**:253-266
- [48] Kırzioğlu Z, Ceyhan D. Accuracy of different dental age estimation methods on Turkish children. *Forensic Science International*. 2012;**216**:61-67. DOI: 10.1016/j.forsciint.2011.08.018
- [49] Demirjian A, Goldstein H, Tanner JM. A new system of dental age assessment. *Human Biology*. 1973;**45**:211-227
- [50] Kaygısız E, Uzuner FD, Yeniay A, Darendeliler N. Secular trend in the maturation of permanent teeth in a sample of Turkish children over the past 30 years. *Forensic Science International*. 2016;**259**:155-160. DOI: 10.1016/j.forsciint.2015.12.031
- [51] Flood SJ, Franklin D, Turlach BA, MGJ. A comparison of Demirjian's four dental development methods for forensic age estimation in South Australian sub-adults. *Journal of Forensic and Legal Medicine*. 2013;**20**:875-883. DOI: 10.1016/j.jflm.2013.07.002
- [52] Demirjian A, Goldstein H. New systems for dental maturity based on seven and four teeth. *Annals of Human Biology*. 1976;**3**:411-421

- [53] Babar MG, Iqbal S, Jan A. Essential guidelines for forensic dentistry. *Pakistan Oral & Dental Journal*. 2008;**27**:79-84
- [54] Ardakani F, Bashardoust N, Sheikhha M. The accuracy of dental panoramic radiography as an indicator of chronological age in Iranian individuals. *The Journal of Forensic Odonto-Stomatology*. 2007;**25**:30-35
- [55] Al-Tuwirqi A, Holcombe T, Seow WK. A study of dental development in a Caucasian population compared with a non-caucasian population. *European Archives of Paediatric Dentistry*. 2011;**12**:26-30
- [56] Cantekin K, Sekerci AE, Peduk K, Delikan E, Ozakar Ilday N, Demirbuga S, Miloglu O. Dental age assessment for different climatic regions. *The American Journal of Forensic Medicine and Pathology*. 2014;**35**:197-200. DOI: 10.1097/PAF.0000000000000096
- [57] Heuze Y, Cardoso HF. Testing the quality of nonadult Bayesian dental age assessment methods to juvenile skeletal remains: The Lisbon collection children and secular trend effects. *American Journal of Physical Anthropology*. 2008;**135**:275-283. DOI: 10.1002/ajpa.20741
- [58] Pelsmaekers B, Loos R, Carels C, Derom C, Vlietinck R. The genetic contribution to dental maturation. *Journal of Dental Research*. 1997;**76**:1337-1340. DOI: 10.1177/00220345970760070201
- [59] Sasso A, Spalj S, Mady Maričić B, Sasso A, Cabov T, Legović M. Secular trend in the development of permanent teeth in a population of Istria and the Littoral region of Croatia. *Journal of Forensic Sciences*. 2013;**58**:673-677. DOI: 10.1111/j.1556-4029.2012.02301.x
- [60] Jayaraman J, Wong HM, King NM, Roberts GJ. The French-Canadian data set of Demirjian for dental age estimation: A systematic review and meta-analysis. *Journal of Forensic and Legal Medicine*. 2013;**20**:373-381. DOI: 10.1016/j.jflm.2013.03.015
- [61] Bagherpour A, Imanimoghaddam M, Bagherpour MR, Einolghozati M. Dental age assessment among Iranian children aged 6–13 years using the Demirjian method. *Forensic Science International*. 2010;**197**:121.e1-121.e4. DOI: 10.1016/j.forsciint.2009.12.051
- [62] Liversidge HM, Speechly T, Hector MP. Dental maturation in British children: Are Demirjian's standards applicable? *International Journal of Paediatric Dentistry*. 1999;**9**(4):263-269
- [63] Nik-Hussein NN, Kee KM, Gan P. Validity of Demirjian and Willems methods for dental age estimation for Malaysian children aged 5–15 years old. *Forensic Science International*. 2011;**204**:208.e1-208.e6. DOI: 10.1016/j.forsciint.2010.08.020
- [64] Cruz-Landeira A, Linares-Argote J, Martínez-Rodríguez M, Rodríguez-Calvo MS, Otero XL, Concheiro L. Dental age estimation in Spanish and Venezuelan children. Comparison of Demirjian and Chaillet's scores. *International Journal of Legal Medicine*. 2010;**124**(2):105-112. DOI: 10.1007/s00414-009-0380-5

- [65] Tunc ES, Koyuturk AE. Dental age assessment using Demirjian's method on northern Turkish children. *Forensic Science International*. 2008;**175**:23-26. DOI: 10.1016/j.forsciint.2007.04.228
- [66] Chaillet N, Willems G, Demirjian A. Dental maturity in Belgian children using Demirjian's method and polynomial functions: new standard curves for forensic and clinical use. *Journal of Forensic Odonto-Stomatology*. 2004;**22**(2):18-27
- [67] Leurs IH, Wattel E, Aartman IH, Eddy E, Prahl-Andersen B. Dental age in Dutch children. *European Journal of Orthodontics*. 2005;**27**:309-314. DOI: 10.1093/ejo/cji010
- [68] Chaillet N, Nyström M, Kataja M, Demirjian A. Dental maturity curves in Finnish children: Demirjian's method revisited and polynomial functions for age estimation. *Journal of Forensic Sciences*. 2004;**49**(6):1324-1331
- [69] Sarkar S, Kailasam S, Mahesh KP. Accuracy of estimation of dental age in comparison with chronological age in Indian population— A comparative analysis of two formulas. *Journal of Forensic and Legal Medicine*. 2013;**20**:230-233. DOI: 10.1016/j.jflm.2012.09.007
- [70] Baghdadi ZD, Pani SC. Accuracy of population-specific Demirjian curves in the estimation of dental age of Saudi children. *International Journal of Paediatric Dentistry*. 2012;**22**:125-131. DOI: 10.1111/j.1365-263X.2011.01179.x
- [71] Krailassiri S, Anuwongnukroh N, Dechkunakorn S. Relationships between dental calcification stages and skeletal maturity indicators in Thai individuals. *The Angle Orthodontist*. 2002;**72**:155-166. DOI: 10.1043/0003-3219(2002)072<0155:RBDCSA>2.0.CO;2
- [72] Sasso A, Legovic M, Mady Maricic B, Pavlic A, Spalj S. Secular trend of earlier onset and decelerated development of third molars: Evidence from Croatia. *Forensic Science International*. 2015;**249**:202-206. DOI: 10.1016/j.forsciint.2015.02.002
- [73] Parner ET, Heidmann JM, Vaeth M, Poulsen S. A longitudinal study of time trends in the eruption of permanent teeth in Danish children. *Archives of Oral Biology*. 2001;**46**:425-431. DOI: 10.1016/S0003-9969(01)00002-4
- [74] Willems G, Van Olmen A, Spiessens B, Carels C. Dental age estimation in Belgian children: Demirjian's technique revisited. *Journal of Forensic Sciences*. 2001;**46**:893-895. DOI: 10.1520/JFS15064J
- [75] Maber M, Liversidge HM, Hector MO. Accuracy of age estimation of radiographic methods using developing teeth. *Forensic Science International*. 2006;**159**:S68-S73. DOI: 10.1016/j.forsciint.2006.02.019
- [76] Phillips VM, van Wyk Kotze TJ. Testing standard methods of dental age estimation by moorrees, fanning and hunt and demirjian, goldstein and tanner on three south african children samples. *Journal of Forensic Odonto-Stomatology*. 2009;**27**(2):20-28
- [77] Haavikko K. Tooth formation age estimated on a few selected teeth— A simple method for clinical use. *Proceedings of the Finnish Dental Society*. 1974;**70**:15-19

- [78] Harris MJ, Nortjé CJ. The mesial root of the third mandibular molar. A possible indicator of age. *The Journal of Forensic Odonto-Stomatology*. 1984;**2**:39-43
- [79] Van Heerden PJ. The Mesial Root of the Third Mandibular Molar as a Possible Indicator of Age. Dissertation for Diploma in Forensic Odontology. London Hospital Medical College; 1985.
- [80] Yang F, Jacobs R, Willems G. Dental age estimation through volume matching of teeth imaged by cone-beam CT. *Forensic Science International*. 2006;**15**(159 Suppl 1):S78-S83. DOI: 10.1016/j.forsciint.2006.02.031
- [81] Vodanović M, Dumančić J, Galić I, Savić Pavičin I, Petrovečki M, Cameriere R, Brkić H. Age estimation in archaeological skeletal remains: Evaluation of four non-destructive age calculation methods. *The Journal of Forensic Odonto-Stomatology*. 2011;**29**:14-21
- [82] Fabbri PF, Viva S, Ferrante L, Lonoce N, Tiberi I, Cameriere R. Radiological tooth/pulp ratio in canines and individual age estimation in a sample of adult neolithic skeletons from Italy. *American Journal of Physical Anthropology*. 2015;**158**:423-430. DOI: 10.1002/ajpa.22796
- [83] De Angelis D, Gibelli D, Fabbri P, Cattaneo C. Dental age estimation helps create a new identity. *The American Journal of Forensic Medicine and Pathology*. 2015;**36**(3):219-220. DOI: 10.1097/PAF.0000000000000178
- [84] Kvaal SI, Solheim T. A non-destructive dental method for age estimation. *Journal of Forensic Odonto-Stomatology*. 1994;**12**:6-11
- [85] Kvaal SI, Kolltveit KM, Thomsen IO, Solheim T. Age estimation of adults from dental radiographs. *Forensic Science International*. 1995;**74**:175-185
- [86] Panchbhai AS. Dental radiographic indicators, a key to age estimation. *Dento Maxillo Facial Radiology*. 2011;**40**:199-212. DOI: 10.1259/dmfr/19478385
- [87] Aboshi H, Takahashi T, Komuro T. Age estimation using microfocus X-ray computed tomography of lower premolars. *Forensic Science International*. 2010;**200**:35-40. DOI: 10.1016/j.forsciint.2010.03.024
- [88] Willems G. Dental age estimation and computers. In: *Proceedings of the European IOFOS Millienium Meeting Leuven*. Forensic Odontology; 23-26 August 2000; Leuven, Belgium. 2000. pp. 161-175
- [89] Marroquina TY, Karkhanisa S, Kvaalb SI, Vasudavanc S, Krugera E, Tennant M. Age estimation in adults by dental imaging assessment systematic review. *Forensic Science International*. 2017;**275**:203-211. DOI: 10.1016/j.forsciint.2017.03.007
- [90] Cameriere R, De Luca S, Egidi N, Bacaloni M, Maponi P, Ferrante L, Cingolani M. Automatic age estimation in adults by analysis of canine pulp/tooth ratio: Preliminary results. *Journal of Forensic Radiology and Imaging*. 2015;**3**:61-66

- [91] De Angelis D, Gaudio D, Guercini N, Cipriani F, Gibelli D, Caputi S, et al. Age estimation from canine volumes. *La Radiologia Medica*. 2015;**120**(8):731-736
- [92] Gustafson G. Age determination on teeth. *Journal of the American Dental Association* (1939). 1950;**41**:45-54
- [93] Dalitz GD. Age determination of adult human remains by teeth examination. *Journal of the Forensic Science Society*. 1962;**3**:11-21. DOI: 10.1111/j.1834-7819.1962.tb02625.x
- [94] Bang G, Ramm E. Determination of age in humans from root dentin transparency. *Acta Odontologica Scandinavica*. 1970;**28**:3-35
- [95] Maples WR. An improved technique using dental histology for estimation of adult age. *Journal of Forensic Sciences*. 1978;**23**:764-770
- [96] Solheim T, Vonen A. Dental age estimation, quality assurance and age estimation of asylum seekers in Norway. *Forensic Science International*. 2006;**159**:56-60. DOI: 10.1016/j.forsciint.2006.02.016
- [97] Thoma KH. *Oral Pathology*. 2nd ed. St. Louis: CV Mosby Co; 1944
- [98] Lamendin H. Age determination with the "simplified" Gustafson method. *Le Chirurgien-Dentiste de France*. 1988;**19**(58):43-47
- [99] French VE, Baccino E, Sinfield L, Colomb S, Baum TP, Martrille L. Technical note: The two step procedure [TSP] for the determination of age at death of adult human remains in forensic cases. *Forensic Science International*. 2014;**244**:247-251. DOI: 10.1016/j.forsciint.2014.09.005
- [100] Stack MV. A gravimetric study of crown growth rate of the human deciduous dentition. *Biologia Neonatorum*. 1964;**6**:197-224
- [101] Deutsch D, Pe'er E, Gedalia I. Changes in size, morphology and weight of human anterior teeth during the fetal period. *Growth*. 1984;**48**:74-85
- [102] Stavriouas C, Mastagas D, Stavriouas I, Karaiskou O. Dental age estimation of adults: A review of methods and principals. *Research Journal of Medical Sciences*. 2008;**2**:258-268. DOI: rjmsci.2008.258.268
- [103] Kosa F, Antal A, Farkas I. Electron probe microanalysis of human teeth for the determination of individual age. *Medicine, Science, and the Law*. 1990;**30**:109-114
- [104] Ohtani S, Ito R, Yamamoto T. Differences in the D/L aspartic acid ratios in dentin among different types of teeth from the same individual and estimated age. *International Journal of Legal Medicine*. 2003;**117**(3):149-152. DOI: 10.1007/s00414-003-0365-8
- [105] Ogino T, Ogino H, Nagy B. Application of aspartic acid racemisation to forensic odontology: Post mortem designation of age at death. *Forensic Science International*. 1985;**29**:259-267

- [106] Ritz-Timme S, Cattaneo C, Collins MJ, Waite ER, Schütz HW, Kaatsch HJ, Borrman HI. Age estimation: The state of the art in relation to the specific demands of forensic practice. *International Journal of Legal Medicine*. 2000;**113**:129-136
- [107] Karkhanis S, Mack P, Franklin D. Age estimation standards for a Western Australian population using the dental age estimation technique developed by Kvaal et al. *Forensic Science International*. 2014;**235**:104.e1-104.e6. DOI: 10.1016/j.forsciint.2013.12.008
- [108] Ohtani S, Hiroshi O, Asaka W. Estimation of age from teeth by amino acid racemisation influence of fixative. *Journal of Forensic Sciences*. 1997;**42**:137-139
- [109] Helfman PM, Bada JL. Aspartic acid racemization in tooth enamel from living humans. *Proceedings of the National Academy of Sciences of the United States of America*. 1975;**72**:2891-2894
- [110] Ritz S, Stock R, Schütz HW, Kaatsch HJ. Age estimation in biopsy specimens of dentin. *International Journal of Legal Medicine*. 1995;**108**:135-139
- [111] Janardhanan M, Umadethan B, Biniraj KR, Kumar RB, Rakesh S. Neonatal line as a linear evidence of live birth: Estimation of postnatal survival of new born from primary tooth germs. *Journal of Forensic Dental Sciences*. 2011;**3**:8-13. DOI: 10.4103/0975-1475.85284
- [112] Stavrianos C, Papadopoulous C, Vasiliadis L, Dagkalis P, Stavrianou I, Petalotis N. Enamel structure and forensic use. *Research Journal of Biological Sciences*. 2010;**5**:650-655. DOI: 10.3923/rjbsci.2010.650.655
- [113] Birch W, Dean C. Rates of enamel formation in human deciduous dentition. *Frontiers of Oral Biology*. 2009;**13**:116-120. DOI: 10.1159/000242402
- [114] Risnes S. Growth tracts in dental enamel. *Journal of Human Evolution*. 1998;**35**:331-350. DOI: 10.1006/jhev.1998.0229
- [115] Naylor JW, Miller WG, Stokes GN, Stott GG. Cemental annulation enhancement: A technique for age determination in man. *American Journal of Physical Anthropology*. 1985;**68**:197-200. DOI: 10.1002/ajpa.1330680206
- [116] Miller CS, Dove SB, Cottone JA. Failure of use of cemental annulations in teeth to determine the age of humans. *Journal of Forensic Science*. 1988;**33**:137-143
- [117] Ge ZP, Ma RH, Li G, Zhang JZ, Ma XC. Age estimation based on pulp chamber volume of first molars from cone-beam computed tomography images. *Forensic Science International*. 2015 Aug;**253**:133.e1-133.e7. DOI: 10.1016/j.forsciint.2015.05.004
- [118] Ge ZP, Yang P, Li G, Zhang JZ, Ma XC. Age estimation based on pulp cavity/chamber volume of 13 types of tooth from cone beam computed tomography images. *International Journal of Legal Medicine*. 2016 Jul;**130**(4):1159-1167. DOI: 10.1007/s00414-016-1384-6

- [119] Baumrind S, Korn EL, Boyd RL. Apical root resorption in orthodontically treated adults. *American Journal of Orthodontics and Dentofacial Orthopedics*. 1996 Sep;**110**(3): 311-320
- [120] Venkatesh S, Ajmera S, Ganeshkar SV. Volumetric pulp changes after orthodontic treatment determined by cone-beam computed tomography. *Journal of Endodontia*. 2014 Nov;**40**(11):1758-1763. DOI: 10.1016/j.joen.2014.07.029
- [121] Marroquin Penaloza TY, Karkhanis S, Kvaal SI, Vasudavan S, Castelblanco E, Kruger E, Tennant M. Orthodontic treatment: Real risk for dental age estimation in adults? *Journal of Forensic Sciences*. 2017;**62**(4):907-910. DOI: 10.1111/1556-4029.13371