

The Helminths

A. Introduction

1. Phylum Platyhelminthes (flatworms) - includes the tapeworms & flukes

a. General Characteristics

- (1) Multicellular animals characterized by a flat, bilaterally symmetric body. It is dorsoventrally flattened and is solid (no body cavity).
- (2) Hermaphroditic, having both male and female reproductive organs in the same individual.
- (3) Overall size varies greatly, some members are as small as 1mm, and others may be 20 meters or longer.
- (4) The classes Cestoda (tapeworms) and Trematoda (flukes) contain species parasitic to humans.

b. The Cestodes


- (1) Adult worms have a flat, ribbon-like white to yellowish body consisting of an anterior attachment organ (scolex) and a body (strobila) consisting of a chain of segments called proglottids.
- (2) Scolex - the head. Characterized by the presence of sucking disks or lateral grooves, and hooks. This is important in speciation, but seldom recovered.
 - (a) Rostellum – present on the scolex of “armed” tapeworms. This is a small button-like structure on top of the scolex from which the hooks protrude. It may be retractable.
- (3) Strobila – the body of the tapeworm
 - (a) Length - varies from a few inches to 20 meters or more.
 - (b) Tegument – the “skin”; important in nutrition of the worm-absorption.
- (4) Dioecious - each proglottid has male & female reproductive organs; can fertilize adjacent segments or a segment can fertilize itself.
- (5) Reproductive organs - male: testes are spread throughout the segment; sperm is collected in the seminal vesical; delivered to female organ via copulatory spicules. Female: ovaries produce eggs; these are stored in the uterus (usually a multi-lobed organ); often not discharged until segment passes, dries and bursts.
 - (a) Proglottids - a few are usually shed every 2-3 days; important in speciation.

(b) Development of proglottids

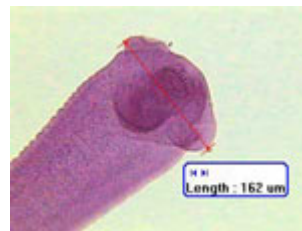
- i) The segments bud from behind the scolex and are immature
- ii) As they are pushed back, they mature, and fill with eggs
- iii) once eggs are fertilized, they become “gravid” proglottids
- iv) release of eggs - sometimes eggs are not released in feces, but often are.
- v) Hexacanth embryos or oncospheres - the larva within the egg shell, it contains six hooklets.

(6) Diagnosis - the scolex or proglottid can be speciated; eggs of some tapeworms can be speciated, but not the *Taenia spp.* Anal swabs (cellophane tape preparations such as used for pinworm diagnosis) are often helpful due to squeezing of segments on the outside of the stool as it passes through the anus.

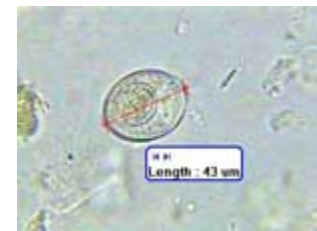b. *Hymenolepis nana* – The Dwarf Tapeworm



Hymenolepis nana adult



Hymenolepis nana scolex



Hymenolepis nana egg

- (1) Frequency - most common of tapeworm infections in humans.
- (2) Requires no intermediate host - can use insects such as fleas or beetles, but these are not necessary.
- (3) Definitive hosts - man, rodents.
- (4) Autoinfection - infected humans ingest eggs from their own feces.
- (5) Morphology - adult is small, 2 to 4 cm in length.
 - (a) scolex - 4 sucking disks & short rostellum with hooks.
 - (b) proglottid – proglottids are broader than long; rarely seen in feces specimens (disintegrate in intestine).
 - (c) eggs - the egg is the most often seen stage in specimens. It measures 45 to 50 microns in diameter and exhibits polar filaments lying between the egg shell

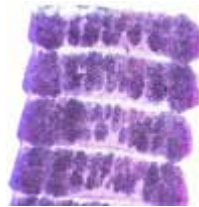
and the hexacanth embryo.

- (6) Mode of Infection - Ingestion of eggs.
- (7) Diagnosis - most often by finding characteristic eggs in a feces specimen.

c. *Hymenolepis diminuta* – The Rat Tapeworm



Hymenolepis diminuta scolex



H. diminuta proglottids



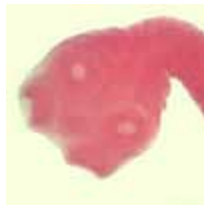H. diminuta egg

- (1) Must be able to differentiate from *H. nana*
- (2) A common parasite of rats, mice and other rodents
- (3) Morphology - considerably larger than *H. nana* (adult as well as egg)
 - (a) size – the adult measures 20 to 60 cm in length.
 - (b) scolex - exhibits no hooks; is larger than that of *H. nana*
 - (c) eggs - measure 60 to 80 microns in diameter and do not exhibit polar filaments.
- (4) Mode of infection - ingestion of intermediate host containing larval stage(s). Grain weevils are the most important intermediate host (other intermediate hosts include earwigs, larval fleas, various beetles). Infection is often due to ingesting bugs in precooked cereals.

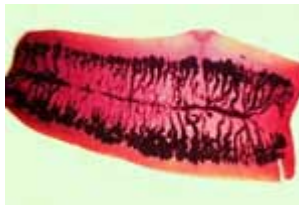e. *Taenia* - two species infect humans

- (1) Life cycle
 - (a) infective eggs (from human feces) are ingested by a suitable intermediate host (cow or pig).
 - (b) oncosphere hatches and penetrates the intestinal mucosa of the intermediate host. It is delivered to various parts of body via the circulatory or lymphatic systems. Most localize & encyst in muscle.
 - (c) infective stage - the encysted larva, called a cysticercus develops within 2 months.

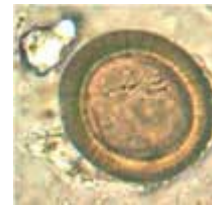- (d) human infections take place when uncooked or undercooked meat is ingested; when other foods (salads, etc.) are contaminated by preparing on same cutting board as meat, or with contaminated utensils.
- (2) scolex - evaginates, attaches to human intestine.
- (3) larvae - cysticercus, a fluid filled bladder with an invaginated scolex.
- (4) Eggs of both species are identical.
- (5) Cysticercosis – A condition resulting when man is the intermediate host. More serious than infections with the adult stage alone. As the oncosphere hatches, it penetrates the intestinal wall and larvae (cysticerci) lodge in body tissues, commonly the lung, brain, eyes, connective tissues, and especially in muscles. This condition only occurs with the pork tapeworm, *Taenia solium*.
- (6) *Taenia saginata* – The Beef Tapeworm



Taenia saginata scolex



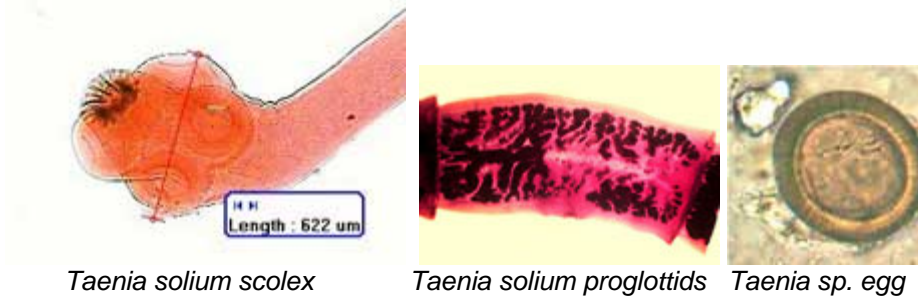
Taenia saginata proglottid



Taenia sp. egg

- (a) Man is the only definitive host
- (b) Infection - ingestion of cysticercus in flesh of cow.
- (c) Size - up to 10 meters in length (although 70' reported).
- (d) Morphology
 - i) gravid proglottids - one inch or slightly longer, the uterus contains 15 to 20 primary branches. The uterine pore is located in a lateral position.
 - ii) scolex - unarmed (no hooks); 4 sucking disks.
 - iii) eggs are identical to *T. solium*, measuring about 40 microns in diameter.
 - iv) life expectancy - 25 years or more.

- (7) *Taenia solium* – The Pork Tapeworm



Taenia solium scolex

Taenia solium proglottids

Taenia sp. egg

- (a) Man is the only definitive host
 - (b) Infection - ingestion of cysticercus in flesh of swine
 - (c) Size - up to 7 meters in length.
 - (d) Morphology
 - i) gravid proglottid has 7-13 primary uterine branches.
 - ii) scolex - armed, with 4 sucking disks.
 - iii) eggs are identical to *T. saginata*, measuring about 40 microns in diameter
 - iv) life expectancy - 25 years or more.
- (8) *T. solium* is more the dangerous infection.
- (a) Autoinfection may occur - cysticercosis, due to ingestion of eggs from feces if infected with adult worm.
 - (b) Racemose form of infection may develop in the brain. A Racemose is a larva which is branching, spreading throughout tissue.

f. *Diphyllobothrium latum* – The Broad Fish Tapeworm Life cycle



Diphyllobothrium latum scolex

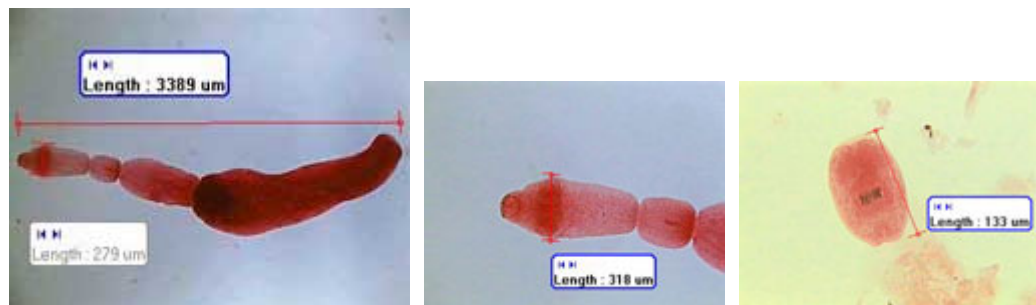
D. latum proglottids

D. latum egg

- (1) Two intermediate hosts are required, copepods (water flea) and fish.

- (2) Several fish-eating mammals serve as definitive hosts, bears, cats, dogs and humans.
- (3) The infective stage for man is the plerocercoid larva ingested in raw or undercooked fish.
- (4) Larvae attach to the mucosa lining of the small intestine.
- (5) Diagnostic stage - eggs or proglottids in feces.
- (6) Morphology - up to 15 meters in length.
- (7) Proglottids are rarely evacuated intact. The uterus looks like a rosette confined to a relatively small area. The uterine pore is centrally located, not lateral as with *Taenia spp.*
- (8) Scolex - almond shaped with a pair of suckorial grooves, one dorsal and one ventral, known as bothria.
- (9) Eggs - measure 30 x 60 microns, and exhibit an operculum (this is the only operculated cestode egg).
- (10) Major pathology
 - (1) Intestinal obstruction
 - (2) Many people exhibit vague diagnostic symptoms such as weight loss and weakness.
 - (3) May cause a macrocytic anemia and eventual nervous system disturbances due to vitamin B12 deficiency. The worm has affinity for vitamin B-12, and can selectively absorb it.

g. *Echinococcus granulosus* – The Hydatid Tapeworm



Echinococcus granulosus adult

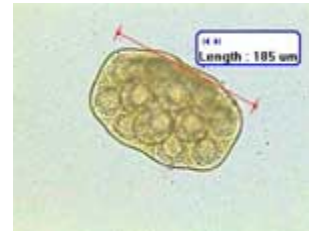
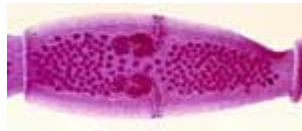
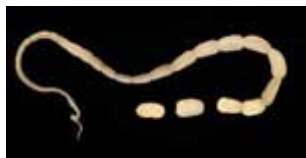E. granulosus scolex

E. granulosus larva

- (1) Dogs or other wild canines are the definitive host
- (2) Life cycle
 - (a) Eggs are shed in the feces of dogs.
 - (b) Humans accidentally ingest eggs from close contact with an infected animal or from canine feces.
 - (c) Hexacanth embryo penetrates the intestinal mucosa and migrates to tissues.
 - (d) The hexacanth develops into the hydatid cyst in the tissue (liver, lung or brain, most often).
 - (e) Viscera containing hydatid cysts are eaten by canines
 - (f) The adult worm develops in canines.
- (3) Morphology

- (a) Adult worm - Small, consists of only 3 segments.
 - (b) Hydatid cyst – a thin walled larva containing many thousands of invaginated scoleces.
- (4) Diagnosis
- (a) Serology
 - (b) Fluid aspiration - look for hydatid “sand”
- (5) Major pathology - hydatid cysts in the brain. Can grow to size of a coconut and contain as much as two liters of fluid. Pressure necrosis of tissue can result from larger cysts. Most commonly found in liver, but can be anywhere, including bone.

h. *Dipylidium caninum* – The Double-Pored Tapeworm



Dipylidium caninum adult *D. caninum* proglottids *D. caninum* egg packet

- (1) Rare in humans.
- (2) Occurs primarily in infants and small children closely associated with pets. Children are at risk of being infected when licked in the mouth after a dog has nipped a flea. Adults killing fleas with fingernails can infect themselves if they bite their nails; cats can spread larvae over fur while grooming following their nipping fleas.
- (3) Life cycle
- (a) Eggs are ingested by fleas (dog or cat fleas are intermediate hosts).
 - (b) The definitive host (dog, cat, human) is infected by ingestion of larvae within fleas. The worm develops in the small intestine of the definitive host.
- (4) Morphology
- (a) Adult – the adult is up to 70 centimeters in length.
 - (b) Scolex - armed rostellum; 4 sucking disks.
 - (c) Gravid proglottids - are the size of rice grains, and exhibit a genital pore on each side.

- (d) Eggs - contained within packets (up to 12 eggs/packet)
- (5) Diagnosis - Usually based on identification of gravid proglottids since free eggs not usually found. Gravid proglottid filled with numerous egg packets containing 8-12 eggs.